



## Acetabular Remodeling after Osteo-Arthroplasty Reconstruction on a Patient with Dislocation of Hip Development

Burnei G<sup>1,2</sup>, Burnei C<sup>3,4</sup>, Dan D<sup>5</sup>, Raducan ID<sup>6,7</sup>

<sup>1</sup>Macta Clinic, Constanta, Romania

<sup>2</sup>Tinos Clinic, Bucharest, Romania

<sup>3</sup>“Carol Davila” University of Medicine and Pharmacy, Bucharest, Romania

<sup>4</sup>Clinical Emergency Hospital, Bucharest, Romania

<sup>5</sup>MedLife Pediatrics Hospitals, Bucharest, Romania

<sup>6</sup>“Vasile Goldis,” Western University of Arad, Arad, Romania

<sup>7</sup>Medical Center ART, Arad, Romania

### Clinical Image

Osteo-Arthroplasty Reconstruction (OAR) of the hip is indicated in Dislocation of Hip Development (DHD) with coxa magna. It is a difficult procedure that can generate serious complication: femoral head necrosis, relapsing of luxation or necrosis of the proximal half of the iliac portion of the acetabulum. DHD is a spectrum of pathology that involves dysplasia of both the acetabulum and the femur [1]. Femoral head acetabular incongruence after iliac osteotomy is a clear sign of articular instability. OAR of the hip is done unique approach, double or triple coxal osteotomy, acetabuloplasty, femoral intertrochanterian osteotomy for centering (derotation and varing or valging) if it is the case with femoral shortening and fixation with pediatric blade-plate with pin guide, pediatric screw-plate or fork blade plate [2].

The procedure repositions and reorientates acetabulum and centers the femoral head. The evaluation and evolution of acetabular remodeling is done by the Head Center - Acetabular Center discrepancy (HC-AC) [3] (Figure 1), ischial tilt (Figure 2), acetabular index, pubo-ischiatic angle (Figure 3) and Hilgenreiner line (Figure 4). The procedure was performed when the patient was 20 months old. The radiological control was performed after 45 days, one, two respectively three years. Patient is in a good state waking normally without any pain, both lower limbs being the same length.

### OPEN ACCESS

#### \*Correspondence:

Burnei Gheorghe, Professor,  
Head of Department Pediatric  
Orthopaedics Surgery, Macta Clinic,  
Constanta, Romania,  
E-mail: mscburnei@yahoo.com

Received Date: 16 Mar 2020

Accepted Date: 24 Mar 2020

Published Date: 27 Mar 2020

#### Citation:

Burnei G, Burnei C, Dan D, Raducan ID.  
Acetabular Remodeling after Osteo-  
Arthroplasty Reconstruction on a Patient  
with Dislocation of Hip Development.  
*Clin Surg.* 2020; 5: 2783.

Copyright © 2020 Burnei G. This is an  
open access article distributed under  
the Creative Commons Attribution  
License, which permits unrestricted  
use, distribution, and reproduction in  
any medium, provided the original work  
is properly cited.

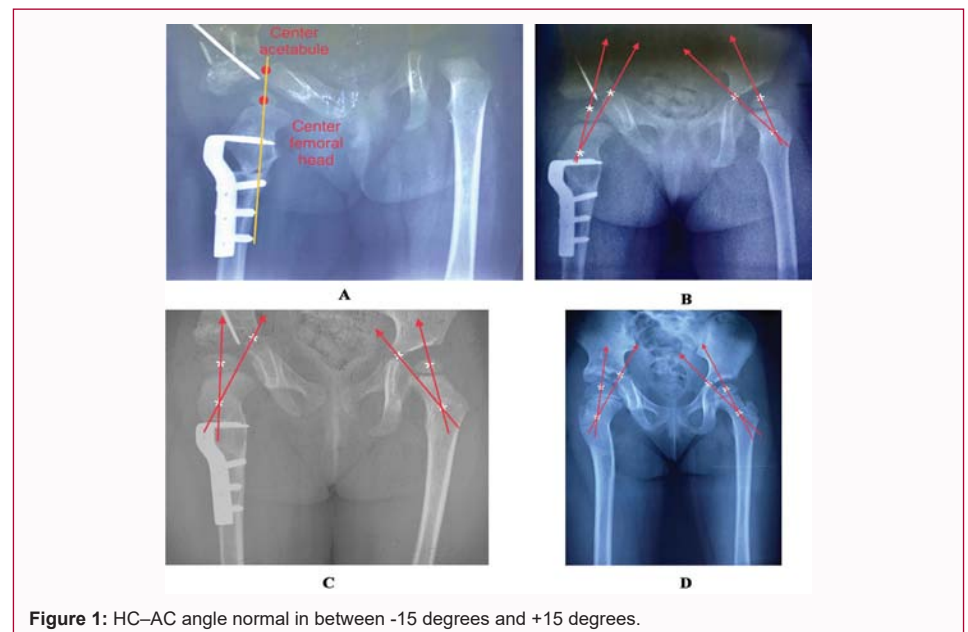
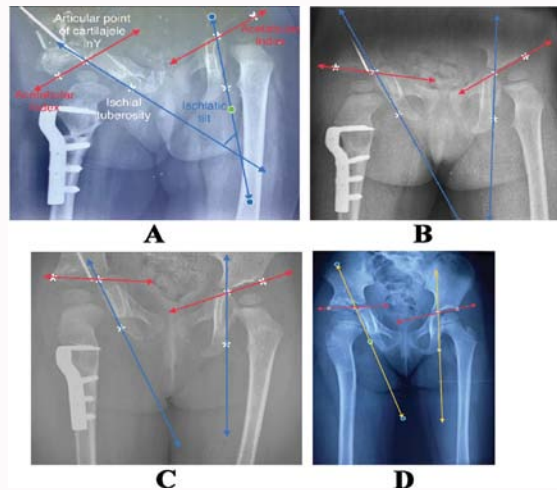
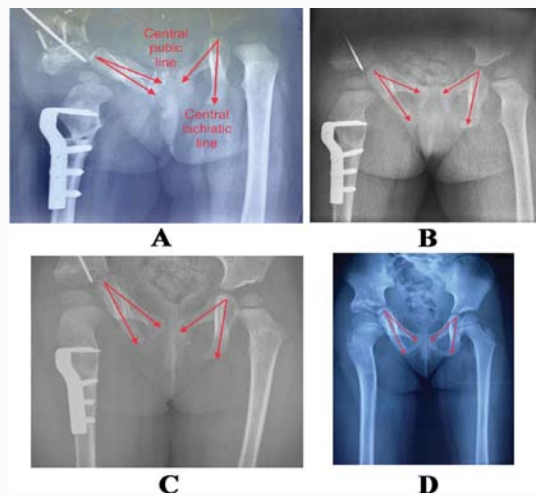


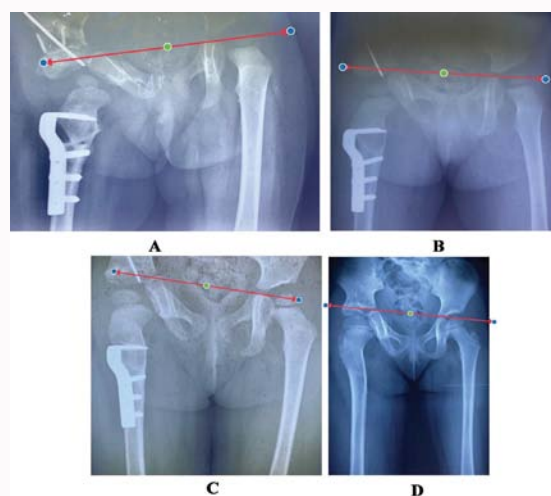
Figure 1: HC-AC angle normal in between -15 degrees and +15 degrees.



**Figure 2:** Ischial tilt is evaluated through ischiadic line in between the articular point of the cartilage and the most lateral point of ischion (ischial tuberosity). The tendency of the line is to become symmetrical with the contralateral one. Acetabular index adjacent to the perpendicular on the ischiadic line is normal thru all the stages.



**Figure 3:** Puboischiadic angle in between the two central lines, pubian and ischiadic increases significantly on the side of the intervention once the obstruction is been removed by detorsioning of the ischiadic bone that was torsioned while reorienting the acetabulum.



**Figure 4:** Hilgenreiner line is normalizing from descending oblique becomes ascending oblique and then evolves towards horizontalisation.

## References

1. Wang Y. Current concepts in developmental dysplasia of the hip and total hip arthroplasty. *Arthroplasty*. 2019;1:2.
2. Burnei G, et al. Arthroplastic reconstruction of the hip in congenital dislocation of the hip—consensus conference in pediatric surgery and orthopedics Iasi: 2001;11-3.
3. Georgescu I, et al. Burnei's technique of femoral neck variation and valgisation by using the intramedullary rod in osteogenesis imperfecta. *J Med Life*. 2014;7(4):493-8.