



## Accidents during Root Canal Treatment

Pedruzzi B<sup>1\*</sup>, Di Carlo R<sup>2</sup> and Girasoli L<sup>2</sup>

<sup>1</sup>Department of ENT, Ospedali Riuniti Padova Sud "Madre Teresa di Calcutta", Via Albere 30, Italy

<sup>2</sup>Department of Neurosciences, Institute of Otorhinolaryngology, Padova University, Padova, Italy

### Clinical Image

A 46-year-old woman presented with an acute restricted painful area in her right throat. The patient were in the Odontostomatology room during a dental root canal treatment, and she inhaled the needle for dental root curettage. No dyspnea, No dysphonia, No dysphagia. An urgent X-ray showed the presence of a metallic needle-shaped foreign body in the larynx ((Figure A), enlarge detail on the right), in a very dangerous site for inhalation into trachea or bronchi and its hazardous risks. A 70°C rigid videolaryngoscopic evaluation revealed the foreign body wedged in her larynx, in detail the rubber dam was skewered between the anterior part of right false fold and laryngeal face of epiglottis. Metallic portion of dental root needle wasn't visible.

The foreign body (Figure B) was successfully removed in endoscopic view under local anesthesia with laryngeal forceps (Jurasz forceps). The patient was discharged with rapid relief of symptoms. Most dental procedures are accomplished while the patient is partially or totally supine; as a result, all restorative patients have the potential to ingest or aspirate a dental item. Aspiration is generally less frequent than ingestion. For the endodontic instruments: the incidence of aspiration was 0.001 per 100,000 root canal treatments and the incidence of ingestion was 0.12 per 100,000 root canal treatments (Figure C). Early location of an inhaled or ingested foreign body facilitates appropriate and timely treatment management and referral. The principle of nonmaleficence dictates the use of preventive practices (i.e. rubber dam, ligatures, throat pack) when possible, both medically and legally.

### OPEN ACCESS

#### \*Correspondence:

Barbara Pedruzzi, Department of ENT, Ospedali Riuniti Padova Sud "Madre Teresa di Calcutta", Italy, Tel: +390429715893;

E-mail: [barbarengy@hotmail.com](mailto:barbarengy@hotmail.com)

Received Date: 09 Mar 2018

Accepted Date: 23 Mar 2018

Published Date: 29 Mar 2018

#### Citation:

Pedruzzi B, Di Carlo R, Girasoli L. Accidents during Root Canal Treatment. Clin Surg. 2018; 3: 1950.

Copyright © 2018 Pedruzzi B. This is an open access article distributed under the Creative Commons Attribution License, which permits unrestricted use, distribution, and reproduction in any medium, provided the original work is properly cited.

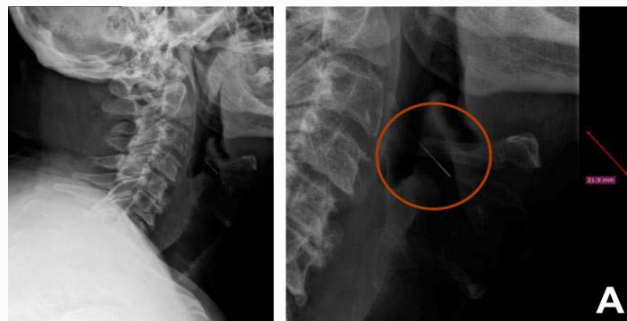

Figure A: On the left, cervical X-ray showing a metallic needle-shaped foreign body in the larynx; on the right enlarge detail of dangerous foreign body in the larynx.



Figure B: Needle for dental root curettage after removing.

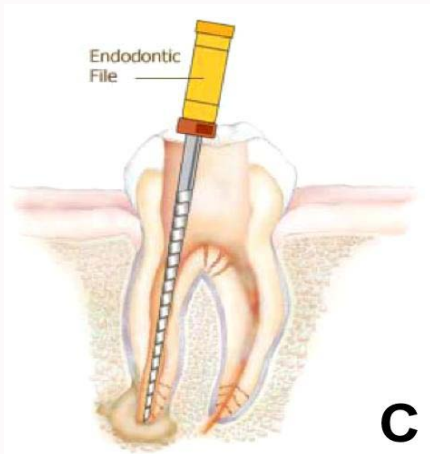


Figure C: Simplify needle for dental root treatment.