



A Study of Comparison of Light Weight 3D Polyester Mesh vs. Light Polypropylene Mesh in Laparoscopic Inguinal Hernia Repair

Soham Shah* and Samir M Shah

Department of General Surgery, Government Medical College, India

Abstract

Background and Objectives: Lightweight Polypropylene mesh gives risk of recurrence, owing to overall decrease in the size of mesh and increased subjective foreign body feeling from contracture and scarring. A lightweight 3D polyester mesh for laparoscopic inguinal hernia repair is associated with minimal risk of postoperative pain, discomfort and recurrence.

Methods: In this study 25 cases of inguinal hernias are treated laparoscopically with TEP with use of lightweight polypropylene mesh and another 25 cases of inguinal hernias are treated with lightweight 3D polyester mesh at Sir Takhtsinhji General Hospital and Government Medical College, Bhavnagar. The following observations were observed for postoperative pain, use of analgesia and postoperative discomfort up between September 2017 to January 2019.

Results: From our study of 50 cases of inguinal hernia using lightweight polypropylene mesh and lightweight 3D polyester mesh, it can be said that lightweight 3D polyester mesh is better than lightweight polypropylene mesh as lightweight 3D polyester mesh is more malleable so deployment time intraoperative is less and there is also less postoperative pain.

Conclusion: The use of 3D lightweight polyester mesh for laparoscopic TEP inguinal hernia repair is a safe and viable option. It offers many advantages in terms of decreased chronic groin pain and decreased postoperative use of analgesia.

Keywords: Lightweight Polypropylene mesh; Lightweight 3D Polyester mesh; Hernia

OPEN ACCESS

*Correspondence:

Soham Shah, Department of General Surgery, Government Medical College, Bhavnagar, Gujarat 364001, India, E-mail: shahsoham0592@gmail.com

Received Date: 13 Mar 2019

Accepted Date: 15 Apr 2019

Published Date: 19 Apr 2019

Citation:

Shah S, Shah SM. A Study of Comparison of Light Weight 3D Polyester Mesh vs. Light Polypropylene Mesh in Laparoscopic Inguinal Hernia Repair. Clin Surg. 2019; 4: 2405.

Copyright © 2019 Soham Shah. This is an open access article distributed under the Creative Commons Attribution License, which permits unrestricted use, distribution, and reproduction in any medium, provided the original work is properly cited.

Introduction

The concept of using a mesh to repair hernias was introduced over 50 years ago. Mesh repair is now standard in most countries and widely accepted and superior to primary suture repair. As a result, there has been a rapid growth in the variety of meshes available and choosing the appropriate one can be difficult.

Now days we have three big groups of material concerning non-resorbable meshes: polypropylene, polyester and polytetrafluoroethylene. Still in literature there is no consensus which material has the best biocompatibility in humans. Polyester is a hydrophilic material as opposed to hydrophobic material such as polypropylene or polytetrafluoroethylene and thus encourages early biologic fixation and collagen in growth into surrounding tissue.

Lightweight polypropylene mesh

These are made of prolene fibres arranged in a network with pores of differing sizes. PPM is classified on the basis of density of the material and its surface area as heavyweight (90 gm/sq meter to 100 gm/sq meter); middle weight (45 gm/sq meter to 50 gm/sq meter) and light weight (less than 45 gm/sq meter).

Three-dimensional polyester mesh

A flat sheet of mesh may not be the ideal configuration for a laparoscopic repair so a 3D mesh was then created with key benefits of being is more malleable so deployment time intraoperative is less. In postoperative period the patient complaint less of discomfort and pain [1-3] (Figures 1 and 2).

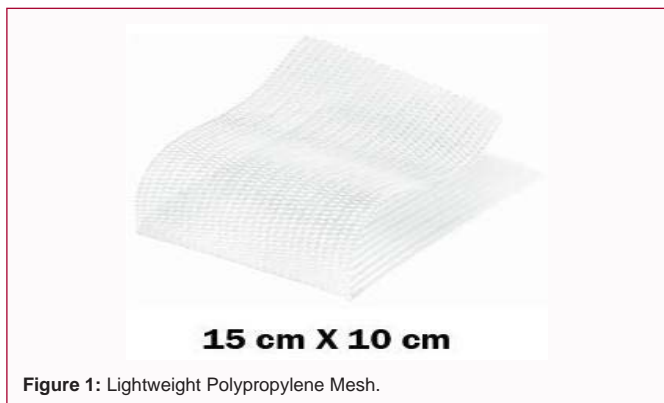

Figure 1: Lightweight Polypropylene Mesh.



Figure 2: Lightweight 3d Polyester Mesh.

Material and Method

In this study total of 50 cases of anterior abdominal wall hernias are selected. Among them Group A consists of 25 cases of laparoscopically TEP hernioplasty done using polypropylene mesh and Group B consists of 25 cases of laparoscopically TEP hernioplasty done using polyester mesh. They are studied and followed up between September 2017 to January 2019 at Sir T. Hospital and Government Medical College, Bhavnagar [4-10].

Inclusion criteria

- Patients of both sex with age group of 18-65 years with inguinal hernia.

Exclusion criteria

- Infant and children (<18 years of age)
- Patient with large irreducible hernia
- Strangulated hernia
- Patient unfit for general anesthesia due to any reason.

Procedure in short

- We have selected total of 50 cases of hernia in different age groups with/without co-morbidities and explained about the study.
- In 25 cases, we have used lightweight polypropylene mesh for hernioplasty and in another group of 25 cases we have used lightweight polyester mesh 3D for laparoscopic approach of inguinal hernia repair.

Evaluation parameters

Patient will be followed up to a minimum of 3 months after the surgery. Follow up would be done in the surgery outpatient department at 1 month, 3 month from the date of surgery.

Those who will not report in OPD will be contacted on phone. Following parameters will be evaluated:

Table 1: Observations & Results.

Group A	25 cases	Hernioplasty done using lightweight polypropylene mesh
Group B	25 cases	Hernioplasty done using lightweight 3D polyester mesh

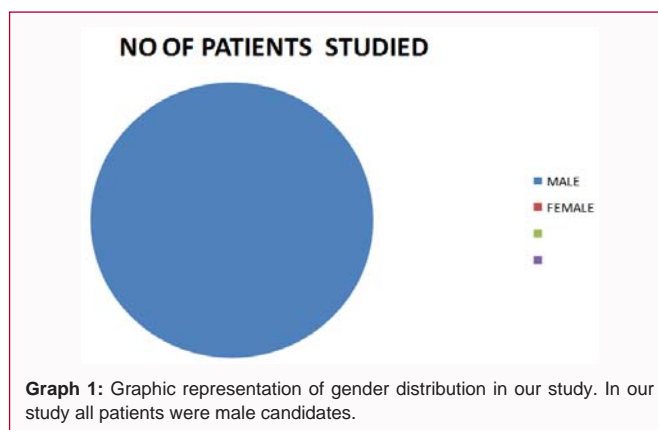
Table 2: Demographic data.

Age Group (in years)	No. of patients
21-30	01(2%)
31-40	15(30%)
41-50	26(52%)
51-60	02(4%)
61-70	04(8%)
>70	02(4%)

In our study maximum patients are of age group of 41-50 years (26 people-52%).

Table 3: Gender distribution of patients studied.

Gender	No of patients studied
MALE	50(100%)
FEMALE	00(0%)



- A. postoperative pain
- B. postoperative discomfort
- C. Use of analgesia [11-19].

Observations and Results

In our study, 50 cases are divided in two groups.

The data presented here consists of Group A with 25 cases of hernia that are treated with lightweight polypropylene mesh and Group B with 25 cases of hernia that are treated with lightweight 3D polyester mesh using laparoscopic approach (Tables 1-4, Graph 1 and 2).

Demographic data

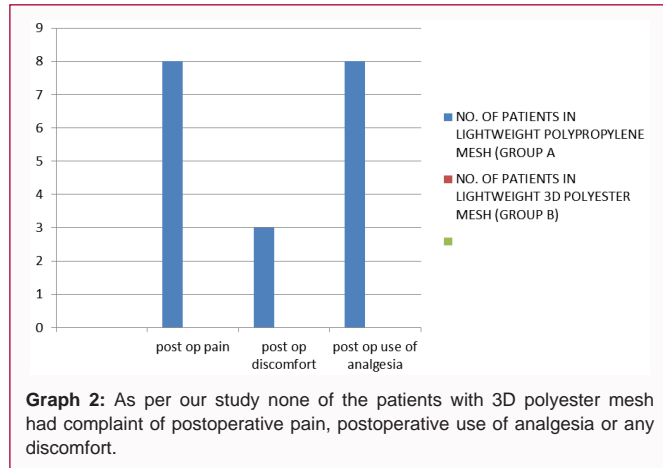
As per our study none of the patients with 3D polyester mesh had complaint of postoperative pain, postoperative use of analgesia or any discomfort.

While 32% of the patients with lightweight polypropylene mesh had complain of postoperative pain while 12% of them had postoperative discomfort while 32% patients required postoperative use of analgesia at 1 month of follow up.

Similar results were obtained in a comparative study of three-dimensional mesh (3D mesh) and polypropylene mesh in laparoscopic inguinal hernia repairs in adults” by Tajamul Rashid, Farooq Ahmad

Table 4: Comparison of post-operative parameters between polypropylene mesh and polyester mesh on day 30.

Parameters	No. of patients in lightweight polypropylene mesh (Group A)	No. of patients in lightweight 3D polyester mesh (Group B)	P value
Post Op Pain	08	00	0.0232
Post Op Discomfort	03	00	0.0009
Post Op Use of Analgesia	08	00	0.0232



Reshi, Iqbal Saleem Mir, Suhail Nazir Bhat, Irfan Nazir, Sheikh Viqar, Mudasir Farooq Hajini, Aftab Akbar.

Comparison of Post-Operative Parameters between Polypropylene Mesh and Polyester Mesh On Day 90

There was no complain in patients of any of the group i.e. lightweight polypropylene group and lightweight 3D polyester group.

Conclusion

The use of lightweight three-dimensional mesh polyester (3D mesh) for laparoscopic inguinal hernia repair is a safe and viable option. It offers many advantages in terms of shorter hospital stays, decreased chronic groin pain and decreased postoperative morbidity as it is more malleable compared to lightweight polypropylene mesh.

References

1. Wantz GE. Abdominal Wall Hernias. Schwartz SI, ed. Principles of Surgery: 7th Ed. 1999;1585-611.
2. McIntosh A, Hutchinson A, Roberts A, Withers H. Evidence-based management of groin hernia in primary care- a systematic review. *Fam Pract.* 2000;17(5):442-7.
3. Bax T, Sheppard BC, Crass RA. Surgical options in the management of groin hernias. *American Family Physician.* 1999;59(1):143-56.
4. Gilbert AI, Young J, Graham MF, Divilio LT, Patel B. Combined anterior and posterior inguinal hernia repair: intermediate recurrence rates with three groups of surgeons. *Hernia.* 2004;8(3):203-7.

5. Ger R. The Management of certain abdominal hernias by intra-abdominal closure of the neck. *Ann R Coll Surg Engl.* 1982;64(5):342-4.
6. Kingsnorth A, Wright D, Porter C, Robertson G. Prolene Hernia System compared with Lichtenstein patch: a randomised double-blind study of short-term and medium-term outcomes in primary inguinal hernia repair. *Hernia.* 2002;6(3):113-9.
7. Ferzli G, Sayad P, Huie F, Hallak A, Usal H. Endoscopic extraperitoneal herniorrhaphy. A 5-year experience. *Surg Endosc.* 1998;12(11):1311-3.
8. Usher F. Hernia repair with Marlex mesh. An analysis of 541 cases. *Arch Surg.* 1962;84:325-8.
9. Doctor HG. Evolution and Evaluation of Newer Prosthetic Material: Recent Advances in Surgery. 2009;11:207-24.
10. Welty G, Klinge U, Klosterhalfen B, Kasperk R, Schumpelick V. Functional impairment and complaints following incisional hernia repair with different polypropylene meshes. *Hernia.* 2001;5(3):142-7.
11. Pajotin P. Laparoscopic groin hernia repair using a curved prosthesis without fixation. *Le journal de Coelio-Chirurgie.* 1998;28:64-8.
12. Koch CA, Greenlee SM, Larson DR, Harrington JR, Farley DR. Randomized prospective study of totally extraperitoneal inguinal hernia repair: fixation versus no fixation of mesh. *JSLS.* 2006;10(4):457-60.
13. Vrijland WW, van Den Tol MP, Luijendijk RW, Hop WC, Busschbach JJ, De Lange DC, et al. Randomized clinical trial of non-mesh versus mesh repair of primary inguinal hernia. *Br J Surg.* 2002;89(3):293-7.
14. Eriksen JR, Gögenur I, Rosenberg J. Choice of mesh for laparoscopic ventral hernia repair. *Hernia.* 2007;11(6):481-92.
15. Chalkoo M, Mir MA, Makhdoomi H. Laparoscopic Transabdominal Preperitoneal Mesh Hernioplasty: A Medical College Experience. *Surgical Science.* 2016;7(2):107-13.
16. Mir IS, Nafae AA, Malyar AA, Nafae M, Watali Y, Farooq M, et al. An Experience of Short-Term Results of Laparoscopic Inguinal Hernioplasty Using 3D Mesh in a Developing Country. *Int J Clin Med.* 2015;6(1):64-9.
17. Agarwal BB, Agarwal KA, Mahajan KC. Prospective double-blind randomized controlled study comparing heavy and lightweight polypropylene mesh in totally extraperitoneal repair of inguinal hernia: early results. *Surg endosc.* 2009;23(2):242-7.
18. Khajanchee YS, Urbach DR, Swanstrom LL, Hansen PD. Outcomes of laparoscopic herniorrhaphy without fixation of mesh to the abdominal wall. *Surg endosc.* 2001;15(10):1102-7.
19. Carter J, Duh QY. Laparoscopic repair of inguinal hernias. *World J Surg.* 2011;35(7):1519-25.