



## A Strange Case of Toothbrush Ingestion

Fulvio Tagliabue<sup>1\*</sup>, Giulia Bonfanti<sup>1</sup>, Morena Burati<sup>2</sup>, Giovanni Pesenti<sup>1</sup>, Alberto Scaini<sup>1</sup> and Mauro Pietro Zago<sup>1</sup>

<sup>1</sup>Department of Emergency and Robotic Surgery, ASST- Lecco "Alessandro Manzoni Hospital", Italy

<sup>2</sup>Department of Emergency, ASST- Lecco "Alessandro Manzoni Hospital", Italy

### Clinical Image

A 45-year-old man was admitted to our surgical department from casualty, complaining of abdominal pain for 3 months. The patient, apparently in good physical and mental health, reports that he ingested about four months before a whole toothbrush without knowing why. Immediately the patient underwent to an X-ray abdomen that showed the presence of the brushes of the toothbrush in the right hypochondrium (Figure 1A). A gastroscopy performed with the intention of seeing the right position of the toothbrush and attempting its removal, showed that the tip of the brush was at the level of the first duodenal portion after the pylorus and that its endoscopic removal was not possible (Figure 1B). For this reason we decided to perform a CT scan with the aim of identifying the right position of the toothbrush for a good surgical approach (Figure 1C). The patient went to operating theatre and we performed an exploratory laparoscopy with toothbrush removal with a gastrostomy (Figure 2). The postoperative course was regular and the patient was discharged on the third postoperative day. Ingested foreign bodies progress through the digestive tract spontaneously in 80% to 90% of cases; however, 10% to 20% of patients require endoscopy and less 1% undergo surgery. The patients interested usually are those with alcohol abuse and drug misuse, emotional disturbance, psychiatric disorders and in persons who wear artificial dentures [1,2]. Usually the pylorus, duodenal C-loop and ileocecal valve are the three physiological narrowing's in the gastrointestinal tract, and most of the swallowed foreign bodies pass through it without complications [3]. However, objects longer than 10 cm like the toothbrush cannot pass the duodenal C-loop due to its fixed position in the retroperitoneum, and for this reason it must be removed as soon as possible to avoid pressure necrosis and gastric or duodenal perforation [4,5]. The first choice, when possible, is the endoscopic removal of these objects but it is necessary an extreme caution and great experience of the endoscopist [6]. If it is impossible to remove it endoscopically, surgery must be done, and it is preferable that the surgery is performed with a minimally invasive technique.

### OPEN ACCESS

#### \*Correspondence:

Fulvio Tagliabue, Department of Emergency and Robotic Surgery, ASST- Lecco "Alessandro Manzoni Hospital", Via dell'Eremo 9/11, 23900 Lecco, Italy,  
E-mail: f.tagliabue@asst-lecco.it

Received Date: 12 Apr 2021

Accepted Date: 26 Apr 2021

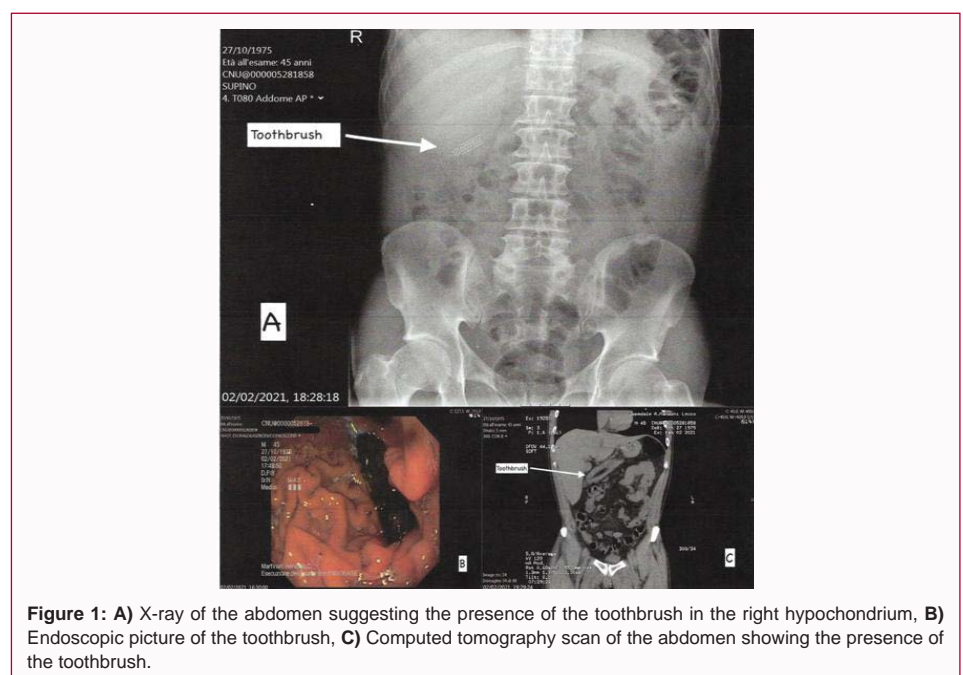
Published Date: 29 Apr 2021

#### Citation:

Tagliabue F, Bonfanti G, Burati M, Pesenti G, Scaini A, Zago MP. A Strange Case of Toothbrush Ingestion. Clin Surg. 2021; 6: 3150.

Copyright © 2021 Fulvio Tagliabue.

This is an open access article distributed under the Creative Commons Attribution License, which permits unrestricted use, distribution, and reproduction in any medium, provided the original work is properly cited.



**Figure 1:** A) X-ray of the abdomen suggesting the presence of the toothbrush in the right hypochondrium, B) Endoscopic picture of the toothbrush, C) Computed tomography scan of the abdomen showing the presence of the toothbrush.



**Figure 2:** Toothbrush immediately after its removal.

## References

1. Magalhaes-Costa P, Carvalho L, Rodrigues JP. Endoscopic management of foreign bodies in the upper gastrointestinal tract: An evidence-based review article. *GE Port J Gastroenterol.* 2015;23(3):142-52.
2. Zarei M, Shariati B, Bidaki R. Intestinal perforation due to foreign body ingestion in a schizophrenic patient. *Int J High Risk Behav Addict.* 2016;5(3):e30127.
3. Smith MT, Wong RK. Foreign bodies. *Gastrointestinal Endosc Clin N Am.* 2007;15:361-82.
4. Li ZS, Sun ZX, Zou DW. Endoscopic management of foreign bodies in the upper -GI-tract: Experience with 1,088 cases in China. *Gastrointest Endosc.* 2006;64:485-92.
5. Niknam R, Mahmoudi L, Nasserri-Moghaddam S. An incidentally swallowed toothbrush. *Arch Iran Med.* 2012;15:177-8.
6. Nagashima R, Saitoh H, Fukase Y. Endoscopic removal of a toothbrush using biopsy forceps and tread. *Endoscopy.* 1998;30:S90-91.