



A Simple Technique of Intra-Operative Autograft Bone Harvesting for Repair of Massive Acetabular Bone Defects

Imran Haruna Abdulkareem* and Jonathon Kitson

Department of Trauma and Orthopedics, East and North Hertfordshire NHS Trust, UK

Abstract

Several techniques of autograft bone harvesting have been described in the Orthopaedic literature. These include iliac crest bone graft which is considered to be the gold standard and the traditional technique carried out by many Orthopaedic surgeons. This is because autograft is osteoinductive, osteoconductive as well as osteogenic, and can be harvested from different sites in different forms and sizes. Other sources include fibula graft (vascularised and non-vascularised), rib, skull, femoral shafts, vascularised medial femoral condyle, calcaneus, osteophytes, proximal or distal tibia, distal radius, greater trochanter, and more recently reamed autogenous bone graft using the Reamer Irrigator Aspiration technique as well as the Poly Methyl Methacrylate membrane-induced technique and tissue engineered biomaterials.

Introduction

Several techniques of autograft bone harvesting have been described in the Orthopaedic literature. These include iliac crest bone graft which is considered to be the gold standard and the traditional technique carried out by many Orthopaedic surgeons [1]. This is because autograft is osteoinductive, osteoconductive as well as osteogenic, and can be harvested from different sites in different forms and sizes [2]. Other sources include fibula graft (vascularized and non-vascularized), rib [3], skull, femoral shafts, vascularized medial femoral condyle [4], calcaneus [5], osteophytes [6], proximal or distal tibia, distal radius, greater trochanter [7], and more recently reamed autogenous bone graft using the Reamer Irrigator Aspiration (RIA) technique [8] as well as the Poly Methyl Methacrylate (PMMA) membrane-induced technique [2] and tissue engineered biomaterials. These techniques are commonly used individually or in combination in non-union, infections, deformity corrections, limb lengthening, spinal surgery [9] and trauma surgery [10].

In addition to that, several other bone graft substitutes such as allografts and artificial bone substitutes like calcium phosphate, calcium sulphate, hydroxyapatite, and bio-active glass, have also been used to repair or support bone defects during surgery [11]. The indications for bone grafts are many and include repair of massive diaphyseal, metaphyseal, peri-articular or intra-articular bone defects as a result of tumor resection, trauma, infection, and osteoporosis or to provide structural support in massive acetabular or femoral defects intra-operatively for example [12]. Other indications include non-union surgery, Anterior Cervical Decompression and Fusion (ACDF) [13] as well as lumbar spinal fusion [1]. Other substitutes are commonly mixed with antibiotics and used in the treatment of bone infections such as Cerament bone cement commonly used in the treatment of osteomyelitis.

However, using some of the traditional techniques of autograft or allograft bone harvesting is fraught with a lot of complications, challenges or problems. With regards to autografts, these problems include donor site morbidity and the issue of quantity, which can sometimes be limited [13]. Problems with allograft include consent issues, risk of infections or disease spread especially with viruses, immunogenic rejection, cost and compatibility issues [14], even though a large amount of graft can be provided. Xenografts are rarely used in humans, because they have an even higher risk of infections and zoonotic disease transmission, more severe immunogenic reaction, as well as tissue rejection. In this regard, artificial bone substitutes [11] have the advantage of providing a large amount of graft required, without the risk of infection, immunogenic rejection or donor site morbidity [14]. However, excessive cost can be an issue with some of these newer bone graft substitutes. In addition to that, some of these agents take a long time to integrate or breakdown in the tissues.

In view of this, we have come up with a new simple intra-operative technique of harvesting

OPEN ACCESS

*Correspondence:

Imran Haruna Abdulkareem,
Department of Trauma and
Orthopedics, East and North
Hertfordshire NHS Trust, Lister
Hospital Stevenage, Corey's Mill Lane,
Stevenage Hertfordshire SG1 4AB, UK,
E-mail: imranharuna@yahoo.com

Received Date: 29 Jul 2019

Accepted Date: 30 Aug 2019

Published Date: 04 Sep 2019

Citation:

Abdulkareem IH, Kitson J. A Simple
Technique of Intra-Operative Autograft
Bone Harvesting for Repair of Massive
Acetabular Bone Defects. *Clin Surg*.
2019; 4: 2565.

Copyright © 2019 Imran Haruna
Abdulkareem. This is an open access
article distributed under the Creative
Commons Attribution License, which
permits unrestricted use, distribution,
and reproduction in any medium,
provided the original work is properly
cited.

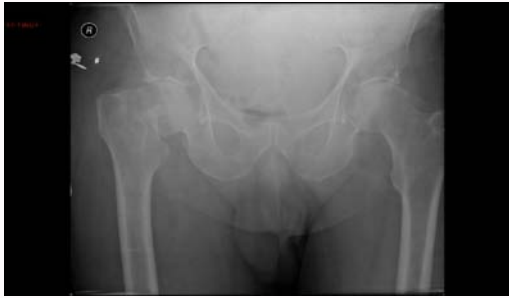

Figure 1a: Pelvic radiograph showing displaced (Garden IV) right intra-capsular NOF fracture.

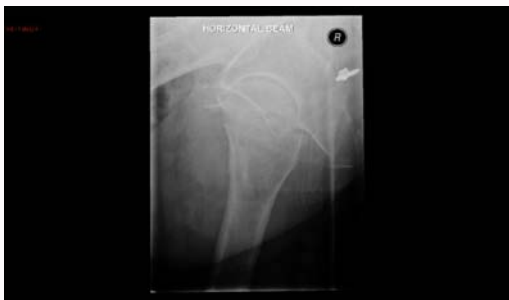

Figure 1b: Lateral radiograph showing displaced right intra-capsular NOF fracture.

autograft bone from the excised femoral head during Total Hip Replacement (THR), which can be used to fill or support massive acetabular and other peri-articular defects intra-operatively. This technique is simple, cheap, and easily reproducible and has not been previously published in the Orthopaedic literature. In addition to that, the technique does not require any additional equipment, no separate consent is required and it doesn't prolong the surgical procedure.

We have done a literature search and couldn't find a single publication or article where this technique has been used or described. We are however aware that many Orthopaedic surgeons traditionally use the excised femoral head to harvest autograft during hip arthroplasty procedures using many different techniques, but most of these harvesting techniques have not been formally described or published in the literature previously. Therefore, we are hoping to add new knowledge of this simple and cost effective technique to the orthopaedic literature, which can be replicated by any Orthopaedic surgeon undertaking hip arthroplasty and other procedures requiring bone graft.

Case Presentation

The patient was an eighty five year old man, who presented to our emergency department following a mechanical fall. He was complaining of right hip pain and inability to weight bear since the fall and his X-rays revealed a displaced (Garden IV) intra-capsular fracture of the right femoral neck (Figure 1a,1b).

He has a past medical history of Benign Prostatic Hypertrophy (BPH) and hypothyroidism, but was otherwise fit and well. He lived at home and was the full time career of his wife. In addition to that, he was also normally fully mobile, independent, and walked for many miles without any aids. He also had a mini-mental score of 10/10. Therefore, in line with National Institute of Clinical Excellence (NICE) guidelines, he was counseled and consented for

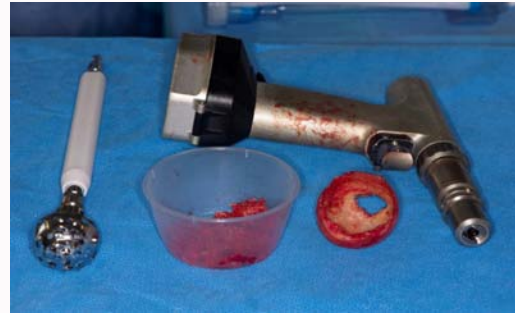

Figure 2a: Acetabular reamer used to harvest autograft bone from the femoral head.

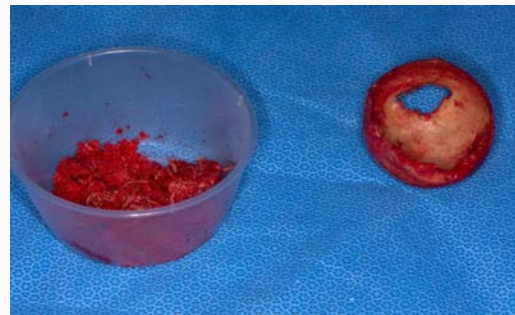


Figure 2b: Harvested autograft bone from the femoral head.

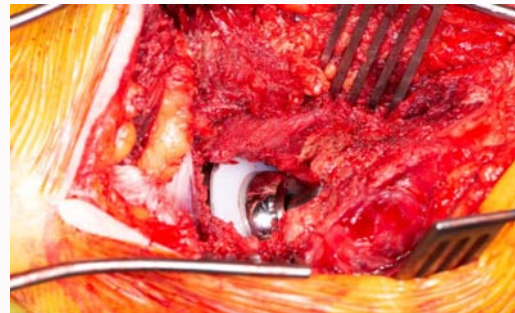


Figure 3: Intra-operative picture of the completed Total Hip Replacement (THR).

a right Total Hip Replacement (THR), which was performed 24 h following admission.

Intra-operative technique

The patient was properly checked and put under spinal anaesthesia. A WHO check was carried out in theatre, and the patient was adequately positioned, prepared and draped. A modified Harding (anterolateral) approach to the right hip was carried out (as this is the favored approach of the senior author JK), femoral osteotomy was done, and the head was removed from the acetabulum with a corkscrew and kept separately on a table, wrapped with a piece of wet gauze. The right acetabulum was adequately exposed with the aid of self-retaining retractors. Sequential reaming of the acetabulum was commenced using a small (size 44 mm) acetabular reamer on the floor of the acetabulum. This led to massive bone loss in the floor of the acetabulum. As a result of this, the reaming procedure was stopped, and the plan was changed to carry out an uncemented THR rather than the original plan of a cemented THR.

In view of this, the femoral head was used to harvest cancellous

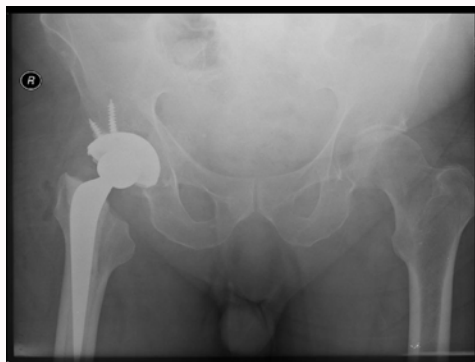


Figure 4a: Pelvic radiograph showing a hybrid Right Total Hip Replacement (THR).

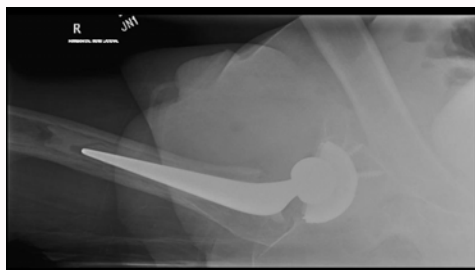


Figure 4b: A lateral radiograph of the Right Total Hip Replacement (THR).

autograft by using the small (size 44 mm) reamer to core out the cancellous bone and leaving a shell of articular cartilage outside, while the femoral head was held on a table with a pair of Kocher's forceps (Figure 2a). The femoral head can also be held with a patella clamp to give better control. This technique can also be used to harvest bone from the femoral head in situ, before it is taken out from the acetabulum. The procedure provided a large amount of cancellous autograft bone, which was used to fill the acetabular defect, without the need for additional graft.

The harvested bone graft (Figure 2b) was then used to fill the acetabular defect after completing gentle reaming of the periphery of the acetabulum. A size 54 mm uncemented acetabular cup was chosen after trial, and then implanted on top of the bone graft which had been impacted into the acetabular defect, this was support with two screws for additional stability, and a ceramic liner was then put into the acetabular shell. The rest of the procedure (THR) was completed uneventfully (Figure 3).

Post-operatively, the patient did well, and was fully mobilized with the aid of the physiotherapists. His check X-rays were satisfactory (Figure 4a,4b). He was discharged home after five days of admission, and was followed up in the out-patients' department after six weeks, where he was found to be fully mobile and completely pain free.

Discussion

Over two million bone grafting procedures were performed annually worldwide in 2016, which is second only to blood transfusion [15]. There are many indications for bone graft in Trauma and Orthopaedic Surgery. Some of the common indications include massive bone loss following trauma [2], tumor resection or infection. Other indications include severe osteoporosis, non-union of fractures, spinal deformity correction, bone lengthening, ACDF,

spinal decompression and fusion [9] as well as severe rheumatoid arthritis [5]. The type of autograft used depends on the size and nature of the defect and the aim of treatment. Generally, non-vascularized grafts are recommended for small defects less than 5 cm, and vascularized grafts are better for larger defects [2].

Treatment of critical bone defects continues to pose a lot of challenges to orthopedic surgeons [16]. However, the iliac crest bone remains the most common site of autograft bone harvesting [5]. But due to the drawbacks and morbidities of using autografts, such as pain, hematoma, neurovascular injury, infection, incisional hernia, fracture and the limited quantity of bone obtained [7], other alternatives have been widely used to correct bone defects. These include allografts, xenografts (rarely used), as well as artificial bone substitutes which include calcium sulphate, hydroxyapatite, calcium phosphate, bisphosphonate, [16], and recombinant human Bone Morphogenetic Proteins (rh-BMPs-rh-BMP2 and rh-BMP7) as well as other tissue engineering techniques [10], which are used either individually or in combination with other agents [15].

In view of this, we have come up with this new simple intra-operative technique of autograft harvesting using the excised femoral head to obtain good quality cancellous autograft which can be used to correct or close massive acetabular bone defects during Total Hip Replacements (THR). This technique which has not been described in the literature before, is also quick, easily to learn, easy to teach, and as mentioned earlier, does not require any sophisticated equipment or extra cost to be incurred. In addition to that, because the bone graft harvest process is part of the normal procedure for a THR, there is no need to obtain a separate consent from the patient.

Furthermore, there is no problem of donor site morbidity, no extra risk of infection, neurovascular injury, wound problems, fractures or issues of quantity which are usually encountered in autograft harvesting from other distant sites. Also, as opposed to allograft, the issue of disease transmission, immunological rejection or biocompatibility does not arise, and our method is much cheaper than using allograft or artificial bone substitutes. The femoral head is usually big enough to provide the desired amount of bone graft which can be used for a large amount of acetabular bone loss or defects.

Conclusion

We advocate the use of this simple technique by all Orthopaedic surgeons especially in arthroplasty procedures, as it provides a good alternative and cheap source of bone graft, which can be used as a bail out to repair massive bone loss or acetabular defects during procedures such as Total Hip Replacement. This can also help to avoid or minimize delays intra-operatively, and therefore keep the operating time short, with the attendant overall benefit to the patient.

References

1. Lehr A, Oner F, Hoebink E, Kempen D, van Susante J, Castelein R, et al. Patients Cannot Reliably Distinguish the Iliac Crest Bone Graft Donor Site From the Contralateral Side After Lumbar Spine Fusion: A Patient-blinded Randomized Controlled Trial. *Spine (Phila Pa 1976)*. 2019;44(8):527-33.
2. Azi M, Aprato A, Santi I, Kfuri M, Masse A, Joeris A. Autologous bone graft in the treatment of post-traumatic bone defects: a systematic review and meta-analysis. *BMC Musculoskelet Disord*. 2016;17(1):465.
3. Loisel F, Pluvy I, Kielwasser H, Panouilleres M, Obert L, Lepage D. Technical note on the harvesting of rib osteochondral autografts for upper limb bone and joint repair surgery. *Hand Surg Rehabil*. 2018;37(6):337-41.

4. Hamada Y, Hibino N, Kobayashi A. Expanding the utility of modified vascularized femoral periosteal bone-flaps: An analysis of its form and a comparison with a conventional-bone-graft. *J Clin Orthop Trauma*. 2014;5(1):6-17.
5. Hirao M, Ebina K, Etani Y, Tsuboi H, Noguchi T, Tsuji S, et al. Use of autologous bone grafting from the calcaneus and interconnected porous hydroxyapatite ceramic for bone transplantation in rheumatoid foot surgery. *SAGE Open Med Case Rep*. 2018;6:2050313X18784413.
6. Ishihara K, Okazaki K, Akiyama T, Akasaki Y, Nakashima Y. Characterisation of osteophytes as an autologous bone graft source: An experimental study *in vivo* and *in vitro*. *Bone Joint Res*. 2017;6(2):73-81.
7. Huang YC, Chen CY, Lin KC, Renn JH, Tarng YW, Hsu CJ, et al. Comparing morbidities of bone graft harvesting from the anterior iliac crest and proximal tibia: a retrospective study. *J Orthop Surg Res*. 2018;13(1):115.
8. Higgins T, Marchand L. Basic Science and Clinical Application of Reamed Sources for Autogenous Bone Graft Harvest. *J Am Acad Orthop Surg*. 2018;26(12):420-8.
9. Fischer C, Cassilly R, Cantor W, Edusei E, Hammouri Q, Errico T. A systematic review of comparative studies on bone graft alternatives for common spine fusion procedures. *Eur Spine J*. 2013;22(6):1423-35.
10. Oryan A, Alidadi S, Moshiri A, Maffulli N. Bone regenerative medicine: classic options, novel strategies, and future directions. *J Orthop Surg Res*. 2014;9(1):18.
11. Tanner M, Heller R, Westhauser F, Miska M, Ferbert T, Fischer C, et al. Evaluation of the clinical effectiveness of bioactive glass (S53P4) in the treatment of non-unions of the tibia and femur: study protocol of a randomized controlled non-inferiority trial. *Trials*. 2018;19(1):299.
12. Lin N, Li H, Li W, Huang X, Liu M, Yan X, et al. Upshifting the Ipsilateral Proximal Femur May Provide Satisfactory Reconstruction of Periacetabular Pelvic Bone Defects After Tumor Resection. *Clin Orthop Relat Res*. 2018;476(9):1762-70.
13. Heindel Koan, Preston G, Tharp J. Chronic Morbidity of a Pilot Hole Burr Technique for Anterior Iliac Crest Autograft in Cervical Fusion. *Orthopedics*. 2019;42(1):e68-73.
14. Labutin D, Vorobyov K, Bozhkova S, Polyakova E, Vodopyanova T. Human bone graft cytocompatibility with mesenchymal stromal cells is comparable after thermal sterilization and washing followed by γ -irradiation: an *in vitro* study. *Regen Biomater*. 2018;5(2):85-92.
15. Wang, W, Yeung K. Bone grafts and biomaterials substitutes for bone defect repair: A review. *Bioact Mater*. 2017;2(4):224-47.
16. Schlickewei C, Laaff G, Andresen A, Klatte T, Rueger J, Ruesing J, et al. Bone augmentation using a new injectable bone graft substitute by combining calcium phosphate and bisphosphonate as composite--an animal model. *J Orthop Surg Res*. 2015;10:116.