



A Rare Case of Primary Posterior Mediastinal Pleural Ancient Schwannoma

Yee AC^{1*}, Karim FW¹ and Giashuddin S²

¹Department of Internal Medicine, New York Presbyterian Brooklyn Methodist, USA

²Department of Anatomic Pathology, New York Presbyterian Brooklyn Methodist, USA

Abstract

Ancient schwannoma is a rare subtype of schwannomas that is generally benign and primarily discovered incidentally through imaging findings. The tumor is characteristically slow-growing and frequently seen to undergo transformative changes such as cystic or myxoid degeneration which can at times lead to erroneous diagnosis of a malignant growth. Ancient schwannomas derive from Schwann cells and can arise at any location with nerve sheaths however they are typically found in the head and neck and less commonly so in the pleura. Here, we report a case of a primary posterior mediastinal ancient schwannoma of the pleura discovered incidentally in a man who initially presented with a chief complaint of cough.

Introduction

Schwannoma is a benign peripheral nerve sheath tumor that also includes neurofibromas and perineuriomas [1]. They typically arise in the head, neck, and extremities and represent roughly 1% to 2% of thoracic tumors [2]. Other locations of origin have also been described including the retroperitoneum, intraparotid, orbit, and pleura but these areas are quite uncommon and less reported in comparison. Additionally, and very rarely, they can undergo regressive changes in the form of myxoid degeneration, nuclear pleomorphism, vascular hyalinization, remote hemorrhage, focal necrosis, calcification, and cystic transformation. This subtype of morphologic changes in the tumor is referred to as “ancient”, due to the characteristic slow growth rate and the assumption that, upon discovery, they had already been present for a very long time. Because of this, diagnosis is generally incidental and commonly found in elderly patients [2,3]. Their discovery is made once the tumor reaches a certain size causing mass effect of the surrounding structures which generally presents with neurologic findings such as pain, weakness, or sensory loss. Moreover, as these tumors present with atypical features, they are often misdiagnosed as malignant [4]. At the time of our review, there were only a handful of cases of pleural ancient schwannomas reported.

Objective

To describe a rare case of an ancient schwannoma discovered in the parietal pleura of a relatively healthy male and to increase recognition of the tumor by highlighting its characteristic histopathology and radiologic findings to guide management.

Case Presentation

A 52-year-old male with a 20-pack-year smoking history and prior appendectomy who was otherwise healthy and had no relevant family, psychosocial, or remaining surgical history presented to the clinic for a surgical evaluation of a recent incidental finding of a right pleural-based mass. He had initially obtained chest radiography for a cough of undetermined duration and without other symptomatology which showed an abnormality in the right pleura (Figure 1). Subsequent CT chest imaging showed a 4.9 cm sharply-marginated right pleural-based mass along the 8th rib (Figure 2A). Further evaluation with FDG-PET scan redemonstrated a posterior mediastinal mass in the same region (Figure 2B) and without significant radiotracer uptake throughout the body. MRI imaging showed no mass extension into the neural foramina (Figure 3). The patient then underwent Video-assisted thoracoscopic surgery for wedge resection and to exclude malignancy. Eventual pathology diagnosis revealed ancient schwannoma including immunophenotyping positive for Bcl-2, Sox-10, and S-100 with a low proliferation index by Ki-67 stain. The patient had an uneventful recovery and was discharged one day after the procedure. He returned to the clinic two weeks later without significant complaints.

OPEN ACCESS

*Correspondence:

Aaron C Yee, Department of Internal Medicine, New York Presbyterian Brooklyn Methodist, 506 6th Street, Brooklyn, NY 11215, USA, Tel: 347-342-6550;

E-mail: aay9004@nyp.org

Received Date: 02 Feb 2023

Accepted Date: 03 Mar 2023

Published Date: 07 Mar 2023

Citation:

Yee AC, Karim FW, Giashuddin S. A Rare Case of Primary Posterior Mediastinal Pleural Ancient Schwannoma. *Clin Surg*. 2023; 8: 3628.

Copyright © 2023 Yee AC. This is an open access article distributed under the Creative Commons Attribution License, which permits unrestricted use, distribution, and reproduction in any medium, provided the original work is properly cited.

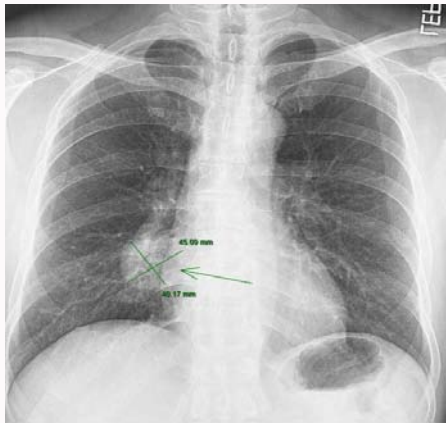


Figure 1: Right pleural lesion measuring up to 45 mm in the largest dimension.

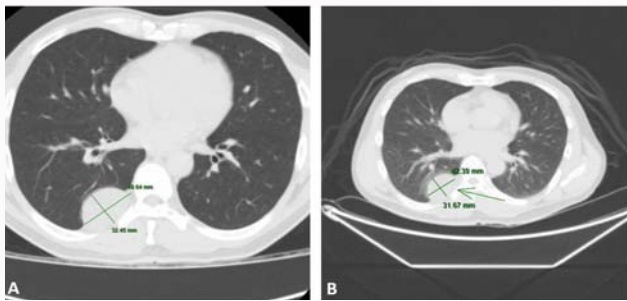


Figure 2: (A) CT chest showing a roughly 4.9 cm sharply-margined right pleural-based mass along the 8th rib. (B) FDG-PET showing a roughly 4.3 cm x 3.1 cm posterior mediastinal mass.

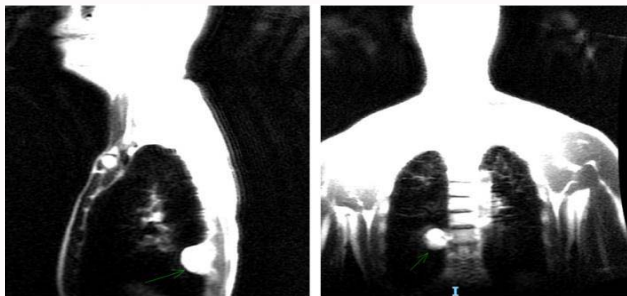


Figure 3: MRI showing redemonstration of pleural-based mass measuring up to 3.4 cm in largest dimension without mass extension into the neural foramina.

Discussion

Ancient schwannomas are a very rare subtype of schwannomas, which also include microcystic-reticular, epithelioid, cellular, psammomatous, and melanotic variations that are all classified based on their histological findings [5]. They are reported to represent roughly 0.8% of all soft tissue tumors [6]. Schwannomas, which are also referred to as neurilemmomas, neurinomas, and perineural fibroblastomas are encapsulated nerve sheath tumors. They are generally discovered in the head and neck areas (25% to 50%), flexor aspects of the limbs, and major nerve trunks including the spinal roots, cervical plexus as well as the vagus, peroneal and ulnar nerves [7,8]. Very rarely they have also been reported in deeply situated structures such as in the posterior mediastinum, retroperitoneum,

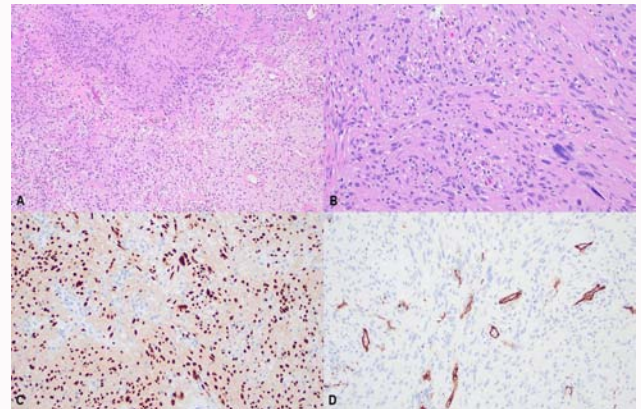


Figure 4: Histologic and immunohistochemical characteristics of schwannoma with ancient features: (A). Typical histologic features of Antoni-A and Antoni-B areas in the upper half of the image and degenerative changes shown in the lower half of the image. (B). Enlarged and hyperchromatic nuclei also noted in Antoni-A areas. Immunohistochemical staining (C) SOX-10 shows nuclear positivity in neoplastic cells, whereas a CD34 stain (D) is non-reactive which excludes the possibility of a solitary fibrous tumor.

orbit, and adrenal glands [6,9-11]. The classification of “ancient” stems from the tumor’s inherent slow-growing nature and likely long-term presence by the time of its discovery. Because of the slow growth, these tumors are generally benign and do not typically cause symptoms. However, given the deeper locations within the body cavity of some of these tumors, patients may become symptomatic by virtue of sheer size alone and subsequent impingement on neighboring structures [7]. Malignant transformation or metastatic involvement to the peripheral nerve, termed Malignant Peripheral Nerve Sheath Tumor (MPNST), is possible but not very common and patients will present with pain, weakness, and sensory deficits more frequently. Additionally, neurofibromatosis type 1 was found to be associated with up to 50% of patients with MPNST and von Recklinghausen syndrome in up to 5% to 18% of cases with malignant transformation [6,7].

Schwannomas are typically diagnosed definitively through biopsy, and as a result, they often pose a difficult challenge to diagnosticians upon discovery. Imaging is the most useful modality on initial evaluation and is oftentimes the first to detect such tumors however radiological findings are non-specific and more often than not generalized as malignancy. MRI is the most helpful imaging technique as it can demonstrate the presence of a mass and whether that mass is intrinsic versus extrinsic to a nerve or whether there is involvement of adjacent structures. T1-weighted images of schwannomas have similar signal intensities to muscle and may be difficult to discern, however T2-weighted imaged schwannomas show higher signal intensities. Additionally, the nerve sheath capsule can be visualized on MRI with one study demonstrating detection of a low intensity rim in roughly 70% of schwannomas [7]. Nonetheless, the modality falters in identifying the specific type of tumor as there are no definitive pathognomonic signals to characterize ancient schwannomas [7]. By the time of their discovery, ancient schwannomas are generally large and may present as an eccentric mass with splaying of the nerve fibers. And, because they are considerably larger, they may have secondary changes such as myxoid degeneration, nuclear pleomorphism, vascular hyalinization, remote hemorrhage, focal necrosis, calcification, and cystic transformation which can also be discovered on MRI imaging [2,3,7]. CT imaging,

on the other hand, is less reliable as discovered masses can appear as iso to hypodense in comparison to muscle and will not be well-differentiated. Still, others propose that electrodiagnostic testing can also help contribute to further evaluation by localizing specific nerves or nerve plexus that may be involved which may potentially direct surgical management [12]. If concerned about metastatic conversion or involvement, FDG-PET can be utilized to differentiate MPNST from benign schwannomas [7,12].

Because the vast majority of these tumors are discovered incidentally and not definitively diagnosable through imaging studies as above, identification through characteristic histological findings is imperative. Microscopically, schwannomas display two different patterns, designated as Antoni Type A and Antoni Type B, the former of which is associated with hypercellularity and compact spindle cells most commonly arranged in either a palisading or an organoid (Verocay bodies) fashion, while the latter is represented by hypercellularity admixed with a myxomatous matrix [1,13,14]. Along with these findings, ancient schwannomas are also characterized as having hyperchromatic nuclei without mitoses, fibrosis, hyalinization, hyperchromasia, and hemosiderin deposition [5,13,15].

Although malignant transformation of schwannomas or ancient schwannomas have been reported in literature, a majority of cases are benign with indolent behaviors and malignant variations are extremely rare [2,3,13]. In a study of 686 mediastinal tumors, 20.7% were schwannomas, and of that portion, only 1.9% of them were malignant [2,13,16]. In our case, because initial imaging findings were nonspecific of a pleural mass, subsequent imaging was performed to not only characterize the mass but also to determine the possibility of metastases. Additionally, prior to surgical exploration and resection, MRI was performed to determine any extension of the mass. Once excised and analyzed, routine staining demonstrated schwannoma with ancient features including Antoni Type A and Antoni Type B areas along with degenerative changes, hyperchromatic nuclei (Figure 4). Subsequent immunohistochemical stains confirmed ancient schwannoma without evidence of malignancy, as well as, ruled out most common tumors in that particular location (e.g., solitary fibrous tumor).

Conclusion

In summary, ancient schwannomas are a rare variation of schwannomas. Although imaging can be utilized to detect its initial presence and help provide information on the extent of disease and disease burden, there are no clearly defined characteristic imaging findings for diagnosis. The gold standard for diagnosing schwannomas is through histologic studies from biopsy and/or surgically resected specimens. The mainstay of treatment is complete surgical resection with preservation of neighboring structures.

References

1. Iwasaki T. Giant ancient schwannoma of the pleura: Commentary. *Lung India*. 2016;33(4):449-50.
2. Bibby AC, Daly R, Internullo E, Edey AJ, Maskell NA. Benign pleural schwannoma presenting with a large, blood-stained pleural effusion. *Thorax*. 2018;73(5):497-8.
3. Canella C, Costa F, Klumb E, Aymoré IL, Marchiori E. Ancient schwannoma. *Arthritis Rheum*. 2013;65(8):2036.
4. Lee YS, Kim JO, Park SE. Ancient schwannoma of the thigh mimicking a malignant tumour: A report of two cases, with emphasis on MRI findings. *Br J Radiol*. 2010;83(991):e154-7.
5. Ho CF, Wu PW, Lee TJ, Huang CC. "Ancient" schwannoma of the submandibular gland: A case report and literature review. *Medicine (Baltimore)*. 2017;96(51):e9134.
6. Ratnagiri R, Mallikarjun S. Retroperitoneal ancient schwannoma: Two cases and review of literature. *J Cancer Res Ther*. 2014;10(2):368-70.
7. Pilavaki M, Chourmouzi D, Kiziridou A, Skordalaki A, Zarampoukas T, Drevelengas A. Imaging of peripheral nerve sheath tumors with pathologic correlation: pictorial review. *Eur J Radiol*. 2004;52(3):229-39.
8. Alotaiby F. Ancient Schwannoma: Case Report of an unusual entity in an unusual oral location. *Am J Case Rep*. 2022;23:e938335.
9. Hellmann AR, Szymański M, Śledziński M, Biernat W, Preis-Hellmann A. "Ancient" Schwannoma of the adrenal gland pretending to be melanoma metastasis. *Pol Arch Intern Med*. 2022;132(6):16260.
10. Kim KS, Jung JW, Yoon KC, Kwon YJ, Hwang JH, Lee SY. Schwannoma of the Orbit. *Arch Craniofac Surg*. 2015;16(2):67-72.
11. Shanmugasundaram G, Thangavel P, Venkataraman B, Barathi G. Incidental ancient schwannoma of the posterior mediastinum in a young male: a rare scenario. *BMJ Case Rep*. 2019;12(5):e227497.
12. Perrin RG, Guha A. Malignant peripheral nerve sheath tumors. *Neurosurg Clin N Am*. 2004;15(2):203-16.
13. Chan PT, Tripathi S, Low SE, Robinson LQ. Case report - Ancient schwannoma of the scrotum. *BMC Urol*. 2007;7:1.
14. Cherem-Kibrit M, Zonana-Schatz E, Alvarado-Silva C. Primary pleural schwannoma as incidental findings: An unusual case report. *EMJ Oncol*. 2022.
15. Abdellatif E, Kamel D, Mantilla JG. Schwannoma. *PathologyOutlines.com*. Accessed December 7th, 2022.
16. Ingels GW, Campbell DC, Giampetro AM, Kozub RE, Bentlage CH. Malignant schwannomas of the mediastinum. Report of two cases and review of the literature. *Cancer*. 1971;27(5):1190-201.