



## A New Treatment for Primitive Neuroectodermal Tumor (PNET) of Prostate: Total Pelvic Exenteration (TPE) and Double Diversion

Lichen Teng, Wei Liangjun, Yongpeng Xu and Changfu Li\*

Department of Urology, Harbin Medical University Cancer Hospital, Harbin city, China

### Abstract

**Introduction:** To report a rare case of Primitive Neuroectodermal Tumor (PNET) of prostate and to present a new surgical method for PNET of prostate.

**Materials and Methods:** A 27-year-old male was admitted to Harbin Medical University Cancer Hospital (Harbin, China) for dysuria and dyschezia, magnetic resonance imaging (MRI) reveal a large mass that may involve bladder and rectum in the prostate region. Histopathological analysis of biopsy of prostate indicated mesenchymal origin tumor, and immunohistochemistic confirmed diagnosis of PNET of prostate. En bloc Total Pelvic Exenteration (TPE) and double barrel sigmoidostomy were performed. Double stomas in the skin incision are used for fecal and urinary diversion, respectively.

**Results:** Related complications, such as urinary tract infection and ileus do not occur. Short-term outcome in the case is satisfactory, normal diet can be taken. However long-term efficacy remains to be evaluated.

**Conclusion:** Clinical features of PNET of prostate should be paid much more attention and radical surgery is recommended.

**Keywords:** Prostate; Primitive neuroectodermal tumor; Total pelvic exenteration; Double barrel sigmoidostomy

### OPEN ACCESS

#### \*Correspondence:

Changfu Li, Department of Urology, Harbin Medical University Cancer Hospital, Harbin city, Postal code: 150080, China, Tel: +86-0451-85718001; Fax: +86-0451-86663760; E-mail: lichangfu2015@sina.com

Received Date: 05 Sep 2017

Accepted Date: 15 Nov 2017

Published Date: 23 Nov 2017

#### Citation:

Teng L, Liangjun W, Xu Y, Li C.

A New Treatment for Primitive Neuroectodermal Tumor (PNET) of Prostate: Total Pelvic Exenteration (TPE) and Double Diversion. *Clin Surg.* 2017; 2: 1758.

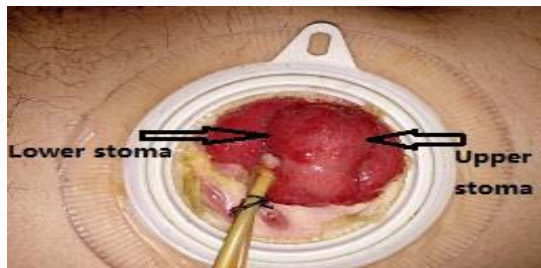
Copyright © 2017 Changfu Li. This is an open access article distributed under the Creative Commons Attribution License, which permits unrestricted use, distribution, and reproduction in any medium, provided the original work is properly cited.

### Introduction

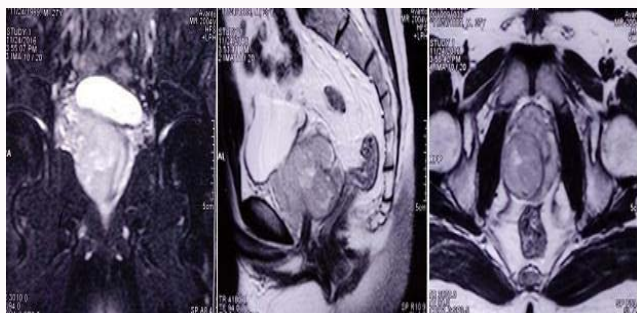
According to the tissue of origin, Primitive Neuroectodermal Tumor (PNTE) is divided into central PNTE and peripheral PNTE. A large size of infiltrative soft mass is a common feature of them [1]. Incidence of PNET occurring in urological organs is very low, previous reports about PNET mainly originated from kidney, bladder, and adrenal glands and so on. Compared with these organs, PNET of prostate is rarer, until to 2003, Peyromaure M documented first case in the world. Up to date, only less than twenty cases of PNET of prostate. The disease appears clinical features of tumors of mesenchymal tissue, such as poor prognosis and lack of optimal model of treatment. Combined therapies are considered now, including surgery, chemotherapy, radiotherapy and so on. How to choice optimal therapy is difficult for urologic oncologists. At December of 2016, we treated a case of PNET of prostate using total pelvic exenteration and double barrel sigmoidostomy, the patient obtains satisfactory efficacy following surgery.

### Case Presentation

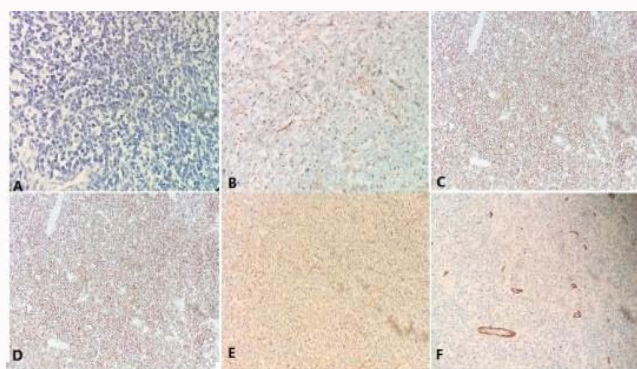
A 27-year-old male patient presented to Outpatient of Harbin Medical University Cancer Hospital (Harbin, China), who complained symptoms of dysuria and dyschezia for two weeks. Moreover, he has indwelled catheter for two days in the local hospital. After the patient was hospitalized, the result of digital rectal examination indicated that a large smooth mass significantly swelled to the rectal cavity. Laboratory examination showed that value of serum Prostate Special Antigen (PSA) was 1.52 ng/mL and white blood cells (WBC) were  $13 \times 10^9/L$ , and the magnetic resonance imaging (MRI) revealed a mass of 84 mm × 78 mm × 72 mm replaced the prostate gland, which may involve posterior wall of bladder and anterior wall of rectum (Figure 1). Transrectal biopsy of the prostate gland was performed. Pathological analysis demonstrated malignant tumor of prostate gland mesenchymal origin and untypical morphology. The tumor cells were positive for Desmin and Vim and negative for CD34, CD117 and SMA. The patient was diagnosed as large



**Figure 1:** T2-weighted MRI show a large mass in prostate region, which replaced prostate gland.



**Figure 2:** Double barrel sigmoidostomy: upper stoma is used for fecal diversion, and lower one is used for urinary diversion.



**Figure 3:** Representative images with E staining and immunohistochemistic staining (x 200).

**A.E.** Staining revealed a lot of small round cells distributed in tumor region.  
**B.** Immunohistochemistic staining demonstrating small round cells positive for CD99; **C and D** reveal small round cells is positive for CD56 and Vim, respectively. **E** and **F** show small round cells negative for CK and CD34, respectively.

prostate tumor and urinary tract infection. After antibiotic treatment of couple days, we carefully communicate with the patient and his dependants about plan for treatment. Finally, we performed total pelvic exenteration and double barrel sigmoidostomy.

During operation, we found a large firm mass companied with surrounding tissue edema, which filled and fixed in pelvic cavity. After en bloc resection of total pelvic organs, 15-cm distal sigmoid colon of stoma was closed. Bilateral ureters were anastomosed end-to-side with sigmoid colon respectively, in which stents were indwelled. The anastomotic site was placed in retroperitoneal space. While faeces are evacuated through upper stoma, urine is discharged via lower one (Figure 2). At 48 h after operation, the patient started to drink, and the patient was allowed to eat at day 4 post-operation. At day 5 post-operation, the patient can freely ambulate, and he was discharged

from hospital at week 2 post-operation. The histopathological study revealed that area of tumor filled with small round cells (Figure 3 A), indicating a PNET, moreover, bladder and rectum were involved, and pelvic lymph nodes has not found metastasis. The cells were positive for Vim, CD56 and CD99 (Figure 3B-D), and negative for CK and CD34 (Figure 3E and 3F).

**Discussion**

PNET is kind of extremely rare malignant tumor with high aggressiveness. Early diagnosis and timely radical surgery would contribute to prolong survival. Therefore, to improve the rate of early diagnosis and obtain satisfactory outcome, it is very important to deeply understand its clinical features, and to reasonably choose treatment regimen.

**Clinical features**

Peripheral PNET can originate from different organs or tissues, such as lung, liver and vertebra and so on, however, PNET of urologic organs-origin is rare, among them, kidney is a mainly organ of origin, compared with which, incidence of PNET of prostate gland is much less. Additionally, the disease commonly occurs in range in age of 20 to 30-year-old. To our best knowledge, from 2003 to now total sixteen cases along with our case have been reported [2-13], median age is 27 years. Due to insidious onset, there is commonly asymptomatic for the patients at early stage, thereafter, with increasing of tumor size, significant dysuria and dyschezia would seriously affect life of the patients, hematuria and chronic anal pains are also complained by some patients, in addition, a lot of residual urine and frequent indwelling catheter also result in refractory urinary tract infections. All of cases exhibited large diameter of primary tumor (>5 cm) at diagnosis. Digital rectal exam should be performed. Similarly to our case, the value of PSA maintain in the normal range in most cases except for two cases. 7,8 Primary tumor appear rapid progress, in the present case, the diameter of tumor increase by about 1 cm duration one month, incidence of multiple distal metastases for PNET of prostate gland is low, two cases of pulmonary and lymph node metastasis were reported [9-11]. Imaging examinations, such as Computed Tomography (CT) and MRI can show a large occupying lesion replaced prostate gland in the pelvic cavity, which may involve and shift surrounding organs, such as bladder, rectum or seminal vesicles. Except for some necessary imaging examinations, establishment of PNET of prostate gland mainly rely on immunohistochemistic staining, which can confirm PNET by positive for CD99 and/or other neuronal markers in a lot of small round cells, at the same time, lymphoma and myogenic tumor need to be excluded.

**Treatment**

Due to low incidence of PNET of the prostate and cohort study of large number of cases, currently, the standard treatment regimen has not yet been established. In the previous studies, combined therapy with surgery, neoadjuvant or adjuvant chemotherapy and radiation therapy were effective, and most of cases underwent radical prostatectomy [2,3,9,11]. Because peripheral PNET prong to develop distant metastases and local recurrence within 2-3 year after surgery, to decrease this possibility, as for localized PNET of prostate [14], we performed aggressively an en bloc total pelvic exenteration in the present case, and double barrel sigmoidostomy is used for with both the urinary and fecal diversions [15]. Compared with ureterostomy or urinary conduit diversion, we take advantage of reflected part of

sigmoid colon with end in subtle ways as urinary diversion. It is helpful to nurse stoma and improve quality of life, more importantly, the operation has not increase incidence of related complications, such as gut leakage and urinary tract infection; moreover, surgical complexity is not increased furthermore. The long-term outcome remains to be evaluated in the future. Except for radical surgery, chemotherapy is a potentially effective treatment for localized PNET of the prostate [16]. Chemotherapeutic agents include incristine (V), driumycin/ Doxorubicin (A), cyclophosphamide (C) and Actinomycin-D, which are commonly used in combination with each other [17]. In conclusion, although PNET of prostate is extremely rare, but urologic oncologists should pay much more attention to the young male patients with above mentioned clinical features. To minimize the harm of the disease, radical surgery should be performed as early as possible in localized PNET of prostate, combined therapy is help to improve efficacy of treatment.

### Compliance with Ethical Standard

The study was supported by Heilongjiang postdoctoral scientific research developmental fund (LBH-Q15104) and by a grant from Heilongjiang Provincial Department of Public Health (670). All procedures performed in studies were in accordance with the ethical standards of the institutional and national research committee and with the 1964 Helsinki declaration, and informed consent was obtained from patient in the study.

### References

- Virani MJ, Jain S. Primary intraspinal primitive neuroectodermal tumor (PNET): a rare occurrence. *Neurology India*. 2002;50(1):75-80.
- Peyromaure M, Vieillefond A, Boucher E, De Pinieux G, Beuzeboc P, Debré B, et al. Primitive neuroectodermal tumor of the prostate. *J Urol*. 2003;170(1):182-3.
- Colecchia M, Dagrada G, Poliani PL, Messina A, Pilotti S. Primary primitive peripheral neuroectodermal tumor of the prostate. Immunophenotypic and molecular study of a case. *Arch Pathol Lab Med*. 2003;127(4):e190-3.
- Thee N, Rastogi D, Arya S, Singh A, Rao P, Chandge A, et al. Primitive neuroectodermal tumour of the prostate gland: ultrasound and MRI findings. *Br J Radiol*. 2007;80(956):e180-3.
- Al Haddabi I, Al Bahri M, Burney I. Cytokeratin-positive primitive neuroectodermal tumor of the prostate: case report and review of literature. *Indian J Pathol Microbiol*. 2012;55(4):569-71.
- Kumar V, Khurana N, Rathi AK, Malhotra A, Sharma K, Abhishek A, et al. Primitive neuroectodermal tumor of prostate. *Indian J Pathol Microbiol*. 2008;51(3):386-8.
- Zhao SM, He CH, Ren JK. Primitive neuroectodermal tumour of the prostate and lung metastasis: a case report. *Chin J Urol*. 2013;34:737.
- Liu Z, Pu JX. Primitive neuroectodermal tumour of the prostate: two case report and literature review. *Literature of No.15 Chinese Urology Academic Conference*. 2008.
- Funahashi Y, Yoshino Y, Hattori R. Ewing's sarcoma/primitive neuroectodermal tumor of the prostate. *Int J Urol*. 2009;16(9):769.
- Mohsin R, Hashmi A, Mubarak M, Sultan G, Shehzad A, Qayum A. Primitive neuroectodermal tumor/Ewing's sarcoma in adult uro-oncology: A case series from a developing country. *Urol Ann*. 2011;3(2):103-7.
- Wu T, Jin T, Luo D, Lin Chen, Xiang Li. Ewing's sarcoma/primitive neuroectodermal tumor of the prostate: A case report and literature review. *Can Urol Assoc J*. 2013;7(5-6): E458-E9.
- Li X, Bu R. One case report of prostate primitive neuroectodermal tumor performed hematuria and literature review. *Modern Oncol*. 2015;23:2031-4.
- Liao C, Wu X, Wang X, Li H. Primitive neuroectodermal tumor of the prostate: Case report from China. *J Cancer Res Ther*. 2015;11(3):668.
- Song HC, Sun N, Zhang WP, Huang CR. Primary Ewing's sarcoma/primitive neuroectodermal tumor of the urogenital tract in children. *Chin Med J (Engl)*. 2012;125(5):932-6.
- Mao Q, Li H, Xiao L. Retrospective analysis of surgical treatment for adult prostate sarcoma. *Chin J Urol*. 2016;37:30-3.
- Balamuth NJ, Womer RB. Ewing's sarcoma. *Lancet Oncol*. 2010;11(2):184-92.
- Tan Y, Zhang H, Ma GL, En-hua Xiao, Xiao-chun Wang. Peripheral primitive neuroectodermal tumor: dynamic CT, MRI and clinicopathological characteristics--analysis of 36 cases and review of the literature. *Oncotarget*. 2014;5(24):12968-77.