



## A Case of Severe Mega Colon: Clinical Image

Agostino Roasio\*

Department of Anesthesia and Intensive Care Unit, "Cardinal Massaia" Hospital, Italy

### Clinical Image

We describe the case of a 22 year-old male affected by congenital anal atresia that underwent repairing surgery 20 years ago. During the last seven years he has been suffering from frequently occlusive episode. He arrived at the emergency department for severe abdominal pain, nausea and vomiting. His abdomen was very painful and taut. When the patient was waiting for a diagnostic CT scan he was hit by pulse less activity cardiac arrest consequent to severe hyperkalemia (Figure 1). After cardiopulmonary resuscitation the patient returned to spontaneous circulation and a hemodynamic stability was obtained. Therefore, diagnostic exams were completed; in particular CT scan demonstrated a severe colic dilatation (14 cm) causing compression on both the femoral artery and subsequent hypoperfusion (Figure 2). A surgical attempt was decided; total colic resection associated to fasciotomy of the legs was practiced with the aim to improve general condition and perfusion of the lower extremities. Unfortunately he died after 20 days of recovery in intensive care unit.

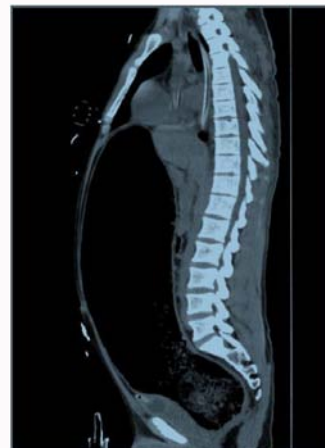

Figure 1: A diagnostic CT scan he was hit by pulse less activity cardiac arrest consequent to severe hyperkalemia.

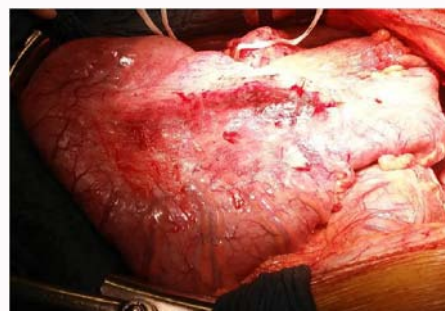


Figure 2: Causing compression on both the femoral artery and subsequent hypoperfusion.

### OPEN ACCESS

#### \*Correspondence:

Agostino Roasio, Department of Anesthesia and Intensive Care Unit, "Cardinal Massaia" Hospital, Asti, Italy,  
E-mail: aroasio@hotmail.com

Received Date: 31 Apr 2021

Accepted Date: 26 Apr 2021

Published Date: 29 Apr 2021

#### Citation:

Roasio A. A Case of Severe Mega Colon: Clinical Image. Clin Surg. 2021; 6: 3153.

Copyright © 2021 Agostino Roasio.

This is an open access article distributed under the Creative Commons Attribution License, which permits unrestricted use, distribution, and reproduction in any medium, provided the original work is properly cited.