



# A 5-Years Report from a Multicenter Randomized Controlled Trial: Dental Implants with Conical *Versus* Internal Hex Connections

Tommaso Grandi<sup>1\*</sup>, Maurizio Cannata<sup>2</sup> and Rawad Samarani<sup>3</sup>

<sup>1</sup>Private Practice in Modena, Italy

<sup>2</sup>Private Practice in Rende (Cosenza), Italy

<sup>3</sup>Department of Periodontology, Saint-Joseph University, Beirut, Lebanon

## Abstract

**Purpose:** To compare implant failure, complications and radiographic bone level changes of dental implants with conical versus internal hex connections, 5 years after loading.

**Methods:** A total of 90 patients with partial edentulous were selected and randomly divided into two equal groups (n=45) in order to be subjected to implant positioning either with conical connection or with internal hex connection at three dental offices. Patients were followed for a period of 5 years. Outcomes considered were implant failures, any complications and marginal bone level changes.

**Results:** Three patients (6.7%) belonging to the conical group and one patient (2.2 %) belonging to the internal hex group dropped out. One implant (1.5%) failed in the conical group versus two implants (2.6%) in the internal hex group. There were no statistically significant differences in implant failures between the two groups (2.4% vs. 2.3%, difference 0.1%; 95% CI: -0.9; 5.1; p=0.584). Four complications occurred in the conical group and five in the internal hex group (9.5% vs. 11.4%, difference 1.9%; 95% CI: -0.7; 4.5; p=0.781).

Five years after loading, patients in the conical group lost an average of  $1.41 \pm 0.94$  peri-implant bone vs.  $1.38 \pm 0.89$  mm for patients in the internal hex group with no significant differences between treatment group (p=0.745). Both treatment groups lost statistically significant marginal peri-implant bone at 5-year post-loading; P=0.0001 for both conical and internal hex group.

**Conclusion:** No statistically or clinically significant differences were observed in outcomes 5 years after loading, between implants with conical and internal hex connection, hence clinicians can decide which type of connection to use according to their preferences.

**Keywords:** Complication; Dental implant; Conical connection; Internal hex; Peri-implant marginal bone

## Introduction

Titanium dental implants are an effective and reliable solution for replacing missing teeth with satisfying results in terms of rehabilitation of aesthetic and masticatory function. The osseointegration of dental implant in newly formed bone and the stability of hard/soft tissues around a dental implant are two important factors that directly influence its long term-success [1]. Following implant placement; it's common to observe marginal bone loss around implants. Peri-implant bone resorption <1.5 mm during the first year of loading and <0.2 mm annually thereafter, are considered acceptable values for successful placement [2]. To date different suppositions have been suggested to explain this phenomenon. Implant-abutment interface microgap is believed to be one of the possible causes. The micro space between the two elements can favor the bacterial colonization: Microorganisms can penetrate through a gap smaller than 10  $\mu$ m causing thread inflammation; bone resorption and influencing biological weed establishment [3-5]. Other important factors influencing the stability of peri-implant bone are surgical trauma, peri-implantitis, biologic width, and occlusal overload [6]. The latter is considered one of the major causes of loss of both marginal bone and osseointegration of successfully osseointegrated implants. Several studies, including animal ones, demonstrated that an excessive dynamic load can damage bone around integrated implant resulting in bone resorption [6], causing the formation of crater-like bone defects [7]. Based on the above,

## OPEN ACCESS

### \*Correspondence:

Tommaso Grandi, Private Practice in  
Modena, Via Contrada 323, 41126  
Modena, Italy phone: +39 3337095223;  
E-mail: t.grandi@grandiclinic.com

Received Date: 04 Aug 2021

Accepted Date: 20 Sep 2021

Published Date: 30 Sep 2021

### Citation:

Grandi T, Cannata M, Samarani R.  
A 5-Years Report from a Multicenter  
Randomized Controlled Trial: Dental  
Implants with Conical Versus Internal  
Hex Connections. *Clin Surg.* 2021; 6:  
3322.

**Copyright** © 2021 Tommaso  
Grandi. This is an open access  
article distributed under the Creative  
Commons Attribution License, which  
permits unrestricted use, distribution,  
and reproduction in any medium,  
provided the original work is properly  
cited.

the preservation of marginal bone is critical to avoid implant failure.

The implant-abutment connection is the point of transition from surgical to prosthetic phase [8], so it has an important role in the outcome of the implant therapy, because it affects peri-implant crestal bone change [9]. Historically the first implant abutment connection interface was the external hexagon connection, or “external hex”, introduced by Bran mark, initially with a height of 0.7 mm, and it is currently used [8,10]. The external hex connection proved to be unfavorable because it fractures more easily than other types of connections [11], and moreover, often it forms the micro-space at the abutment-implant interface promoting bacterial micro leakage [12].

To address the limitations of external connections, like micro movement problems and screw loosening, and to achieve a better aesthetic result, an internal connection has been developed. The main advantage of this connection lies in the better stress distribution and greater stability of the prosthetic screw [5]. There are different types of internal connections; the most widely used are the internal hex and the conical ones. The market of internal connections is growing rapidly as nearly each dental implant manufacturer has designed and developed their own connections and at the same time many of them claimed the efficiency and the performance of their product over competitors. Despite mechanical and clinical claims no data demonstrated the superiority of one type of connection compared to others in term of clinical outcomes. Only few Randomized Control Trials (RCTs) investigated the relation between the type of connection (internal and external) and the clinical and radiographic parameters related to marginal bone remodeling around implants [6,13,14]. By the way there are not significant evidence-based clinical data about the superiority of one implant connection to the others, assessed in terms of complications, peri-implant marginal bone loss, aesthetics and ease of use.

This RCT is the continuation of the previous study published 1 year after initial loading [15]. In this case data were collected at 5 years post-loading. The null hypothesis of this trial is the same one of the previous article, that there would be no difference in success rates, complications and peri-implant marginal bone level changes between the two connections.

## Materials and Methods

The present multicenter randomized clinical trial was conducted in Italy in three different private practices by three operators (MC, TG, RS) who performed all the surgical and prosthetic interventions. A total of 90 patients (30 for each clinician) with partial edentulous in the maxilla or mandible, requiring one implant-supported prosthesis, have been enrolled. All patients selected were 18 or older and able to sign an informed consent form. For patients needed more than one implant rehabilitation the operator chosen which site to include in the study after the screening visit.

The anatomical criteria considered as a requirement for inclusion in this trial was the presence of residual bone height of least 10 mm and thickness of at least 5 mm, measured on Computerized Tomography (CT) scans.

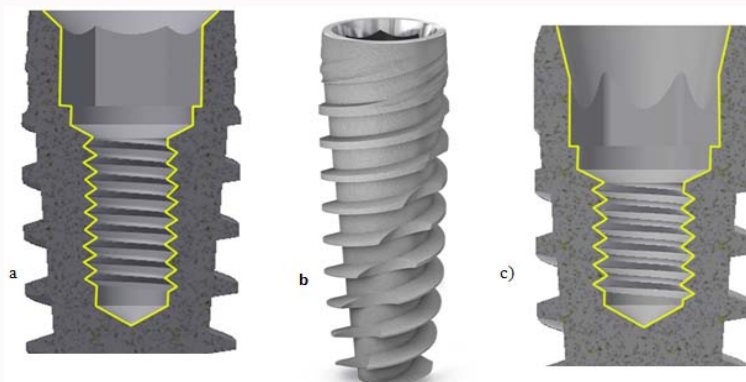
A pre-operative periapical radiography was firstly performed for an initial screening, then was used a computer tomography scan to quantify the amount bone. Broad inclusion criteria were used, including any type of bone quality, any jaw location and if patients were heavy smoker.

The other criteria applied to patients for the exclusion from the clinical trial are:

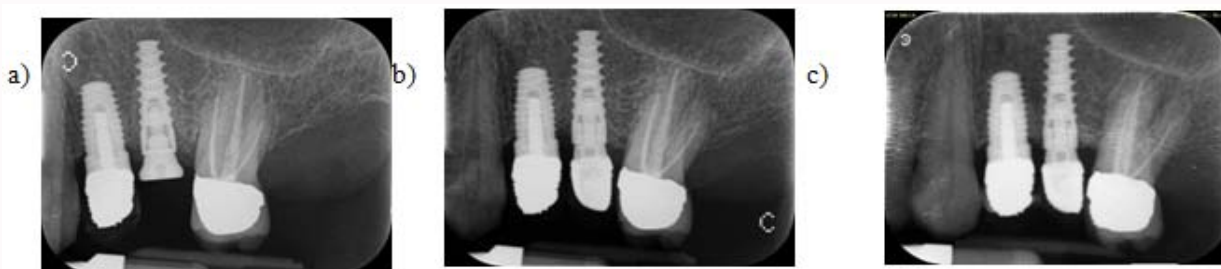- general contraindications to implant surgery
- subjected to irradiation in the head and neck area
- treated or under treatment with intravenous amino-bisphosphonates
- poor oral hygiene and motivation
- untreated periodontitis
- uncontrolled diabetes
- if they were pregnant or lactating
- substance abusers
- a lack of opposite occluding dentition in the area intended for implant placement
- an acute or chronic infection at the site intended for implant placement
- Patients referred only for implant placement that could not be monitored at the treating center.

All patients received detailed information regarding the study and the treatment foreseen by the clinical protocol, and signed a written informed consent prior to enrolment. Patient was categorized in three groups as per what they declared: Non-smoker, moderate smoker or heavy smoker (up to 10 cigarettes per day). The surgical technique performed by the operator reflected the best choice referring to patient conditions (i.e. flapless implant placement, immediate post extractive implants, submerged or non-submerged technique). Tapered titanium screw-shaped dental implants were used in the trial: They are characterized by the same macro design and sand-blasting acid-etched surface up to the neck but they have different internal connection (JD Icon vs. JD Evolution system, J Dental Care, Modena). The JD Icon implant is characterized by 12-degree internal conical connection with interlocking hexagon in the bottom. The JD Evolution implant has a 2 mm deep internal hex and a 45-degree internal bevel (Figure 1). Before the intervention all patients underwent at least one session of oral hygiene training and, if needed, a professionally delivered debridement. Antibiotic prophylaxis was obtained with 1 g of Amoxicillin and clavulanic acid, Augmentin Roche SpA, Milan Italy) every 12 hours from the day before surgery to the sixth postsurgical day. 500 mg of clarithromycin (Klacid, Abbott SRL, Rome, Italy) 1 h before the intervention and 250 mg twice a day for one week were given to patients allergic to penicillin.

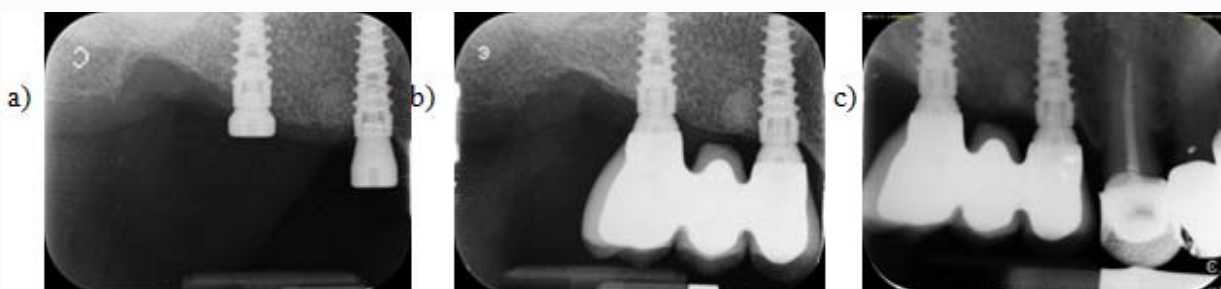Surgical procedures were performed under local anesthesia. When needed tooth extractions were performed as traumatically as possible, to preserve the buccal alveolar bone. Extraction sockets were carefully cleaned of any granulation tissue. Individual clinicians could decide whether to use the flap or flapless technique. The implant site was prepared according to what indicated by the implant manufacturer. Once the implant site preparation was completed, the operator was told if the implants to be placed had to be with conical or internal hex connection by opening a sequentially numbered sealed envelope corresponding to the patient recruitment number. Clinicians were free to decide to leave the implant submerged or not for the healing period. Periapical radiographs (baseline) were



**Figure 1:** Characteristics of the implants used in the study: **a)** external macro-design of the implant; **b)** sagittal section showing the conical connection of JD Icon implant; **c)** sagittal section showing the internal hex connection of JD Evolution implant.



**Figure 2:** Sequence of periapical radiographs of one of the patients treated with JD Icon implant with conical connection included in this study: **a)** implant placement; **b)** 1 year after loading; **c)** 5 years after loading.



**Figure 3:** Sequence of periapical radiographs of one of the patients treated with JD Evolution implants with internal hex connection included in this study: **a)** implant placement; **b)** 1 year after loading; **c)** 5 years after loading.

made with the paralleling technique. Patients were prescribed Chlorhexidine digluconate 0.2% mouthwash twice daily for 1-week post-surgery. After 3 months all the implants were loaded directly with definitive screw-retained or cemented restorations (Figure 2, 3). The three operators involved in the trial (MC, TG and RS) made all clinical assessments; therefore outcome assessors were not blind.

The primary outcome measures were

1. Implant failures, evaluated as implant mobility and removal of stable implants dictated by progressive marginal bone loss or infection. The stability of each implant was measured manually by tightening the abutment screw with a wrench delivering a torque of 30 Ncm, or by assessing the stability of single crowns using the metallic handles of two instruments. Spinning implants were recorded as failures.

2. **Complications:** Any biological and prosthetic complication occurred at the implant site during the entire follow-up time were

recorded and reported per study group.

The secondary outcome measure was peri-implant marginal bone level changes evaluated on intraoral radiographs taken with the paralleling technique at implant placement, 1 year and 5 years after loading. All measurements were taken by an independent, blinded assessor. Radiographs were scanned, digitized in JPG format and converted to TIFF format with a 600-dpi resolution. Image J 1.42 software (National Institute of Mental Health, Maryland, USA) was used to measure peri-implant marginal bone levels and it was calibrated for every single image according to the known implant diameter. Measurements of the mesial and distal crestal bone levels adjacent to each implant were made to the nearest 0.01 mm and averaged at patient level and then group level. The measurements were taken parallel to the implant axis. The most coronal margin of the implant collar and the most coronal point of bone-to-implant contact were taken as reference for linear measurements. No sample size calculation was performed. When the protocol was defined, it was

decided 30 patients should be enrolled in each of the three centers, and 45 patients were randomized to each group using computer generated random numbers which were inserted in sequentially numbered, opaque, sealed envelopes. Envelopes were opened only after the implant site was prepared, and this because the investigators in charge of enrolling and treating the patients didn't know the treatment allocation.

For the data analysis, the patient was considered as the statistical unit of the analyses. A doctor with expertise in statistics analyzed the data using the statistical package StatView (version 5.01.98, SAS Institute Inc, Cary, NC, USA), without knowing group allocation.

The t- test was used for the following evaluations:

- comparison of differences of mean at patient level for continuous outcomes between groups,
- within-group comparison (t-test for paired data)
- Differences in resorption in the two study groups.

Comparisons among centers were performed by one-factor analysis of variance using ANOVA. Differences in the proportion of patients with implant failures were compared among the centers using the chi-square test. Differences in crestal bone were compared among the centers using ANOVA. When necessary, prevalence of patient characteristics was compared by contingency tables and chi-square test. All statistical comparisons were conducted at 0.05 level of significance.

## Results

The three centers screened 98 patients for eligibility but 8 patients were not included because they were referred only for implant placement. Ninety patients were then consecutively enrolled in the trial and randomized to the conical group and to the internal hex group, 45 patients for each group according to a parallel group design. All patients were treated according to the allocated interventions. Four/90 patients (4.4%) dropped out before the completion of the 5-year post-loading follow-up.

Three dropouts (3/45, 6.7%) were in the conical group:

1. One patient did not attend the 5-years visit because he moved to another city (Dr Samarani)
2. One patient died after the 2-years follow-up (Dr Grandi)
3. One patient did not want to attend the 5-years follow up (Dr Grandi)
4. Only one dropout was recorded in the internal hex group (1/45, 2.2%):
5. One patient did not return for the delivery of the definitive crowns (Dr Cannata)

Patients were recruited and operated from February 2015 to July 2015. The follow-up for all patients was 5-years post-loading (last follow-up July 2020). The main baseline patient's features, divided by treatment group, are reported in Table 1. There were no significant baseline imbalances between the two groups in terms of sex, age, and smoke, opposite dentition and bone quality. In total 67 implants were inserted in the conical group and 72 implants were inserted in the internal hex group.

- **Implant failures:** One implant (1.5%) failed in the conical group

**Table 1:** Subjects' and interventions' characteristics.

	Conical group (n=45) (%)	Internal hex group (n=45) (%)
Females	25 (55.6%)	22 (48.9%)
Mean age at implant insertion (range)	52.3 ± 16.8 (23-79)	51.2 ± 17.3 (25-75)
Smoking up to 10 cigarettes/day	9 (20.0%)	8 (17.8%)
Smoking more than 10 cigarettes/day	4 (8.9%)	6 (13.3%)
Implants inserted in mandibles	38/67 (57.8%)	40/72 (53.3%)
Implants inserted in incisor	7 (10.4%)	8 (11.1%)
Implants inserted in canine	4 (6%)	7 (9.7%)
Implants inserted in premolar	31 (46.3%)	29 (40.3%)
Implants inserted in molar	25 (37.3%)	28 (38.9%)
Mean implant length	10.4 ± 1.6	10.8 ± 1.8
Mean implant diameter	4.3 ± 0.8	4.1 ± 0.7
Hard bone quality at implant site	16 (23.9%)	14 (19.4%)
Medium bone quality at implant site	45 (67.1%)	47 (65.3%)
Soft bone quality at implant site	6 (9%)	11 (15.3%)
Post extractive implants	22 (32.8%)	31 (43.1%)
Implants inserted flapless	25 (37.3%)	36 (50.0%)
Patients with implants submerged	2 (4.4%)	3 (6.7%)
Single crowns	32 (71.1%)	28 (62.2%)
Partial fixed prostheses	13 (28.9%)	17 (37.8%)

versus two implants (2.6%) in the internal hex group. The implant failed in the conical group displayed postoperative pain, edema and signs of infection with pus. It was mobile 3 weeks after placement in a heavy-smoker male. It was inserted as an immediate post-extractive implant in a premolar area in the maxilla. It was successfully replaced after 4 months. Two implants failed in the internal hex group in a non-smoker female. They were affected by peri-implantitis and became mobile after 3 years. They were not replaced. There were no statistically significant differences for patients experiencing implant failures between the two groups (patient's level, 1/42 vs. 1/44, 2.4% vs. 2.3%, difference 0.1%; 95% CI: -0.9; 5.1; p=0.584).

- **Complications:** Four complications occurred in the conical group and five complications occurred in the internal hex group. There was no statistically significant difference for patients experiencing complications between groups (patient's level, 4/42 vs. 5/44, 9.5% vs. 11.4%, difference 1.9%; 95% CI: -0.7; 4.5; p=0.781) and the three different centers (10.7% vs. 13.8% vs. 6.9%, p=0.691; Table 3).

- The following complications occurred for patients in the conical group:

- Postoperative pain and pus occurred at one immediate post-extractive implant. It was removed 3 weeks after its placement.

- One implant had peri-implant mucositis at 8 months post-implantation, solved by a curettage and 0.2% chlorhexidine mouthwash.

- One metal-ceramic crown displayed chipping 3 years after loading. The prosthesis was unscrewed and repaired in the laboratory.

- Loosening of one healing abutment after 3 weeks which was



**Table 2:** Mean radiographic peri-implant marginal bone levels and changes between groups and time periods according to per protocol analysis.

	Implant placement	1 year after loading	5 years after loading	Difference placement-5 years	P-value intragroup
	N Mean $\pm$ SD (95% CI)	N Mean $\pm$ SD (95% CI)	N Mean $\pm$ SD (95% CI)	N Mean $\pm$ SD (95% CI)	
Conical group	45 0.03 $\pm$ 0.06 (-0.03;0.09)	44 0.59 $\pm$ 0.61 (-0.02;1.20)	41 1.44 $\pm$ 0.81 (0.63;2.25)	41 1.41 $\pm$ 0.94 (0.47;2.35)	0.0001
Internal hex group	45 0.02 $\pm$ 0.05 (-0.03;0.07)	44 0.62 $\pm$ 0.65 (-0.03;1.27)	43 1.40 $\pm$ 0.79 (0.61;2.19)	43 1.38 $\pm$ 0.89 (0.49;2.27)	0.0001
P-value intergroup	0.393	0.822	0.657	0.745	

**Table 3:** Comparison between the three different centres: each centre treated 30 subjects.

	Grandi (n=30)	Cannata (n=30)	Samarani (n=30)	P-value
Drop-out	2/30 (6.7%)	1/30 (3.3%)	1/30 (3.3%)	0.6
Patients with implant failure	1/28 (3.6%)	1/29 (3.4%)	0/29 (0%)	0.98
Patients with complications	3/28 (10.7%)	4/29 (13.8%)	2/29 (6.9%)	0.691
Bone loss after 1 year	0.32 $\pm$ 0.51	1.19 $\pm$ 0.75	0.35 $\pm$ 0.58	0.0001
Bone loss after 5 years	1.28 $\pm$ 0.81	1.80 $\pm$ 0.75	1.20 $\pm$ 0.84	0.0001

retightened.

- The following complications occurred for patients in the internal hex group:
  - Two implants in the same patient were affected by peri-implantitis and failed 3 years after loading.
  - Screw loosening of the final crown 2 months after loading.
  - One implant had peri-implant mucositis at 10 months post-implantation, solved by a curettage and 0.2% chlorhexidine mouthwash.
  - One patient experienced screw loosening of the final crown 4 years after loading.
  - Two implants in the same patient were affected by mucositis 2 years after implantation, solved by non-surgical debridement.

Marginal bone level changes: at implant placement there was no statistically significant difference between the two different treatment groups ( $p=0.393$ ). Bone levels were  $0.03 \pm 0.06$  mm (95% CI -0.03; 0.09) for the conical group and  $0.02 \pm 0.05$  mm (95% CI -0.03; 0.07) for the internal hex group. One year after loading there was no statistically significant ( $p=0.824$ ) difference between the two groups for peri-implant bone levels,  $0.59 \pm 0.61$  mm (95% CI -0.02; 1.20) for the conical group and  $0.62 \pm 0.65$  mm (95% CI -0.03; 1.27) for the internal hex group, and bone loss  $0.56 \pm 0.53$  mm (95% CI 0.03; 1.09) for conical and  $0.60 \pm 0.62$  mm (95% CI 0.02; 1.22) for internal hex group (Table 2).

Five years after loading, patients in the conical group lost an average of  $1.41 \pm 0.94$  peri-implant bone vs.  $1.38 \pm 0.89$  mm for patients in the internal hex group with no significant differences between treatment group ( $p=0.745$ ).

Both treatment groups lost statistically significant marginal peri-implant bone at 5-year post-loading:  $P=0.0001$  for both conical and internal hex group.

By comparing the outcomes of the three different centers, no statistically significant differences can be observed for drop outs, failures or complications (Table 3). On the other hand, in the Cannata centre there was a significant superior bone loss, both at 1-year ( $+0.87$  mm, 95% CI 0.26: 1.48) and 5-years follow up.

In comparison to other centers ( $+0.56$  mm, 95% CI 0.21: 0.91) ( $p=0.0001$ ) (Table 3).

## Discussion

The main aim of this study has been to compare identical implants, with the same characteristics (implant material, surface characteristics and macro design) and different abutment connection interfaces: Conical vs. internal hex connection. In the previous study, carried out with data at 1 year after loading no statistically significant differences were noticed; the numbers of failures and complications were low and similar for both types. The same occur for data at 5 years post-loading.

In this case, the average values of bone loss were:

- 0.56 mm and 0.60 mm for conical and internal hex connection respectively, 1 year after loading,
- 1.41 mm and 1.38 mm for conical and internal hex connection respectively, 5 years after loading.

The bone loss is considerable at 5-year post-loading for the two types of connections, but the differences are not significant, hence, according to the findings of this study, clinicians can decide which type of connection to use according to their preferences. It is widely debated if implant-abutment connection designs can induce different degrees of crestal bone remodeling, after subjected to functional loading.

Only three other studies were found in PubMed, regarding the bone resorption for conical and internal hex connections:

- In a 5 years study, Szyszowski et al. compared implants all made of the same medical-grade titanium and all with the same SLA (Sandblasted and Acid-etched) surface, but with conical or internal hex connection, in order to evaluate the influence of the implant-abutment interface design on the Marginal Bone Loss (MBL). They observed a lower bone resorption in the conical connection respect to the internal hex group ( $0.68 \pm 0.59$  vs.  $0.99 \pm 0.89$  mm 1 year after loading, and  $0.96 \pm 1.02$  vs.  $1.30 \pm 1.15$  mm 5 years after loading). Both groups of implants ensure a 100% survival rate 16.

- In a randomized controlled clinical trial Pieri et al. compared the outcomes of single implants with conical and internal hex connection, immediately placed and restored in 40 patients.

One year after the loading, the difference of the average values of MBL between the two groups was 0.31 mm in favor of the conical connection [17].

- In a randomized controlled trial Corvino et al. compared the clinical and radiographical outcomes in terms of success and survival rate, primary and secondary stability, level of MBL for implants with the same micro- and macrotopography but with conical and internal hex connection, placed in a total of 33 patients. The values of MBL at 1 year after loading were  $0.48 \pm 0.18$  mm for the conical connection and  $0.57 \pm 0.24$  mm for the internal hex one. The conical connection gave better results than the internal hex one. No implants failed. MBL was found to be influenced by different individual and clinical factors [18].

The values of marginal bone loss obtained by Corvino et al. and Pieri et al. are in line with the values obtained in the first part of the present study with the same duration of 1 year of the follow-up, however, to date, there are no further published works comparing conical vs. internal hex connections for a period longer than one year, except the Szyszkowski et al., so we can't do a proper comparison.

The major limitations of this study were the small sample size and the fact that the outcome measurements, except for radiographic assessments, were done by operators aware of patient allocation and who treated the patients themselves. Both implant types were tested under real clinical conditions and the patient inclusion criteria were rather broad, therefore the results of the present trial can be generalized to patients having similar characteristics.

## Conclusion

No statistically or clinically significant differences were observed in outcomes 5 years after loading, between implants with conical and internal hex connection. Both treatment groups lost statistically significant marginal peri-implant bone at 5-year post-loading, hence clinicians can decide which type of connection to use according to their preferences.

## References

- Pessoa RS, Sousa RM, Pereira LM, Neves FD, Bezerra FJB, Jaecques SVN, et al. Bone remodeling around implants with external hexagon and morse-taper connections: A randomized, controlled, split-mouth, clinical trial. *Clin Implant Dent Relat Res.* 2017;19(1):97-110.
- Albrektsson T, Zarb G, Worthington P, Eriksson AR. The long-term efficacy of currently used dental implants: A review and proposed criteria of success. *Int J Oral Maxillofac Implants.* 1986;1(1):11-25.
- Liu Y, Wang J. Influences of microgap and micromotion of implant-abutment interface on marginal bone loss around implant neck. *Arch Oral Biol.* 2017;83:153-60.
- Callan DP, Cobb CM, Williams KB. DNA probe identification of bacteria colonizing internal surfaces of the implant-abutment interface: A preliminary study. *J Periodontol.* 2005;76(1):115-20.
- Capelli M. Surgical, biologic and implant-related factors affecting bone remodeling around implants. *Eur J Esthet Dent.* 2013;8(2):279-313.
- Oh TJ, Yoon J, Misch CE, Wang HL. The causes of early implant bone loss: Myth or science? *J Periodontol.* 2002;73(3):322-33.
- Duyck J, Rønold HJ, Van Oosterwyck H, Naert I, Vander Sloten J, Ellingsen JE. The influence of static and dynamic loading on marginal bone reactions around osseointegrated implants: An animal experimental study. *Clin Oral Implants Res.* 2001;12(3):207-18.
- Singla S, Rathee, M. Know your implant connections. *African J Oral Health.* 2017;6(2):1.
- Lin MI, Shen YW, Huang HL, Hsu JT, Fuh LJ. A retrospective study of implant-abutment connections on crestal bone level. *J Dent Res.* 2013;92(12 Suppl):202S-7S.
- Brånemark PI, Hansson BO, Adell R, Breine U, Lindström J, Hallén O, et al. Osseointegrated implants in the treatment of the edentulous jaw. Experience from a 10-year period. *Scand J Plast Reconstr Surg Suppl.* 1977;16:1-132.
- Khraisat A, Stegaroiu R, Nomura S, Miyakawa O. Fatigue resistance of two implant/abutment joint designs. *J Prosthet Dent.* 2002;88(6):604-10.
- Larrucea Verdugo C, Jaramillo Núñez G, Acevedo Avila A, Larrucea San Martín C. Microleakage of the prosthetic abutment/implant interface with internal and external connection: in vitro study. *Clin Oral Implants Res.* 2014;25(9):1078-83.
- Espósito M, Maghaireh H, Pistilli R, Grusovin MG, Lee ST, Trullenque-Eriksson A, et al. Dental implants with internal versus external connections: 5-year post-loading results from a pragmatic multicenter randomised controlled trial. *Eur J Oral Implantol.* 2016;9(Suppl 1):129-41.
- Pessoa RS, Sousa RM, Pereira LM, Neves FD, Bezerra FJ, Jaecques SV, et al. Bone remodeling around implants with external hexagon and Morse-taper connections: A randomized, controlled, split-mouth, clinical trial. *Clin Implant Dent Relat Res.* 2017;19(1):97-110.
- Cannata M, Grandi T, Samarani R, Svezia L, Grandi G. A comparison of two implants with conical vs. internal hex connections: 1-year post-loading results from a multicentre, randomised controlled trial. *Eur J Oral Implantol.* 2017;10(2):161-8.
- Szyszkowski A, Kozakiewicz M. Effect of implant-abutment connection type on bone around dental implants in long-term observation: Internal cone versus internal hex. *Implant Dent.* 2019;28(5):430-36.
- Pieri F, Aldini NN, Marchetti C, Corinaldesi G. Influence of implant-abutment interface design on bone and soft tissue levels around immediately placed and restored single-tooth implants: A randomized controlled clinical trial. *Int J Oral Maxillofac Implants.* 2011;26(1):169-78.
- Corvino E, Pesce P, Camodeca F, Moses O, Iannello G, Canullo L. Clinical and radiological outcomes of implants with two different connection configurations: A randomised controlled trial. *Int J Oral Implantol (Berl).* 2020;13(4):355-68.