



Improved Angina Symptoms Following Coronary Sinus Flow Reducer Implantation in a Patient with Refractory Angina and Chronic Total Occlusion: A Case Report

Crt Langel¹, Mrak Miha², Nejc Pavsic² and Matjaz Bunc^{2*}

¹Department of Radiology, University Medical Centre Ljubljana, Slovenia

²Department of Cardiology, University Medical Centre Ljubljana, Slovenia

Abstract

Due to ageing population and increased survival of the patients with coronary artery disease there is an increasing number of patients with debilitating angina refractory to optimal medical treatment who are not candidates for revascularization. Even more, up to 30% of patients have symptoms of angina 1 year after revascularization, some with no additional revascularization options. In case of low ischemic load, the treatment of stable refractory angina is aimed at symptom reduction. There are several new treatment methods targeting myocardial ischemia available. We report a case of a patient with unsuccessful PCI of RCA CTO suffering from refractory angina successfully treated with Coronary sinus Flow Reducer (CFR).

Keywords: Chest pain; Refractory angina pectoris; Myocardial ischemia; Coronary sinus flow reducer; Chronic total occlusion

Introduction

Advancements in drug and device therapy, along with ageing population, have increased the life expectancy of the patients with Coronary Artery Disease (CAD) [1]. This has also resulted in the increased prevalence of those CAD patients who have chronic angina pectoris refractory to medical treatment and who are ineligible for further surgical or percutaneous revascularization [2,3]. Patients with reversible ischemia-related angina lasting ≥ 3 months despite optimal medical therapy and revascularization options exhausted are said to have Refractory Angina (RA). This group of patients comprises an estimated 5% to 10% of all diagnosed angina cases. They often use several anti-ischemic drugs, experience a poor quality of life due to deleterious symptoms and are frequently hospitalized [3].

Coronary Sinus Flow Reducer (CFR) stent is an implantable device aimed at reducing angina pectoris symptoms by decreasing the cross-section of the Coronary Sinus (CS) and increasing venous backpressure. This in effect redirects blood flow to subendocardium, increases collateral blood flow and, presumably, induces neogenesis [4,5].

Combined, these mechanisms increase perfusion of the more ischemic regions of the myocardium, resulting in alleviation of angina symptoms, improved myocardial contraction and reduced left ventricular end-diastolic pressure [6]. CFR is a stainless steel balloon-expandable hourglass-shaped stent inserted into the CS *via* transjugular approach. It is a percutaneous analogue of surgical partial ligation of the CS that was first performed by Beck and Leighninger in 1954 and was- despite significantly improving angina symptoms and reducing 5-year mortality rate- later discontinued in part due to widespread acceptance of the Coronary Artery Bypass Graft (CABG) surgery [7].

Studies of CFR so far have demonstrated the device and its implantation procedure to be feasible, safe and efficacious. The Coronary Sinus Reducer for treatment of Angina (COSIRA) multicentre, prospective, double-blind, sham-controlled study showed significantly higher percentage of patients with Canadian Cardiovascular Society (CCS) classification improvement of at least one functional class in the treatment group in comparison to the sham-controlled group (71% and 42%, respectively) [8]. Two smaller studies also demonstrated significant improvements of objective myocardial ischemia measures, such as exercise time or the mean change in wall-motion index assessed by dobutamine echocardiography [9,10]. Our heart centre has been employing CFR in RA

OPEN ACCESS

*Correspondence:

Matjaz Bunc, Department of
Cardiology, University Medical Center
Ljubljana, Zaloška c. 007, 1000
Ljubljana, Slovenia,

E-mail: mbuncec@yahoo.com

Received Date: 08 Jul 2019

Accepted Date: 12 Aug 2019

Published Date: 20 Aug 2019

Citation:

Langel C, Miha M, Pavsic N, Bunc
M. Improved Angina Symptoms
Following Coronary Sinus Flow
Reducer Implantation in a Patient with
Refractory Angina and Chronic Total
Occlusion: A Case Report. *Clin Surg*.
2019; 4: 2550.

Copyright © 2019 Matjaz Bunc. This
is an open access article distributed
under the Creative Commons
Attribution License, which permits
unrestricted use, distribution, and
reproduction in any medium, provided
the original work is properly cited.

treatment since 2016 with overall results so far closely matching the COSIRA trial outcomes.

Case Presentation

An 80-year-old man with a history of hypertension, dyslipidemia, type 2 diabetes treated with oral anti hyperglycemic therapy, benign prostatic hyperplasia, peripheral arterial disease, a trial fibrillation, non-ST-elevation myocardial infarction, CABG using Left Internal Mammary Artery (LIMA) grafted to Left Anterior Descending coronary artery (LAD) and venous graft grafted to Obtuse Marginal 1 (OM 1), and aortic valve replacement using bio prosthetic valve presented to our clinic with CCS class IV angina despite optimal medical therapy (acetylsalicylic acid 100 mg, nebivolol 5 mg twice daily, ramipril 5 mg twice daily). Cardiac echography showed impaired left ventricular systolic function with EF of 48% to 50%, with basal, inferior, inferior septal and inferior lateral wall motion abnormalities. Aortic bioprosthetic valve showed normal function.

Coronary angiography showed 2-vessel coronary artery disease with RCA Chronic Total Occlusion (CTO) with left to right Rantop 2 collateral flow and an important stenosis of proximal LAD. Surgical revascularization was our first option. After patient refused surgery we performed proximal LAD stenting with DES (Synergy 3.0 mm × 12 mm). PCI CTO with different approaches (antegrade, retrograde) was not successful. Finally, dissection of the mid RCA occurred during PCI attempts. Due to RA persisting 3 months after PCI despite optimal medical therapy (bisoprolol 5 mg, perindopril 10 mg, ranolazine 2 mg × 500 mg, rosuvastatin 30 mg) multi-disciplinary heart team decided that CFR implantation was the optimal treatment approach for this patient.

Ultrasound-guided right internal jugular vein puncture was performed, followed by multipurpose catheter insertion and coronary sinus ostium cannulation using fluoroscopic guidance. A 9 French guiding catheter with the CFR stent (Neovasc Inc., Richmond B.C., Canada) was placed inside the coronary sinus at the appropriate insertion point, i.e. at least 2 cm distal to the ostium to exclude small cardiac veins draining the Right Coronary Artery (RCA) venous return, all the while excluding the larger, more distal side branches draining Left Coronary Artery (LCA) venous return (Figure 1). The catheter-mounted hourglass-shaped balloon was inflated at 5 atm for 30 seconds, expanding the reducer stent into its functional shape (Figure 2). The recommended 10% to 20% device over sizing relative to the coronary sinus cross section was achieved in order to ensure proper anchoring, prevent device migration and induce endothelialization of the stent's mesh structure. After balloon deflation and the removal of the catheter, venography showed successful reducer stent position and anchoring. Complications such as stent occlusion, coronary sinus dissection or perforation, or bleeding at the jugular puncture site were excluded. The patient received dual antiplatelet therapy comprising acetylsalicylic acid and clopidogrel for the duration of 6 months.

At 6-month follow-up, the patient showed marked reduction of the angina symptoms, with CCS grade improving by three classes (from IV to I). The reduction of angina symptoms started 6-7 weeks after implantation. The positive effects lasting more than 10 months and is sustained.

Discussion

Increased life expectancy of patients with CAD, to some extent

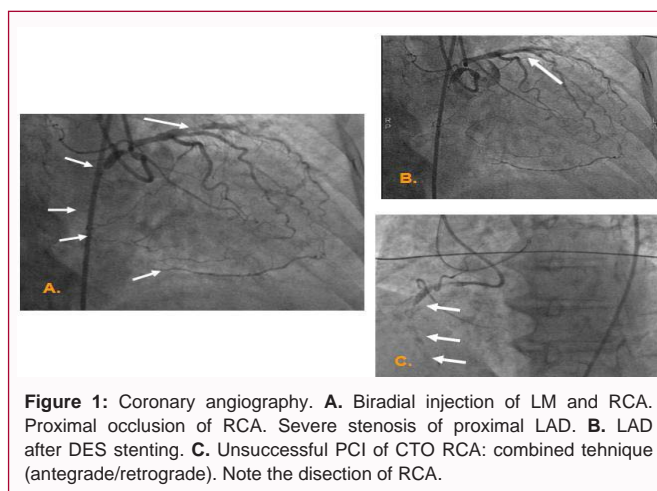


Figure 1: Coronary angiography. **A.** Biradial injection of LM and RCA. Proximal occlusion of RCA. Severe stenosis of proximal LAD. **B.** LAD after DES stenting. **C.** Unsuccessful PCI of CTO RCA: combined technique (antegrade/retrograde). Note the dissection of RCA.

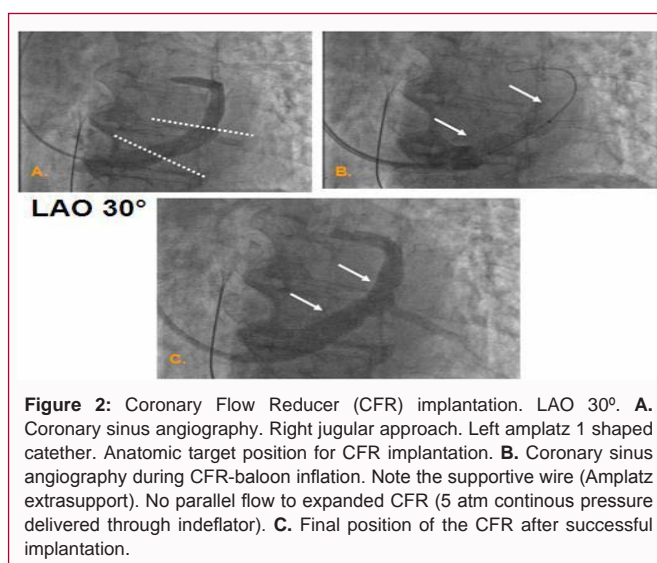


Figure 2: Coronary Flow Reducer (CFR) implantation. LAO 30°. **A.** Coronary sinus angiography. Right jugular approach. Left Amplatz 1 shaped catheter. Anatomic target position for CFR implantation. **B.** Coronary sinus angiography during CFR-balloon inflation. Note the supportive wire (Amplatz extrasupport). No parallel flow to expanded CFR (5 atm continuous pressure delivered through inflator). **C.** Final position of the CFR after successful implantation.

due to advancements in drug and device therapy and in part due to ageing population in general, have increased the number of patient is with RA. Despite having a long-term mortality of under 4% per year, approaching that of the patients with chronic stable angina (1.5%), the incapacitating nature of angina has a significant negative effect on quality of life in patients with RA [3,10]. Up to 30% of stable CAD still experience angina symptoms 1 year after revascularization [11]. Data derived from cardiac cath-lab registries showed that 6% to 12% of the patients referred to angiography with evidence of ischemia were ineligible for traditional revascularization [12].

Several methods have been under investigation to mitigate the symptoms of RA. First-line treatment options include beta-blockers, ivabradine, calcium channel blockers, nitrates, ATP-sensitive potassium channel openers, late sodium current inhibitors and rho-kinase inhibitors [13]. According to Diamond recommendations patients should be treated with a combination of event prevention and angina relief medical therapy [14]. Approximately 10% of RA patients receiving one or more of the medical treatment choices remain symptomatic [15].

There are some additional treatment options of RA, including external enhanced counter pulsation, extracorporeal shockwave therapy, spinal cord stimulation, internal mammary artery implants, transmyocardial laser revascularization, cell therapy and gene

therapy. None of these approaches, however, have yet become widely used [16]. Lately, the CFR implantation has shown promising results in alleviating angina symptoms and improving quality of life. 70% to 80% of patients experience improvement in CCS class, while according to the COSIRA data there is also up to 30% of placebo effect in angina symptoms' improvement [17]. Since RA treatment is aimed at symptom reduction, its goal is achieved even in the placebo population.

There is a non-response cohort of patients up to 20% to 30%, with no definite explanation for this clinical fact. Some possible mechanisms may be: ischemia arising from the territory of RCA, symptoms caused by heart failure rather than ischemia, non-ischemic chest pain, the presence of an alternative drainage venous system of the myocardium into the right ventricle (the Thebesian venous system), and incomplete endothelialization of the stent with inadequate pressure gradient across the device [18]. Some of the proposed mechanisms need further clinical evaluation. It has already been shown that peri-procedural measurement of the differential pressure between right atrial pressure before implantation and coronary sinus systolic pressure during balloon occlusion might be able to identify the non-responder population; the patients who achieve a high peri-procedural differential pressure are more prone to have a high post-implantation, post-endothelialization pressure gradient across the device and thus a higher probability of good response regarding angina symptoms [19].

CFR implantation is a safe procedure; with only one coronary sinus perforation reported so far [20]. In our case report we present a successful CFR implantation with good clinical reduction of angina. At this point we cannot prove any mechanism of the improvements. Nevertheless, the clinical dynamic ensued according to previous clinical data, i.e. the angina improvement appeared 6-7 weeks after CFR implantation. This is the expected time period necessary for CFR mesh endothelialization, the latter being the critical point for hemodynamic effects resulting in venous backpressure build-up to take place.

So far we have experience with 5 CFR implantations in CTO RCA patients. Reduction of RA in this population seems to be lower than in the overall CFR population, the etiological reasoning being that CFR might not be as effective in the cases of large ischemic area. Additional clinical data is required to support our hypothesis.

There is an ongoing discussion concerning the possibility of using CFR in patients with chronic angina who are candidates for percutaneous revascularization of left coronary arteries' CTOs (i.e. a certain subgroup of non-RA patients). There are data from our CTO registry confirming the clinical efficacy of successful PCI of LAD, RCA, LCX in reducing RA in 6-year follow-up (55%, 35%, less than 5%, respectively) [21]. However, in the light of the recent CTO studies' conflicting results, there is still a debate regarding the clinical efficacy of CTO interventions at improving angina frequency, physical limitation and quality of life [22,23]. In addition, CTO revascularizations do not offer prognostic benefits but rather aim at improving angina symptoms, which is exactly what the Reducer has already proven to achieve. Furthermore, while CTO revascularization is a technically challenging and often time-consuming, CFR implantation is a relatively simpler and usually shorter (~30 min to 45 min) procedure [24].

Conclusion

Optimal medical therapy is the initial treatment approach to stable CAD. In case of proven ischemia exceeding 10% of the myocardium revascularization options should be performed [25]. However, patients with angina refractory to optimal medical treatment and with revascularization options exhausted make up a substantial portion of all patients with CAD and their number is expected to increase in the years to come. CFR implantation has proved to be an effective and safe RA treatment method. Both wider acceptance of this novel technique into regular clinical practice and broadening of the patient population-those with angina due to CTO being the prime possible candidates-are expected in the near future. We have shown a case of a patient with a remarkable CCS class improvement of angina symptoms, demonstrating the CFR's potential to have a transformative impact on formerly no-option patients' lives. Further clinical studies are required to evaluate CFR implantation as a complementary treatment strategy in addition to optimal medical therapy and/or revascularization.

References

- Banai S, Ben Muvhar S, Parikh KH, Medina A, Sievert H, Seth A, et al. Coronary sinus reducer stent for the treatment of chronic refractory angina pectoris: a prospective, open-label, multicenter, safety feasibility first-in-man study. *J Am Coll Cardiol*. 2007;49(17):1783-9.
- Mannheimer C, Camici P, Chester MR, Collins A, DeJongste M, Eliasson T, et al. The problem of chronic refractory angina; report from the ESC Joint Study Group on the Treatment of Refractory Angina. *Eur Heart J*. 2002;23(5):355-70.
- Williams B, Menon M, Satran D, Hayward D, Hodges JS, Burke MN, et al. Patients with coronary artery disease not amenable to traditional revascularization: prevalence and 3-year mortality. *Catheter Cardiovasc Interv*. 2010;75(6):886-91.
- Giannini F, Aurelio A, Jabbour RJ, Ferri L, Colombo A, Latib A. The coronary sinus reducer: clinical evidence and technical aspects. *Expert Rev Cardiovasc Ther*. 2017;15(1):47-58.
- Weigel G, Kajgana I, Bergmeister H, Riedl G, Glogar HD, Gyöngyösi M, et al. Beck and back: a paradigm change in coronary sinus interventions-pulsatile stretch on intact coronary venous endothelium. *J Thorac Cardiovasc Surg*. 2007;133(6):1581-7.
- Königstein M, Verheye S, Jolicœur EM, Banai S. Narrowing of the coronary sinus: a device-based therapy for persistent angina pectoris. *Cardiol Rev*. 2016;24(5):238-43.
- Beck CS, Leightner DS. Operations for coronary artery disease. *J Am Med Assoc*. 1954;156(13):1226-33.
- Verheye S, Jolicœur EM, Pettersson T, Sainsbury P, Hill J, Vrolix M, et al. Efficacy of a device to narrow the coronary sinus in refractory angina. *N Engl J Med*. 2015;372(6):519-27.
- Königstein M, Meyten N, Verheye S, Schwartz M, Banai S. Transcatheter treatment for refractory angina with the coronary sinus reducer. *Euro Intervention*. 2014;9(10):1158-64.
- Henry TD, Satran D, Hodges JS, Johnson RK, Poulouse AK, Campbell AR, et al. Long-term survival in patients with refractory angina. *Eur Heart J*. 2013;34(34):2683-8.
- Abdallah MS, Wang K, Magnuson EA, Osnabrugge RL, Kappetein AP, Morice MC, et al. Quality of life after surgery or DES in patients with 3-vessel or left main disease. *J Am Coll Cardiol*. 2017;69(16):2039-50.
- Bernstein S, Brorsson B, Aberg T, Emanuelsson H, Brook R, Werko L. Appropriateness of referral of coronary angiography patients in Sweden. *Heart*. 1999;81(5):470-7.

13. Grandjean T, Haefliger D, Arroyo D, Cook S. Coronary sinus reduction for the treatment of refractory angina: a novel tool for the treatment of angina pectoris resistant to optimal conventional therapy. *Cardiovasc Med*. 2018;21(6):170-3.
14. Ferrari R, Camici PG, Crea F, Danchin N, Fox K, Maggioni AP, et al. Expert consensus document: A 'diamond' approach to personalized treatment of angina. *Nat Rev Cardiol*. 2018;15(2):120-32.
- 15.
16. McGillion M, Arthur HM, Cook A, Carroll SL, Victor JC, L'allier PL, et al. Management of patients with refractory angina: Canadian Cardiovascular Society/Canadian Pain Society joint guidelines. *Can J Cardiol*. 2012;28(2):S20-S41.
17. Abawi M, Nijhoff F, Stella PR, Voskuil M, Benedetto D, Doevendans PA, et al. Safety and efficacy of a device to narrow the coronary sinus for the treatment of refractory angina: a single-centre real-world experience. *Neth Heart J*. 2016;24(9):544-51.
18. Verheye S, Jolicœur EM, Behan MW, Pettersson T, Sainsbury P, Hill J, et al. Efficacy of a device to narrow the coronary sinus in refractory angina. *N Engl J Med*. 2015;372:519-27.
19. Konigstein M, Giannini F, Banai S. The Reducer device in patients with angina pectoris: mechanisms, indications, and perspectives. *Eur Heart J*. 2018;39(11):925-33.
20. Baldetti L, Colombo A, Banai S, Latib A, Esposito A, Palmisano A, et al. Coronary sinus Reducer non-responders: insights and perspectives. *Euro Intervention*. 2018;13(14):1667-9.
21. Cortese B, Di Palma G, Latini R. Coronary sinus perforation during reducer implantation. *Catheter Cardiovasc Interv*. 2018;91(7):1291-3.
22. Kranjec I, Zavrl D, Zananovic D, Mrak M, Bunc M. Robustness of percutaneously completed coronary revascularization in stable coronary artery disease: Obstructive versus occlusive lesions. *Angiology*. 2019;70(1):78-86.
23. Park SJ. Drug-eluting stent versus optimal medical therapy in patients with coronary chronic total occlusion: DECISION CTO randomized trial. American College of Cardiology Annual Scientific Session. 2017.
24. Werner GS, Martin-Yuste V, Hildick-Smith D, Boudou N, Sianos G, Gelev V, et al. A randomized multicentre trial to evaluate the utilization of revascularization or optimal medical therapy for the treatment of chronic total coronary occlusions. *Eur Heart J*. 2018;39(26):2484-93.
25. Cheng K, de Silva R. New advances in the management of refractory angina pectoris. *Eur Cardiol*. 2018;13(1):70-9.
26. Neumann FJ, Sousa-Uva M, Ahlsson A, Alfonso F, Banning AP, Benedetto U, et al. 2018 ESC/EACTS Guidelines on myocardial revascularization. *Eur Heart J*. 2019;40(2):87-165.