



The Intraoperative Findings and Clinical Experience of Direct Inguinal Hernia Descending into the Scrotum

Lisheng Wu^{1*}, Junsheng Li², Jianwei Yu¹ and Ran Miao¹

¹Department of Hernia and Metabolic Surgery, The First Affiliated Hospital, University of Science and Technology, China

²Department of General Surgery, Affiliated Zhongda Hospital, Southeast University, China

Abstract

Background: Direct inguinal hernias rarely descend into the scrotum. We reported ten cases of direct inguinal hernias descending into the scrotums during inguinal hernia repair procedures.

Methods: We reported a series of 10 cases of direct inguinal hernias which descending into the scrotums. 8 of the 10 cases were bilateral direct hernias, and 4 of the 10 cases were recurrent direct hernias. The direct-scrotal hernias were found in right side in 6 cases and left sides in 4 cases. The successful laparoscopic inguinal hernia repairs were performed in 6 these cases, and open repairs in 4 cases. And we presented the operative findings of the repair technique, illustrated the mechanism of direct hernia into scrotum, in addition, we also provided our skills and pitfalls in treating the hernias in this situation.

Results: The both laparoscopic and open approaches were successfully performed in all cases, recurrent direct-scrotal hernias resulted heavy adhesion and made dissection difficult, the direct hernia sacs had a close contact with the vas deference by disrupting the transversalis fascia. Closing the large direct orifice prior to placement was a useful method to prevent recurrence.

Conclusion: The extreme attenuation or disruption of the transversalis attribute to the occurrence of direct-scrotal hernias, therefore, the cord structures were exposed to the direct hernia defect and should be avoided during dissection and hernia repair. Closing of the transversalis fascia around the defect cavity prior to mesh placement is a reliable method to prevent hernia recurrence in this situation.

OPEN ACCESS

*Correspondence:

Lisheng Wu, Department of Hernia and Metabolic Surgery, The First Affiliated Hospital, University of Science and Technology, Hefei 230001, China, E-mail: wlsheng1210@163.com

Received Date: 02 Jul 2019

Accepted Date: 30 Jul 2019

Published Date: 02 Aug 2019

Citation:

Wu L, Li J, Yu J, Miao R. The Intraoperative Findings and Clinical Experience of Direct Inguinal Hernia Descending into the Scrotum. *Clin Surg.* 2019; 4: 2535.

Copyright © 2019 Lisheng Wu. This is an open access article distributed under the Creative Commons Attribution License, which permits unrestricted use, distribution, and reproduction in any medium, provided the original work is properly cited.

Keywords: Direct inguinal hernia; Spermatic cord; Scrotum; TAPP; TEP

Introduction

Inguinal hernia is one of the most frequently performed operations in general surgery. It is well known that the enlarged indirect inguinal hernia would eventually descend into the ipsilateral scrotum. The direct inguinal hernia protrude directly against the weakened transversalis fascia, therefore, the direct inguinal hernia was usually regarded extremely rarely descending into the scrotum. During our clinical practice in the past four years, we have encountered ten cases of direct inguinal hernias which descended into the scrotum, and all of them were preoperatively diagnosed as indirect inguinal hernias. Interestingly, 8 the ten cases were bilateral direct inguinal hernias, and four of the ten cases were recurrent hernias, which highlighted the mechanism of collagen metabolic disturbance of this entity. We therefore reported the unusual clinical findings in this report, as well as the technical aspects regarding the treatment of large recurrent direct hernias, especially the technique modifications regarding laparoscopic direct-scrotal hernia repair.

Materials and Methods

Patients' information

Under the approval of the Institutional Review Board of the First Affiliated Hospital of University of Science and Technology of China (approval number: 2019-P-003), ten patients between 2014 and 2018 at 2 institutions (the First Affiliated Hospital of University of Science and Technology of China and Zhongda Hospital Southeast University) were retrospectively reviewed. Written informed consent was waived by the IRB. Eight of the ten cases were bilateral direct hernias, and four of the ten cases were recurrent direct hernias. Even in bilateral hernias, only one side of hernia descended into the scrotum at the time of presentation. The direct-scrotal hernias were found in right side in

Table 1: Basic information of the cases.

Case number	Gender	Age(year)	Hernia type	Hernia side	Side in scrotum	History (year)	Repair procedure	Follow-up
1	M	62	Primary	Bilateral	L	11	TEP	9 months
2	M	55	Recurrent	Bilateral	R	2 years after repair	TAPP	19 months
3	M	71	Recurrent	Bilateral	R	5 years after repair	TAPP	19 months
4	M	64	Recurrent	bilateral	L	10 years after repair	TAPP	7 months
5	M	78	Primary	bilateral	R	20 years	TEP	4 months
6	M	71	Primary	Bilateral	L	6 years	TAPP	4 months
7	M	52	recurrent	bilateral	R	3 years	Open preperitoneal	4 years
8	M	67	Primary	Bilateral	R	21 years	Open preperitoneal	4 years
9	M	76	Primary	Unilateral	L	4 years	Open preperitoneal	4 years
10	M	79	Primary	Unilateral	R	6 months	Lichtenstein	2years

6 cases and left sides in 4 cases. The successful laparoscopic inguinal hernia repairs were performed in 6 these cases, and open repairs was carried out in 4 cases.

The basic information of the ten cases was summarized in Table 1, Total Extra Peritoneal Repair (TEP) was performed in 2 cases, and 4 cases were repaired by the Transabdominal Preperitoneal Repair (TAPP). Open preperitoneal repair (modified Kugel[®]) was done in 3 cases. One case was repair with Lichtenstein procedure. The typical intra-operative finding and technique skills were presented in Table 1.

Results

Intraoperative findings

Case No. 4 was a 64 years old male, he was admitted to us with left side inguinal scrotal hernia, on examination, the left inguinal hernia mass measured 10 cm × 15 cm, which descended into the left scrotum, and could be manually reduced without difficulty (Figure 1). His past medical history included two times of hernia repair on the left side and one time repair on the right. In detail, first time repair was undertaken on the left side inguinal hernia 15 years ago with a conventional open procedure. Second time, bilateral inguinal hernia repair (TAPP) was carried out 10 years ago. And only one month after the TAPP operation, he found the swelling appeared again in the left side inguinal area, and the size of the swelling gradually increased within the past four years and eventually descended into the left scrotum. There was no history of abdominal pain, vomiting and fever. Thus, the patient was diagnosed with left side recurrent inguinal hernias, presumably indirect inguinal hernia, and the patient proceeded to an elective laparoscopic Tran's abdominal preperitoneal repair.

Intraoperative findings and repair technique

During the TAPP procedure, after the establishment of the pneumoperitoneum, a large defect measuring 4 cm was found in the left side inguinal region, and the defect was evidently medially sided and near the left medial ligament. The epigastric artery was not visible due to the previously preperitoneal mesh repair (Figure 2). Thus, the diagnosis of recurrent direct scrotal hernia was established.

The repair was completed by TAPP. Although the previous repair method was TAPP, the peritoneum dissection was successfully done was without difficulty, due to the fact that the majority of the previous mesh have slid into the direct hernia defect cavity, with only a small portion of the upper border of the mesh visible, and this is obviously

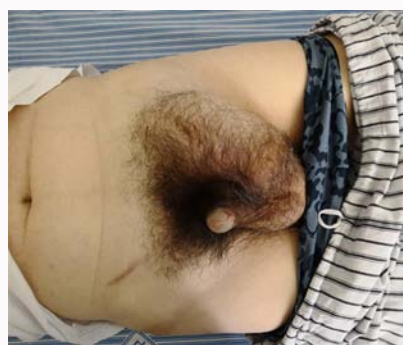

Figure 1: The left recurrent inguinal hernia descended into the scrotum.

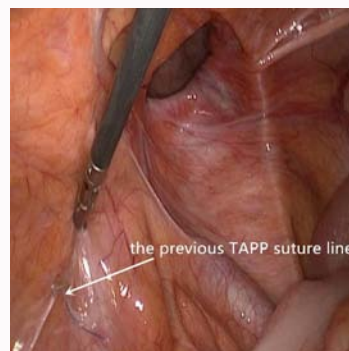


Figure 2: The left direct inguinal hernia defect and the previous TAPP suture line.

the cause of hernia recurrence (Figure 3). After complete reduction of the direct hernia sac, the spermatic cord and vas deference were exposed into the dissection field, indicating the complete disruption of the transversalis, which usually separates the spermatic cord and direct sac, and specially attention should be paid during the recurrent hernia dissection (Figure 3).

To prevent the mesh sliding into the direct hernia cavity following repair, the attenuated transversalis fascia border and adjacent tissue around the direct hernia defect was closed with 3-0 barbed suture (V-Loc[™] 180, Covidien[™], USA). The first suture was secured on the mesh (Figure 4), and special attention should be paid to spare the vas deference when putting the suture (Figure 5), which was covered by the flimsy transversalis fascia or even exposed. The deep apex of transversalis fascia was pulled out into the preperitoneal space and sutured together, thus, the direct hernia defect and the cavity was

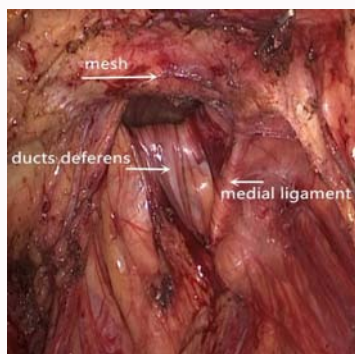


Figure 3: The vas deference was seen following the defect into the scrotum.

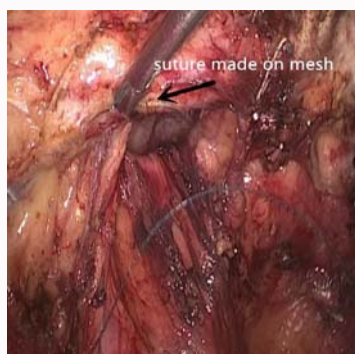

Figure 4: The first suture was made in the mesh.

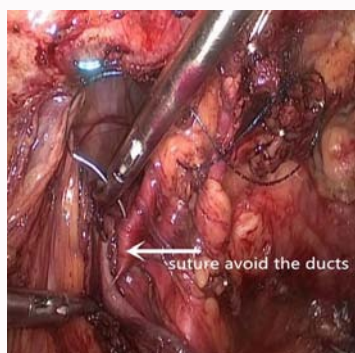


Figure 5: The closing suture was made not to involve the vas deference.

completely eradicated (Figure 6). Then, the mesh was placed, and the peritoneum was closed with suture.

In our ten series, 4 cases were repair with open technique, among them, three cases were treated with open preperitoneal (Modified Kugel) and one case was treated with Lichtenstein approach. The detailed information and outcomes of the ten cases were presented in Table 1. All the ten cases with direct inguinal hernias descending into the scrotum were successfully, there were no perioperative complications and no hernia recurrence during the following-up (4 years, 4 months).

Discussion

Hernia sac descending into scrotum was often used as a criterion to differentiate direct and indirect inguinal hernia clinically. However, the long-standing and multiple recurrent direct inguinal hernias may destroy or distort the adjacent anatomical structures, especially the

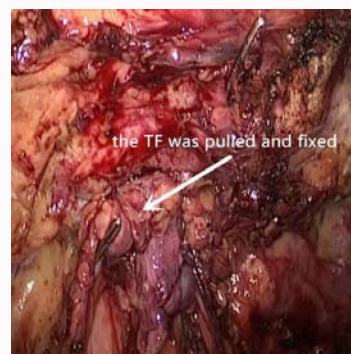

Figure 6: The direct hernia defect cavity was completely closed.

transversalis fascia, and lead to the formation of “direct-scrotal” hernias. Anatomically, the indirect inguinal hernia could easily descend into the scrotum along with the spermatic cord through two openings of the inguinal canal: the internal ring bordered with the transversalis fascia and the external ring bordered by the external oblique aponeurosis. However, the direct hernia does not have the natural and straightforward pathway into the scrotum. Furthermore, the transversalis fascia was believed to be an important structure to prevent the occurrence of inguinal hernia. Stoppa suggested that “A groin hernia is a defect in the transversus abdominis”, and he also added that the only layer of resistance in this area was the fascia transversalis [1,2]. This is extremely true in the situation of direct inguinal hernia, since the main manifestation of direct hernia occurrence is attenuation and protrusion of the transversalis fascia, as illustrated in the present case (Figure 3). It has been postulated that the mechanism of direct inguinal hernia has a strong relation with collagen metabolism.

Experiments have shown that there is a concomitant decrease of TIMP-2 in the transversalis fascia of patients with direct inguinal hernia, which supports the different pathogenetic mechanisms between direct and indirect inguinal hernias [3].

Interestingly, the 8 cases (80%) in our series all had the history of bilateral direct inguinal hernias, which supported the systematic metabolic collagen-mechanism of “direct-scrotal” hernia formation, and it is conceivable that, the long-standing direct inguinal hernia, combined with the disruption of local tissue structures resulted from multiple recurrences, would eventually extend the transversalis fascia, and descend into the ipsilateral scrotum. Furthermore, the disturbances in collagen metabolism are also strongly associated with high hernia recurrence rates, supporting the hypothesis that hernia recurrence also represents a disease of the extracellular matrix, these factors, taken together; contribute to the reoperations to 8% to 17% of all inguinal hernia repairs [4-6].

Thus, in the situation of long-standing or recurrent direct hernia, the transversalis fascia was extremely extended or disrupted to disappear, in addition, the external ring of the external oblique aponeurosis may also disrupt. In this situation, the direct hernia contents could descend into the scrotum through the vanished transversalis and the external ring.

And these anatomical features are clinically important in several aspects. First, the direct hernia sac is exposed directly to the spermatic cord structure, and may be firmly adhered to it; therefore, special attention should be paid not to injure the vas deference during difficult dissection. Second, to prevent mesh sliding into the hernia

defect, especially in laparoscopic procedures, narrowing or closing the hernia defect is desirable maneuver prior to mesh placement [7]. Third, when suturing or narrowing the defect on the transversalis fascia, special attention should be paid not to trap the vas deference, since the covering transversalis fascia was vanished (Figure 5). Fourth, direct-scrotal hernias are more prone to be recurrent hernias (40% of our cases) and bilateral hernias (80% of our cases).

Conclusion

Our findings indicated that, although rare, a long-standing or recurrent direct hernia may go into the scrotum, the extremely attenuation or disruption of the transversalis fascia is critical mechanism attributing this to happen. The cord structures may direct adhere to the hernia sac, and attention should be paid during dissection. Closing of the direct hernia defect cavity is an effective method to prevent direct hernia recurrence.

References

1. Condon RE. Surgical anatomy of the transversus abdominis and transversalis fascia. *Ann Surg.* 1971;173(1):1-5.
2. Stoppa R. Hernia of the Abdominal Wall. In: Chevrel JP, ed. *Surgery of the Abdominal Wall.* Berlin, Heidelberg: Springer Berlin Heidelberg; 1987:155-224.
3. Abci I, Bilgi S, Altan A. Role of TIMP-2 in fascia transversalis on development of inguinal hernias. *J Invest Surg.* 2005;18(3):123-8.
4. Kingsnorth A. The management of incisional hernia. *Ann R Coll Surg Engl.* 2006;88(3):252-60.
5. Aufenacker TJ, de Lange DH, Burg MD, Kuiken BW, Hensen EF, Schoots IG, et al. Hernia surgery changes in the Amsterdam region 1994-2001: decrease in operations for recurrent hernia. *Hernia.* 2005;9(1):46-50.
6. Bay-Nielsen M, Kehlet H, Strand L, Malmstrom J, Andersen FH, Wara P, et al. Quality assessment of 26,304 herniorrhaphies in Denmark: a prospective nationwide study. *Lancet.* 2001;358(9288):1124-8.
7. Li J, Zhang W. Closure of a direct inguinal hernia defect in laparoscopic repair with barbed suture: a simple method to prevent seroma formation? *Surg Endosc.* 2018;32(2):1082-6.