



Autogenous Fibula Graft for Periprosthetic Femoral Fractures after Revision Total Hip or Knee Arthroplasty

Yoshio Kumagae and Takaaki Tanaka*

Department of Orthopaedic Surgery, NHO Utsunomiya National Hospital, Japan

Abstract

Periprosthetic femoral fractures after total hip and knee arthroplasty are increasing common complications. With stable prosthesis classified Vancouver type B1, surgical stabilization of the fracture with plate, strut allograft, or a combination of both is recommended. However, allografts have not commonly been used in Japan. In addition, bone formation and stabilization in the fractured site are not easily obtained after revision THA and TKA using long stem. Thus, we used autogenous fibula graft and plate in the treatment of periprosthetic femoral fractures after three revisions THA and one revision TKA. In addition, to reduce donor-site morbidity, Beta-Tricalcium Phosphate (TCP) blocks were placed on the periosteum. The results showed that bone union of femoral fractures was obtained in all patients, and partial reconstruction of fibula was obtained but no complain on donor-site and tibio-fibular joints.

In conclusion, a combination of autogenous fibula graft and plate fixation is a useful technique to treat periprosthetic femoral fractures after primary and revision THA or TKA. In addition, reconstruction of fibula using beta-TCP reduced donor-site morbidity.

Keywords: Periprosthetic femoral fracture; Revision arthroplasty; Autogenous fibula graft; Beta-tricalcium phosphate

Introduction

Periprosthetic fractures of the femur in association with total hip and knee arthroplasty are increasingly common and often difficult to treat [1-3]. Patients with periprosthetic fractures are mostly elderly and have osteoporosis. In addition, after revision hip and knee arthroplasty are more difficult due to poor periosteal blood supply. In the case of a stable prosthesis, surgical stabilization of the fracture with plate, strut allograft, or a combination of both was recommended [4-8]. However, allografts have commonly been used as substitutes for autogenous bone grafts in Europe and United States but not in Japan. In this study, we report the results of periprosthetic femoral fractures after revision THA and TKA using autogenous fibular graft and plate, and also show reconstruction of fibula using beta-TCP.

Materials and Methods

Three patients with periprosthetic femoral fractures after revision THA classified Vancouver type B1 and one patient after revision TKA were enrolled in this study. They were all female and the mean age at the time of surgery was 80 (74 to 89) years. All femoral fractures were reduced and fixed using plate and autogenous fibula graft (12 cm to 14 cm). Beta-TCP blocks with 75% porosity were placed on the periosteum of the fibula. The follow-up period ranged from 1 to 6 years.

Results

Bone union was obtained from all 4 periprosthetic femoral fractures after revision THA or TKA. Bone formation and beta-TCP resorption were found in the bone defects of fibula. Although beta-TCP resorption was completed, bone reconstruction of fibula was incomplete. All patients did not complain pain on donor-site and tibio-fibular joints.

Case Presentation

Case 1

A 74-year-old female, she underwent primary THA in 1984 and revision THA in 2008. Left femoral fracture was occurred in 2012. Stem was stable, and fracture was classified Vancouver type B1 (Figure 1A, 1B). Thus, open reduction and internal fixation with plate and autogenous fibula graft

OPEN ACCESS

*Correspondence:

Takaaki Tanaka, Department of Orthopaedic Surgery, NHO Utsunomiya National Hospital, 2160 Shimomokamoto, Utsunomiya city, Tochigi 329-1103, Japan, Tel: 81286732111;

E-mail: tanakat-2@hosp.go.jp

Received Date: 28 Sep 2018

Accepted Date: 29 Oct 2018

Published Date: 01 Nov 2018

Citation:

Kumagae Y, Tanaka T. Autogenous Fibula Graft for Periprosthetic Femoral Fractures after Revision Total Hip or Knee Arthroplasty. *Clin Surg*. 2018; 3: 2189.

Copyright © 2018 Takaaki Tanaka.

This is an open access article distributed under the Creative Commons Attribution License, which permits unrestricted use, distribution, and reproduction in any medium, provided the original work is properly cited.

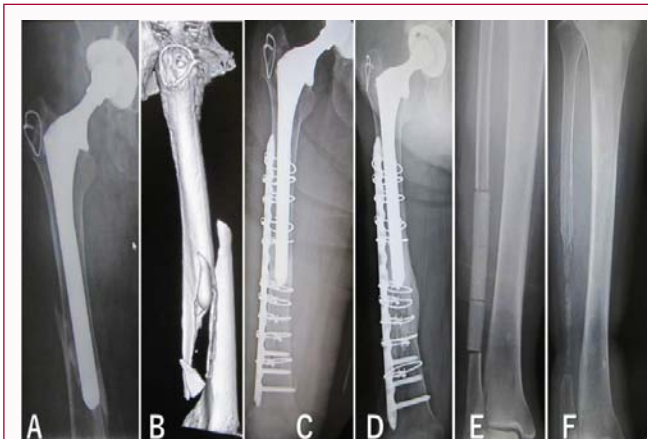

Figure 1: Radiographs and a CT image in a 74-year-old woman showed Vancouver type B1 fracture located distal to the femoral stem (A,B). Open reduction and internal fixation with plate and autogenous fibula graft were performed (C). Beta-TCP blocks with 75% porosity were placed on the periosteum (E). Marked bone formation around the fracture site was recognized 6 years after surgery (D). Partial reconstruction of fibula was found at 6 years (F).

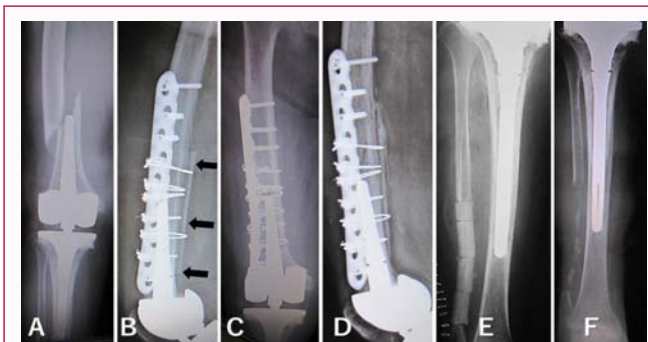


Figure 2: Radiographs in an 89-year-old woman showed periprosthetic femoral fracture after revision TKA occurring at the tip of the stem (A). Fixation with plate and 14 cm of fibula graft were performed (B). One year after surgery, bone union was obtained (C,D). Arrows indicate fibula. Cylindrical beta-TCP blocks with 75% porosity were implanted on the periosteum (E). Beta-TCP blocks were completely resorbed but fibula reconstruction was incomplete at 1 year (F).

were performed (Figure 1C). Marked bone formation was obtained at 6 months, and no deformity or shortening of the femur was recognized 6 years after surgery (Figure 1D). Partial reconstruction of fibula was found (Figure 1E, 1F), but no complain on the donor-site.

Case 2

An 89-year-old female revision TKA using rotating hinge with long stem was performed in 2003. Femoral fracture was occurred at the tip of the long stem in 2012 (Figure 2A). Open reduction and internal fixation with plate and autogenous fibula graft were performed (Figure 2B). One year after surgery bony bridging was recognized (Figure 2C, 2D). Reconstruction of fibula was incomplete (Figure 2E, 2F).

Case 3

A 13-year-old girl an 18 cm long fibula graft was harvested for spinal fusion, and beta-TCP blocks with 75% porosity were placed on the remaining periosteum (Figure 3A). Two years after implantation, the fibula had been completely reconstructed (Figure 3B). Twenty-two years after surgery, the cortical bone and bone marrow had been kept as an original shape of the fibula (Figure 3C, 3D).

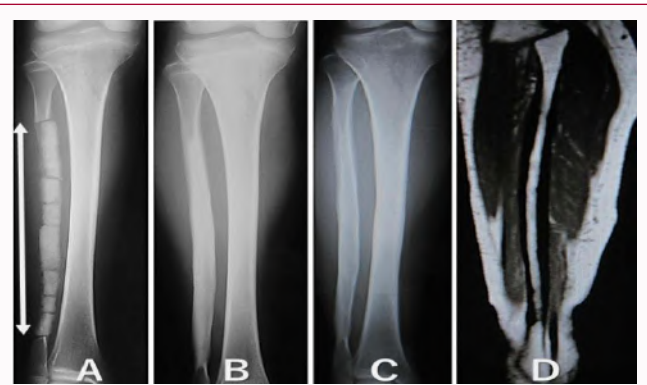


Figure 3: Radiographs of a 13-year-old girl. An 18-cm-long section of the fibula was harvested for spinal fusion, and beta-TCP blocks were placed on the remaining periosteum (A). The arrows indicate beta-TCP blocks with 75% porosity. Resorption of beta-TCP and formation of cortical bone was observed 2 years after surgery (B). Twenty-two years after implantation, the fibula is fully reconstructed (C). In addition, MRI showed bone marrow was also reconstructed (D).

Discussion

Periprosthetic fractures are increasingly common complications associated with THA and TKA, occurring in 0.9% of primary THA, 4.2% in revision THA, and 0.6% primary TKA and 1.7% revision TKA [3]. The Vancouver classification system for post-THA periprosthetic fractures has proven to be reproducible, reliable, and valid [9-12]. Classification of periprosthetic fractures after TKA by Rorabeck [13] is commonly used. In the case with a stable implant classified as Vancouver type B1, fractures can be treated with open reduction and internal fixation using plate with or without cortical strut allograft. Strut graft had advantages of bone formation and biomechanical strength [4,5]. In this study, all periprosthetic femoral fractures were occurred after revision THA or TKA. Thus, circumstances around the fracture sites were not in good condition. In addition, all patients were aged and have osteoporosis. It was not easy to obtain bone union compared to after primary THA or TKA. Tsiridis et al. [5] recommended use of strut allograft. However, significant problems associated with allograft introduction include a low bone-fusion rate and disease transmission [14-15]. In addition, allograft is not easily available in Japan due to religious reason. In contrast, autogenous bone graft is osteoconductive and osteoinductive, and it contains osteogenic cells and osteoinductive growth factors such as Bone Morphogenetic Proteins (BMPs). Thus, we used autogenous fibula graft. However, limitation of supply and donor-site morbidity is present. In order to reduce donor-site morbidity, we have used beta-TCP for reconstruction of harvested bone defects. We previously reported complete reconstruction of fibula after implantation of beta-TCP blocks with 75% porosity [16]. At the time of surgery, the patient was a 13-year-old girl. Eighteen cm of fibular was harvested for spinal fusion and beta-TCP blocks with 75% porosity were implanted on the remaining periosteum. Two years after surgery, beta-TCP was completely replaced by bone. Twenty-two years after surgery, the fibula was still in good shape and MRI showed bone marrow was also reconstructed (Figure 3). It can be used as bone graft again. Based on this experience, we applied the same technique in elderly patients with periprosthetic femoral fractures. The results showed that beta-TCP resorption and bone formation occurred in the beta-TCP implanted site, but reconstruction of fibula was incomplete. However, no one complained pain on the donor-site and proximal and distal tibio-fibular joints. As all patients were old female, they

had osteoporosis. The rate of beta-TCP resorption by osteoclasts was faster than that of bone formation by osteoblasts. Thus, restorative activity should be suppressed. One way is to use denser materials such as beta-TCP blocks with 60% porosity. We evaluated resorption of beta-TCP and bone formation in Opening Wedge High Tibial Osteotomy (OWHTO) using beta-TCP blocks with 60% and 75% porosity [17]. Six years after OWHTO, beta-TCP with 75% porosity was completely resorted and replaced by bone. In contrast, resorption was occurred in beta-TCP with 60% porosity, but approximately 1/3 of TCP was still remained even 6 years after surgery. The other way to inhibit restorative activity of osteoclasts is administration of bisphosphonates. We previously reported that low-dose alendronate inhibited beta-TCP resorption, but not bone formation [18].

In conclusion, a combination of autogenous fibula graft and plate fixation is a useful technique to treat periprosthetic femoral fractures after primary and revision THA or TKA. In addition, reconstruction of fibula using beta-TCP reduced donor-site morbidity.

References

- Berry DJ. Periprosthetic fractures after joint replacement. *Orthop Clin North Am.* 1999;30(2):183-90.
- Lindahl H. Epidemiology of periprosthetic femur fracture around a total hip arthroplasty. *Injury.* 2007;38(6):651-4.
- Meek RMD, Norwood T, Smith R, Brenkel IJ, Howie CR. The risk of periprosthetic fracture after primary and revision total and knee replacement. *J Bone Joint Surg Br.* 2011;93(1):96-101.
- Dennis MG, Simon JA, Kummer FJ, Koval KJ, DiCesare PE. Fixation of periprosthetic femoral shaft fractures occurring at the tip of the stem. *J Arthroplasty.* 2000;15(4):523-8.
- Tsiridis E, Spence G, Gamie, El Masry MA, Giannoudis PV. Grafting for periprosthetic femoral fractures: Strut, impaction or femoral replacement. *Injury.* 2007;38(6):688-97.
- Pike J, Davidson D, Garbuz D, Duncan CP, O'Brien PJ, Masri BA. Principles of treatment for periprosthetic femoral shaft fractures around well-fixed total hip arthroplasty. *J Am Aca Orthop Surg.* 2009;17(11):677-88.
- Laurer HL, Wutzler S, Possner S, Geiger EV, Saman AE, Marzi I, et al. Outcome after operative treatment of Vancouver type B1 and C periprosthetic femoral fractures: Open reduction and internal fixation versus revision arthroplasty. *Ach Orthop Trauma Surg.* 2011;131(7):983-9.
- Marsland D, Mears SC. A review of periprosthetic femoral fractures associated with total hip arthroplasty. *Geriatr Orthop Surg Rehabil.* 2012;3(3):107-20.
- Duncan CP, Masri BA. Fractures of the femur after hip replacement. *Instr Course Lect.* 1995;44:293-304.
- Brady OH, Garbuz DS, Masri BA, Duncan CP. The reliability and validity of the Vancouver classification of femoral fractures after hip replacement. *J Arthroplasty.* 2000;15(1):59-62.
- Royan F, Dodd M, Haddad FS. European validation of the Vancouver classification of peri-prosthetic proximal femoral fractures. *J Bone Joint Surg Br.* 2008;90(12):1576-9.
- Naqvi GA, Baig SA, Awan N. Interobserver and intraobserver reliability and validity of the Vancouver classification system of periprosthetic femoral fractures after hip arthroplasty. *J Arthroplasty.* 2012;27(6):1047-50.
- Rorabeck CH, Taylor JW. Classification of periprosthetic fractures complicating total knee arthroplasty. *Orthop Clin North Am.* 1999;30(2):209-14.
- Aurori BF, Weierman RJ, Lowell HA, Nabel CI, Parsons JR. Pseudoarthrosis after spinal fusion for scoliosis. A comparison of autogenic and allogenic bone grafts. *Clin Orthop.* 1985;199:153-8.
- Karcher HL. HIV transmitted by bone graft. *BMJ.* 1997;314(7090):1300.
- Tanaka T, Komaki H, Chazono M, Kitasato S, Kakuta A, Akiyama S, et al. Basic research and clinical application of beta-TCP. *Morphologie.* 2017;101(334):164-72.
- Tanaka T, Kumagai Y, Chazono M, Kitasato S, Kakuta A, Marumo K. A novel evaluation system to monitor bone formation and beta-tricalcium phosphate resorption in opening wedge high tibial osteotomy. *Knee Surg Sports Traumatol Arthrosc.* 2015;23(7):2007-11.
- Tanaka T, Saito M, Chazono M, Kumagai Y, Kikuchi T, Kitasato S, et al. Effects of alendronate on bone formation and osteoclastic resorption of beta-tricalcium phosphate. *J Biomed Mater Res.* 2010;93(2):469-74.