



## Untreated Periprosthetic Hip Fracture - A Consequence of War

Yasser Farid<sup>1\*</sup> and Tamás S Illes<sup>1,2,3</sup>

<sup>1</sup>Department of Orthopedics & Traumatology, Brugmann University Hospital, Brussels, Belgium

<sup>2</sup>Department of Orthopaedic Surgery and Traumatology, Odense University Hospital and Institute of Clinical Research, University of Southern Denmark, Denmark

<sup>3</sup>National Medical Academy, Paris, France

### Clinical Image

A 79-year-old female refugee from Syria presented to our emergency department with a long history of right hip pain causing walking inability. At age 58, a cemented total hip prosthesis had been implanted due to primary coxarthrosis. In 2012, after a fall, a periprosthetic fracture occurred, which was stabilized using a plate and screws, supplemented with cerclages. She became asymptomatic. Because of the civil war, she was forced to flee Syria with her family. In 2015, she fell again and immediately became incapable of walking. Her family toted her across countries. Being a migrant, she did not have access to adequate medical care. Recent radiographs (AP & lateral) revealed luxation of the prosthesis, with the femur fracture healed with significant angulation (54°) and a loosened acetabulum component (arrows). Unfortunately, the general status of the patient did not allow surgical intervention. Health care of refugees is a serious and unresolved problem.

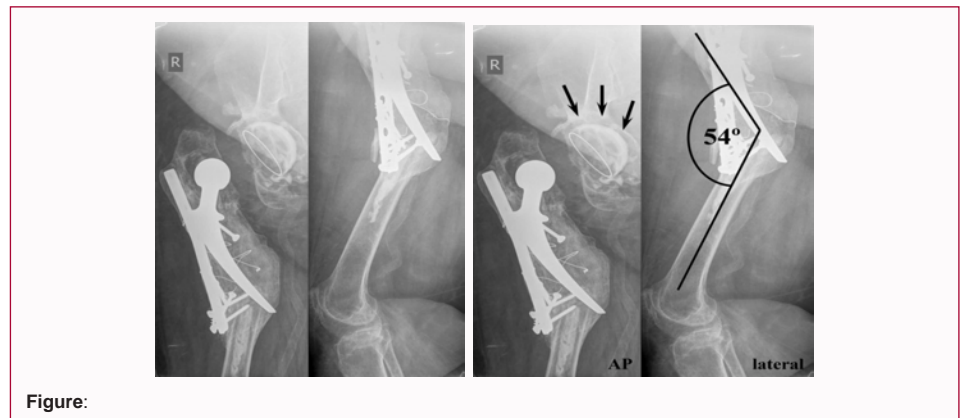


Figure:

### OPEN ACCESS

#### \*Correspondence:

Yasser Farid, Department of Orthopedics & Traumatology, Brugmann University Hospital, Université Libre de Bruxelles, Brussels, Belgium, Tel: 32 495255255;

E-mail: yfarid@ulb.ac.be

Received Date: 28 Sep 2018

Accepted Date: 25 Oct 2018

Published Date: 01 Nov 2018

#### Citation:

Farid Y, Illes TS. Untreated Periprosthetic Hip Fracture - A Consequence of War. *Clin Surg*. 2018; 3: 2182.

**Copyright** © 2018 Yasser Farid. This is an open access article distributed under the Creative Commons Attribution License, which permits unrestricted use, distribution, and reproduction in any medium, provided the original work is properly cited.