



Reported Opening Limitations as a TMD Symptom: A Clinical Report on Diagnoses and Outcome

Alexandra Carlsson¹, Bengt Wenneberg² and Christina Mejersjö^{3*}

¹Centre for Oral Rehabilitation, Public Dental Health, Linköping, Sweden

²Department of Stomatognathic Physiology, Gothenburg University, Sweden

³Clinic of Orofacial Pain, VGRegion Public Dental Health and Sahlgrenska Academy, Sweden

Abstract

Objective: To study diagnoses of reported mouth opening limitations and the outcome after treatment, to better understand the symptom and the prognosis.

Methods: New referrals to an Orofacial Pain & Temporomandibular Disorders (TMD) Clinic with the symptom of “jaw locking” in the referral were considered for this clinical prospective report. This referrals constituted 5.8% of all the referrals during a ten month period, and 40 patients were included. Case history, clinical examination and diagnoses were made according to the RDC/TMD criteria. MRI and CT examinations of the temporomandibular joint were performed when indicated. Reported symptoms and clinical signs were compared for different diagnoses. The treatment was non-invasive and conservative, no patient underwent surgery. At end of treatment, the clinical examination was repeated, the primary and definite diagnoses were compared, and the improvement after treatment was evaluated.

Results: The main diagnoses were disc displacement with reduction (DDwR), 23%, disc displacement without reduction (DDwoR), 30%, and myofascial pain with limited opening (wLO), 45%. General Hypermobility was significantly more frequent in the disc displacement diagnosis compared with myofascial pain ($p < 0.05$). After treatment, the mean opening capacity was good, regardless of the diagnosis.

Conclusion: A report of jaw locking is not indicative of a single diagnosis of TMD. A diagnosis based on the history and a clinical examination is generally accurate. The symptom of opening limitations responds well to conservative treatment methods.

Keywords: Jaw locking; Diagnosis; Treatment outcome; Disc displacement; Myofascial pain

Introduction

Opening limitations, catching and locking of the jaw, are common complains of patients referred to a clinic for orofacial pain and temporomandibular disorders (TMD). TMD is a collective term including a number of clinical symptoms and diagnoses of the masticatory muscles and/or the temporomandibular joints (TMJ) [1]. Dentists and physicians often use the word locking in their referrals and the patient can use the word to describe their condition of opening limitations. Screening questions for reported symptoms are used; “Does your jaw get stuck, locked or get out” [2] and “Does your jaw lock or become stuck once a week or more” [3] with the intention of identifying TMJ or disk problems. Also the RDC/TMD Patient History Questionnaire [4] version 2016, ask “Have you ever had your jaw lock or catch”.

A study among adults found a prevalence of 4% of middle-aged women reporting frequent locking of the jaw [5]. Another epidemiological study among children and adolescents found that 3.7% reported jaw locking [6], while the prevalence of reported intermittent locking of the jaw of adolescents 18 years of age was 14% [7]. A meta-analysis on the prevalence of clinical signs of intra-articular temporomandibular disorders in children and adolescents found a frequency of 2.3% with locking [8].

It can be a major challenge for the clinician to determine whether a patient’s symptoms are caused by disc displacement or due to myofascial pain with limited mouth opening (wLO). Testing the end feel with a downward force on the mandibular incisors with the fingers, a soft end feel and increased mouth opening suggests muscle-caused restriction, while a hard and not increased

OPEN ACCESS

*Correspondence:

Christina Mejersjö, Clinic of Orofacial Pain, VGRegion Public Dental Health and Sahlgrenska Academy Specialisttandvården bettfysiologi, Universitetsklinikerna FTV Västra Götaland, Box 7163, SE-402 33 Gothenburg, Sweden;

E-mail: christina.mejersjo@vgregion.se

Received Date: 21 May 2017

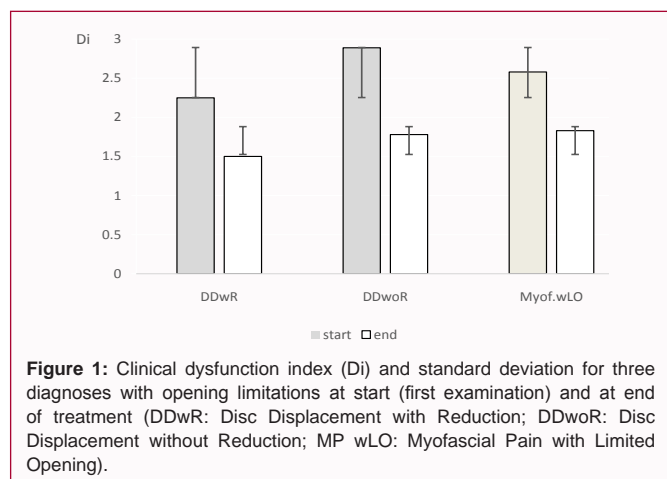
Accepted Date: 17 Jul 2017

Published Date: 24 Jul 2017

Citation:

Carlsson A, Wenneberg B, Mejersjö C. Reported Opening Limitations as a TMD Symptom: A Clinical Report on Diagnoses and Outcome. *Clin Surg*. 2017; 2: 1572.

Copyright © 2017 Christina Mejersjö. This is an open access article distributed under the Creative Commons Attribution License, which permits unrestricted use, distribution, and reproduction in any medium, provided the original work is properly cited.



opening may indicate disc displacement without reduction (DDwoR) [1]. Furthermore, a limited opening capacity of 24 mm - 30 mm with deflection to the affected side, pain in the affected joint, and impaired laterotrusion to the contralateral side but normal to the ipsilateral side, are all signs that could indicate DDwoR. A history of clicking that resolved with a sudden onset of opening limitations has been interpreted as the disc being permanently displaced [1]. General Hypermobility has been identified as a risk factor for disc derangements of the temporomandibular joint [9].

Muscle tissue damage from dental injections (post-injection trismus), excessive chewing, yawning or dental treatment could lead to myalgia causing opening limitations and a sensation of jaw locking. The first muscular response to trauma is often a protective co-contraction, with the antagonist muscles trying to protect the injured part [10]. There is no or little pain when the muscle is at rest, but use of the muscles increases the pain and mouth opening is impaired. Prolonged muscle contractions may lead to local muscle soreness and changes to the muscular tissues through the release of bradykinin, substance p and histamine [11].

Examples of other diagnoses that could result in severe opening limitations are TMJ arthritis, fibrosis and scarring of the TMJ cartilage, oral infections, scleroderma, scars, and trismus caused by neoplasm [12]; however, myofascial pain is the most common diagnosis [13].

A magnetic resonance image (MRI) examination of the TMJ provides an estimation of the relationship between the joint components, but does not always identify the cause of the reported opening limitations [14].

The aims of the study were:

- I. To identify the diagnoses of patients referred for “locking” of the jaw;
- II. To estimate how well the initial clinical examination identified the diagnosis or whether this was changed after additional examinations
- III. To study the features of the different diagnoses and the outcome after treatment.

Materials and Methods

New referrals to the Orofacial Pain & TMD Clinic, Gothenburg, were screened for “locking of the jaw” as described in the referral and it was that description in the referral that qualified the patient

for inclusion in the study. The period of recruitment of consecutive patients for this prospective observation study was ten months. During this period, 783 patients were referred to the clinic, and 45 patients matched the inclusion criteria (nine males and 36 females, aged 17-72 years), constituting 5.8% of the referrals. Five patients postponed their examination and never came to an examination within the study period, leaving 40 patients who were included in the study. The patients were given a priority appointment for examination at the clinic.

At the first visit to the clinic the patients completed a standardized questionnaire concerning their jaw problems and general health. The patient history was taken according to the Research Diagnostic Criteria for TMD (RDC/TMD) [4]. The clinical examination was performed by the same dentist for all the patients and according to the Axis I (clinical condition) of RDC/TMD [15], including maximum opening capacity, with and without pain, and additional “assisted opening” by the examiner, also called “the end feel” [1]. The lateral movement capacity was measured towards the affected, ipsilateral, side and to the contralateral side, and the difference between the directions was calculated. The patient’s history and the clinical examination resulted in a primary diagnosis. The examination was extended [16] to allow for calculation of the clinical dysfunction index evaluating the severity of the clinical dysfunction [17] (Di 0-III; 0=no clinical signs; Di I=mild; Di II=moderate; Di III=severe signs of clinical dysfunction). The patient’s general hypermobility (HMS) was estimated according to Beighton (0-9 points, >4 being hypermobile) [18].

The patient’s diagnosis refers to the side of the current symptoms and the reason for the referral. Intramuscular local anaesthetic was used as a diagnostic tool to block muscle pain. Manipulation of the TMJ disc was performed when DDwoR was clinically suspected.

Computed tomography (CT) and MRI of the TMJs were performed when clinically indicated. The indication for CT was a suspicion of degenerative changes of the TMJ, and for MRI, a suspicion of TMJ disc displacement. The examinations were performed at the Department of Oral and Maxillofacial Radiology, Institute of Odontology, Gothenburg. The preliminary diagnosis of the disc position (RDC group II a or II b) was according to the clinical examination.

The treatment followed the routines at the clinic for the condition and was individually designed, including counselling and information, awareness training and mobilization, local physical training and relaxation, acupuncture and pharmacological management, and stabilization splint [1,19]. No patient had a surgical intervention.

The same clinical examination as at start was repeated at the end of treatment by the same examiner. The patient charts were later looked into and narrowly observed, and reported symptoms, clinical signs at the first examination and at the end of treatment, X-rays and MRI examinations were compared for the different diagnoses. From the patients’ chart, information was collected about the treatment outcome as classified by the patients (impaired, unaltered, improved, obviously improved, and symptom-free) and about any changes of the preliminary diagnosis to the final diagnosis at end of treatment.

The questionnaire and the examination of the patients followed the routines at the clinic. Informed consent to participate in the study was obtained from each patient and the guideline of the Helsinki Declaration has been followed in this investigation. The study was discussed at the Ethical Committee at the University of Gothenburg,

Table 1: Diagnoses of 40 patients with reported mouth opening limitations, preliminary after the first clinical examination and definite for 33 patients after treatment (n: Number of Patients; DDwR: Disc Displacement with Reduction, DDwoR: Disc Displacement without Reduction; wLO: with Limited Opening).

Diagnoses	at start (n)	after treatment (n)	patients with 1visit only (n)
	40	33	7
DDwR	9	4	4
DDwoR	12	9	
Myofascial pain wLO	18	17	3
Arthritis		1	
Degenerative joint disorder	1	2	

and according to their written policy for such studies, no more ethical approval was required.

The SPSS software version 22 was used for statistical processing. Differences in frequency and severity of signs and symptoms between groups were analyzed with the Chi-square and Mann-Whitney U-tests. For analyzing differences of the mandibular moving capacity, the Students t-test was used. The level for statistical significance was set at $p < 0.05$. The agreement between the preliminary and the definite diagnosis was calculated as a percentage of the agreement and with the Cohen's Kappa [20].

Results

The main diagnoses of the patients reporting a symptom of "locking" were, disc displacement with reduction (DDwR) 23%, disc displacement without reduction (DDwoR) 30%, and myofascial pain with limited opening (wLO) 45%. The proportion of females was the same for the diagnoses. The duration of symptoms was longer for DDwR and the experienced locking was often intermittent. The mean age for both DDwR and DDwoR was 35 years, while it was 45 years for the myofascial pain wLO patients, the difference between DDwR and myofascial pain wLO being statistically significant ($p < 0.05$).

The diagnoses at the first examination and at the end of treatment are shown in Table 1. The seven patients with only one appointment at the clinic only received a preliminary diagnosis. Comparing the diagnoses at the start and at the end of treatment for 33 patients, an agreement was found in 80 % and with $\kappa=0.731$ (good agreement [18]). The primary diagnosis was changed in six patients, with the greatest change for DDwoR, where 25% (three patients) had their diagnosis changed; two to myofascial pain wLO and one to arthritis.

Of the 40 patients in the study, eleven patients had a MRI and 17 aCT examination. All DDwoRs were confirmed by MRI, but the examination also revealed DDwoR in the opposite joints in 67% of the patients examined. From the MRI, it was noticed that most joints with DDwoR had an indication of degenerative TMJ changes. Degenerative changes were frequently found by CT in the affected joint but also in the opposite TMJ.

Analyzing features of the different diagnoses, a report of TMJ clicking prior to the experienced locking was common in all three diagnoses, 73% – 89%. Hypermobility was observed in 75% of the patients with DDwR, in 33% of the DDwoR patients and in 20% of the myofascial pain wLO patients. Both the DD diagnoses had significantly more general hypermobility compared with myofascial pain wLO ($p < 0.05$).

Deflection of the mouth-opening path was not an appropriate description of any of the diagnoses studied, nor did the estimation of the end feel differ significantly for any of the diagnoses. Tenderness

on palpation of the TMJ was found in all three diagnoses and was not descriptive of any of them.

TMJ pain on mouth opening was significantly more often found in DDwoR ($p < 0.01$), as was pain on lateral excursion both from and towards the affected side ($p < 0.05$). The lateral excursion towards the contralateral side, compared with towards the affected side, was impaired in DDwoR and the mean difference between the movements was -3 mm (-9 mm – 0 mm). For myofascial pain wLO, the laterotrusion difference ranged from -6 mm to +6 mm (mean + 1.4 mm); however, the difference between the diagnoses was not statistically significant.

The outcome after treatment was good for all diagnoses; for DDwoR, 78% were improved and 22% were symptom-free, for DDwR, 75% were improved but no symptom-free, and for myofascial pain wLO, 66% were improved and 13% symptom-free. The clinical dysfunction index was significantly reduced after treatment for all three diagnoses (Figure 1), and the mouth opening capacity was significantly improved, reaching a mean of 45 mm for DDwoR and myofascial pain wLO ($p < 0.001$), and 46 mm for DDwR ($p < 0.05$). On average, the patients had a treatment period of ten months (2-16 months) and five visits (2-11) to the clinic.

Discussion

The main findings of the study were that myofascial pain wLO was a more frequent diagnosis underlying the patient's report of jaw locking than DDwoR. A TMJ disc with a closed lock is sometimes regarded as identical with a sensation of locking, but severely limited mouth opening can be due to either muscle or joint problems, and sometimes there is also a displaced disc in a patient with myofascial pain. Differentiating between muscle and joint symptoms may be difficult, and a rather similar status was found for both muscle and joint causes.

The primary diagnoses determined after only history-taking and a clinical examination were often accurate, but the features of the different diagnoses were not as clear as described [1,15]. A history of clicking before the opening limitations appeared was frequently reported for all three diagnoses studied, and the end feel [1] failed in our study to disclose clear differences.

The impairment of lateral movement was more elusive. Impaired lateral mandibular movement to the contralateral side was descriptive of DDwoR. Hypermobility is a known risk factor for TMJ disc disorders [9] and was also in this study associated with disc displacement.

The MRI examination confirmed DDwoR in the patients with that clinical diagnosis, but also frequently revealed disc derangement of the opposite joint, although asymptomatic. Probably, some disc

displacements were present among those not examined with MRI, however, not the current problem. The DDwoR noticed on MRI could also be a consequence of an impaired mouth opening due to muscle pain and no reduction of the disc occurred at the time of the examination. One of the shortcomings of the study is that not all patients had a MRI examination showing the disc position of the side of the patient's symptoms, but the study focus on the patient's current symptoms which is not always explained by the MRI picture. The finding of the study of frequent degenerative changes in joints with DD is in accordance with other studies, like Cortes et al. [21], who found a significant association between disc displacement and degenerative changes.

There has been some discussion concerning whether the term disc derangement would better describe the status of a TMJ with disc displacement [22]. Epidemiologically, disc displacement is frequently found, often without any pain or impaired mouth opening. In some cases the development of a new pseudo disc has also been described [23].

For most of the patients, hyperactivity and overloading of the muscles and the TMJs were recognized as the cause of the symptoms. The treatment focused on measures to unload and relax the system, to promote a varied functional pattern and improved mouth opening with or without the disc in its original place [1,19]. According to the dysfunction index, the outcome after treatment was good, but numerically better for DD than for myofascial pain wLO, which was also noticed by Takahara [24].

The study found a good result of conservative treatment methods of reported limited mouth opening. Surgical treatment of disc displacement has produced varied results. Lavage gave an effect equivalent to that of local anesthetics [25], and another study found lavage to be an effective method when the effect of previous conservative treatment was poor [26]. In a follow-up after 24 and 60 months, Schiffmann et al. [27] found no difference in treatment effect between four different strategies for closed lock. Manipulation of the TMJ disc seldom gives a lasting result, and a review [28] concludes that DDwoR should be treated by the simplest and least invasive method.

After treatment the dysfunction was significantly reduced and the maximum mouth opening reached about the same mean capacity, regardless of the diagnosis. This reassuring information is important to give to the patient, who often finds the symptom very unpleasant. The proportion of 5.8% of the referrals expressing symptoms of jaw locking is close to the report of 6% by Dahlström [29], and he concluded that there is often a combination of myalgia and disc displacement. Reported locking has been identified as one predictor of the onset of TMD symptoms [30], which indicates the importance of paying attention to the symptom.

To conclude, the sensation of jaw locking is not a defined dental symptom and is not an expression of a single diagnosis but of many diagnoses with the symptom of mouth opening limitations. The patient's history and the clinical examination often provide sufficient information for the diagnosis; the symptom responds well to conservative treatment and has a good prognosis. Impaired lateral movement from the affected side and TMJ pain on mandibular movement was descriptive of DDwoR.

References

- Okeson JP, editor. Management of temporomandibular disorders and

occlusion. 7th ed. Mosby: Elsevier Inc. 2013;129-69,222-90.

- American Academy of Orofacial Pain. General assessment of the orofacial pain patient. De Leeuw R, Klasser GD, editors. Orofacial pain – guidelines for assessment, diagnosis and management. 5th ed. Chicago: Quintessence. 2013:25-46.
- Lövgren A, Visscher CM, Häggman-Henrikson B, Lobbezoo F, Marklund S. Validity of three screening questions (3Q/TMD) in relation to the DC/TMD. *J Oral Rehabil.* 2016;43(10):729-36.
- Schiffman EL, Truelove E, Ohrbach R, Andersson G, John MT, List T, et al. The Research Diagnostic Criteria for Temporomandibular Disorders. I: overview and methodology for assessment of validity. *J Orofac Pain.* 2010;24:7-24.
- Yekkalam N, Wänman A. Prevalence of signs and symptoms indicative of temporomandibular disorders and headaches in 35-, 50-, 65- and 75-year-olds living in Västerbotten, Sweden. *Acta Odontol Scand.* 2014;72(6):458-65.
- Hirsch C, Hoffmann J, Turp JC. Are temporomandibular disorder symptoms and diagnosis associated with pubertal development in adolescents? An epidemiological study. *J Orofac Orthop.* 2012;73:6-8,10-18.
- Mejersjö C, Ovesson D, Mossberg B. Oral parafunctions, piercing and signs and symptoms of temporomandibular disorders in high school students. *Acta Odontol Scand.* 2016;74(4):279-84.
- da Silva CG, Pachêco-Pereira C, Porporatti AL, Savi MG, Peres MA, Flores-Mir C. Prevalence of clinical signs of intra-articular temporomandibular disorders in children and adolescents: A systematic review and meta-analysis. *J Am Dent Assoc.* 2016;147:10-18.
- Chang TH, Yuh DY, Wu YT, Cheng WC, Lin FG, Shieh YS, et al. The association between temporomandibular disorders and joint hypermobility syndrome: a nationwide population-based study. *Clin Oral Investig.* 2015;19:2123-32.
- Okesson JP. Bell's Orofacial Pains. The clinical Management of Orofacial Pain. 6th edition, Chicago, Quintessence Publishing. 2005:287-328.
- Tegeger L, Zimmermann J, Meller ST, Geisslinger G. Release of algogenic substances in human experimental muscle pain. *Inflamm Res.* 2002;51(8):393-402.
- Stern D. Benign and Malignant Tumors. In: Laskin DM, Green CS, Hylander WL (editors). Temporomandibular Disorders: an evidence-based approach to diagnosis and treatment. Quintessence Publishing Co, Inc. 2006:319-33.
- Manfredini D, Guarda Nardini L. TMD classification and epidemiology. In: Manfredini D (ed). Current concepts on temporomandibular disorders. Quintessence Publishing Co, Ltd. 2010:32-5.
- Emshoff R, Rudisch A, Innerhofer K, Brandlmaier I, Moschen I, Bertram S. Magnetic resonance imaging findings of internal derangement in temporomandibular joints without a clinical diagnosis of temporomandibular disorder. *J Oral Rehabil.* 2002;29:516-22.
- Look JO, Schiffman EL, Truelove EL, Ahmad M. Reliability and validity of Axis I of the Research Diagnostic Criteria for temporomandibular disorders (RDC/TMD) and proposed revisions. *J Oral Rehabil.* 2010;37:744-59.
- Carlsson GE, Magnusson T. Management of temporomandibular disorders in the general dental practise. Chicago: Quintessence; 1999:67-78.
- Helkimo M. Studies on function and dysfunction of the masticatory system. II. Index for anamnestic and clinical dysfunction and occlusal state. *Sv Tandlak Tidsskr.* 1974;67:101-21.
- Horan FT, Beighton PH. Recessive inheritance of generalized joint hypermobility. *Rheumatol Rehabil.* 1973;12(1):47-9.
- Cortés D, Exss E, Marholz C, Millas R, Moncada G. Association between

- disk position and degenerative bone changes of the temporomandibular joints: an imaging study in subjects with TMD. *Cranio*. 2011;29(2):117-26.
20. Practical statistics for medical research. Altman DG, editor. London: Chapman and Hall. 1991;406-8.
21. Cortes D, Exss E, Marholz C, Millas R, Moncada G. Association between disk position and degenerative bone changes of the temporomandibular joints: an imaging study in subjects with TMD. *Cranio*. 2011;29:117-26.
22. Stegenga B, de Bont LGM. TMJ disc derangements. In: Laskin DM, Green CS, Hylander WL, editors. *Temporomandibular Disorders: an evidence-based approach to diagnosis and treatment*. Quintessence Publishing Co, Inc. 2006:125-36.
23. Bristela M, Schmid-Schwap M, Eder J, Reichenberg G, Kundi M, Piehslinger E, et al. Magnetic resonance imaging of temporomandibular joint with anterior disk dislocation without reposition – long-term results. *Clin Oral Invest*. 2016;16.
24. Abboud W, Yahalom R, Givol N. Treatment of Intermittent Locking of the Jaw in Wilkes Stage II Derangement by Arthroscopic Lysis and Lavage. *J Oral Maxillofac Surg*. 2015;73(8):1466-72.
25. Schiffman EL, Velly AM, Look JO, Hodges JS, Swift JQ, Decker KL, et al. Effects of four treatment strategies for temporomandibular joint closed lock. *Int J Oral Maxillofac Surg*. 2014;43(2):217-26.
26. Abboud W, Yahalom R, Givol N. Treatment of Intermittent Locking of the Jaw in Wilkes Stage II Derangement by Arthroscopic Lysis and Lavage. *J Oral Maxillofac Surg*. 2015;73(8):1466-72.
27. Schiffman EL, Velly AM, Look JO, Hodges JS, Swift JQ, Decker KL, et al. Effects of four treatment strategies for temporomandibular joint closed lock. *Int J Oral Maxillofac Surg*. 2014;43(2):217-26.
28. Al-Baghdadi M, Durham J, Araujo-Soares V, Robalino S, Errington L, Steele J. TMJ disc displacement without reduction management: A systematic review. *J Dent Res*. 2014;93(7 Suppl):37S-51S.
29. Dahlström L. Diagnoses among referrals to a Swedish clinic specialized in temporomandibular disorders. *Acta Odontol Scand*. 1998;56(3):143-7.
30. Ohrbach R, Bair E, Fillingim RB, Gonzalez Y, Gordon SM, Lim PF, et al. Clinical orofacial characteristics associated with risk of first-onset TMA: the OPPERA prospective cohort study. *J Pain* 2013;14(12 Suppl) T33-50.