



Study of the Effect of Ankaferd Blood Stopper on Outcome of Total Thyroidectomy

Aly Saber^{1*}, Emad K Bayum² and Leonie Sophia van den Hoek³

¹Department of Surgery, Port-Fouad General Hospital, Egypt

²Department of General Surgery, Medical Academy Named after S.I. Georgiesky of Crimea Federal University, Russia

³Department of Health Psychology, Liberty International University, USA

Abstract

Introduction: During thyroidectomy, bleeding may obscure the operative field making safe dissection of recurrent laryngeal nerve and parathyroid gland difficult and prolonging the operation time. Ankaferd Blood Stopper (ABS) is a novel topical hemostatic agent of plant origin. The hemostatic mechanism of ABS involves the formation of an encapsulated protein network representing focal points for vital erythrocyte aggregation. The aim of this study was to compare the effectiveness of ABS as a local hemostatic agent for control thyroid bed bleeding after total thyroidectomy for benign thyroid diseases versus hemostasis achieved by conventional electrocauterization.

Patients and Methods: A total of 200 patients were subjected to primary total thyroidectomy for bilateral multinodular goitre due to compression symptoms or cosmetic purposes without previous neck surgery or radiotherapy. Our patients were divided into two main groups Ankaferd (group A) and Suture-Ligation (group B).

Outcome Parameters: The following parameters were measured to compare the effect of ankaferd blood stopper versus conventional suture-ligation technique in decreasing the operative blood loss, operative time, securing laryngeal nerves and parathyroids, postoperative drainage and postoperative wound infection.

Results: Regarding the demographic data of our patients, there was no statistical difference between the two groups regarding age, sex and body mass index and also there was neither operative mortality nor 30 day death. In the ankaferd-treated group, mean operative time, mean intraoperative bleeding and postoperative drainage volumes were all reduced when compared with conventional suture-tie technique.

Conclusion: In thyroid surgery like any other surgical interference, meticulous dissection with secured hemostasis are the most important steps to prevent intraoperative and postoperative bleeding. Ankaferd blood stopper seems effective in reducing both operative bleeding and postoperative drainage volumes when compared with the conventional suture and tie maneuver. Regarding its safety, ankaferd causes neither a foreign body reaction nor thrombocyte activation and actually allows the regeneration process to be completed with minimal signs of inflammation.

Keywords: Total thyroidectomy; Multinodular goiter; Ankaferd

Introduction

Total thyroidectomy has been accepted as current surgical therapy for benign and malignant thyroid diseases but with increased risk of postoperative complications [1]. During thyroidectomy, bleeding may obscure the operative field making safe dissection of recurrent laryngeal nerve and parathyroid gland difficult and prolonging the operation time. Effective vessel haemostasis can be achieved by suture knot tying technique or newer techniques of vessel haemostasis like ligasure as an alternative bipolar surgical diathermy system [2]. Ankaferd Blood Stopper (ABS) is a novel topical hemostatic agent of plant origin. The hemostatic mechanism of ABS involves the formation of an encapsulated protein network representing focal points for vital erythrocyte aggregation [3]. The use of ABS in swine bleeding model, in an experimental liver laceration model, upper gastrointestinal hemorrhage, and tonsillectomy, have been reported in the literature [4,5]. The aim of this study was to compare the effectiveness of ABS as a local hemostatic agent for control thyroid bed bleeding after total thyroidectomy for benign thyroid diseases versus hemostasis achieved by conventional

OPEN ACCESS

*Correspondence:

Aly Saber, Department of Surgery, Port-Fouad General Hospital, Egypt,
E-mail: Alysaber54@gmail.com

Received Date: 06 Feb 2017

Accepted Date: 17 Apr 2017

Published Date: 24 Apr 2017

Citation:

Saber A, Bayumi EK, van den Hoek LS. Study of the Effect of Ankaferd Blood Stopper on Outcome of Total Thyroidectomy. *Clin Surg*. 2017; 2: 1421.

Copyright © 2017 Aly Saber. This is an open access article distributed under the Creative Commons Attribution License, which permits unrestricted use, distribution, and reproduction in any medium, provided the original work is properly cited.

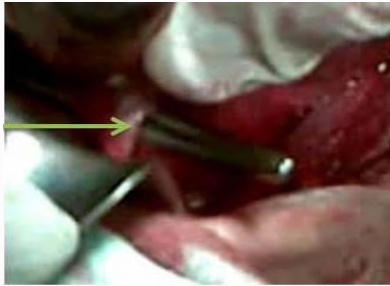

Figure 1: An operative photograph showing the terminal branches of the superior thyroid artery identified and dissected meticulously close to the thyroid capsule. The arrow indicated the superior thyroid pedicle.

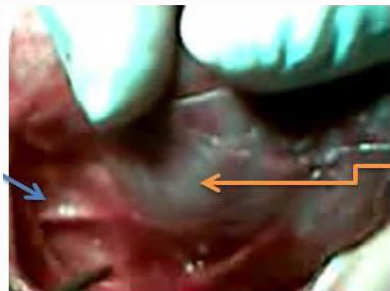

Figure 2: An operative photograph showing the recurrent laryngeal nerve; the blue arrow while the yellow arrow indicated the right thyroid lobe.

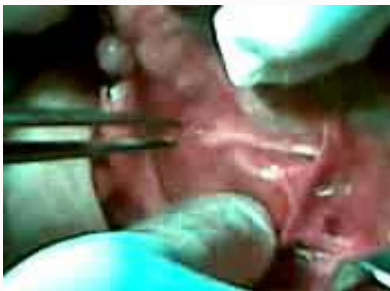

Figure 3: An operative photograph showing the recurrent laryngeal nerve along its course.

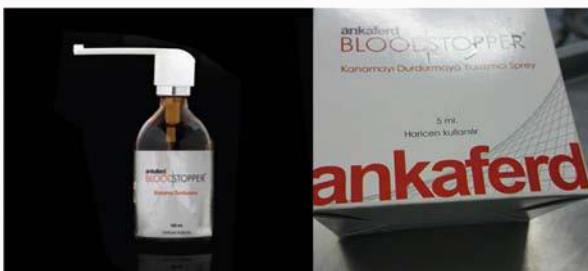

Figure 4: Showed the bottle of ankaferd spray.

electrocauterization.

Patients and Methods

A total of 200 patients diagnosed to have bilateral multinodular goitre were enrolled to this study conducted in Port Fouad General Hospital, Port-Fouad, Egypt from April 2010 to Mayo 2016. Patients were subjected to primary total thyroidectomy due to compression symptoms or cosmetic purposes without previous neck surgery or radiotherapy. All patients' data were collected such as the patient's

demographic data (age at diagnosis, gender, occupation and residence), body mass index (BMI) and the presenting symptoms (dysphagia dyspnea, hoarseness, and others). Our patients were divided into two main groups Ankaferd (group A) and Suture-Ligation (group B). The treating team obtained written consent from all patients or first-degree relatives before the management procedure and the local ethics committee approved the study.

Preoperative Workup

The status of vocal cords for all patients was checked in the preoperative period our otorhinolaryngologist using direct rigid laryngoscope (rigid laryngeal endoscope, Storz 70° with video monitor was used for laryngeal evaluation) during maximum phonation and maximum inspiration (full adduction and full abduction) to ensure intact both superior laryngeal nerve (SLN) and recurrent laryngeal nerve (RLN). The preoperative preparation for thyroidectomies for the bilateral multinodular goitre patients included the following investigations: neck ultrasound, determination of free T3, free T4, thyroid stimulating hormone (TSH) and serum calcium level, and fine-needle aspiration cytology.

Operative Steps

In total thyroidectomy, an extra capsular removal of the entire thyroid glandis performed including pyramidal lobe while preserving the parathyroid glands, recurrent laryngeal nerves, and external branches of the superior laryngeal nerves. The terminal branches of the superior thyroid artery were identified and dissected meticulously close to the thyroid capsule as possible to avoid damaging the superior laryngeal nerve (Figure 1). The external branch of the superior laryngeal nerve travels inferiorly along the lateral surface of the inferior constrictor until it terminates at the cricothyroid muscle (Figure 2). The delicate technique was performed by seeking, identifying and exposing the recurrent laryngeal nerve itself with all branches, and following its course with care until it entered larynx (Figure 3). The main trunk of the inferior thyroid artery was preserved and the branches entering the thyroid only were cut between ligatures to preserve the blood supply of the parathyroid then all the parathyroid glands were identified, if possible. Hemostasis of the thyroid bed was secured using ankaferd spray (Figure 4) locally in patients for group A while in group B, hemostasis was secured by the use of electrocauterization and suturing.

Postoperative Period

For detection the status of laryngeal nerves in all patients, vocal cords were checked immediately postoperatively by laryngoscope and at the day 10 of postoperative period to assess the status of both laryngeal nerves. Temporary RLN paralysis after 6 months was considered permanent. Clinical evidence of SLN injury was considered as breathy voice or diminished vocal frequency range, especially with regard to raising pitch. Using direct laryngoscope, signs of bowing, and inferior displacement of the affected cord on examination were diagnostic [1]. The function of the parathyroid glands was checked immediately in the postoperative period by detecting the serum calcium concentration and parathyroid hormone level. Postoperative hypocalcaemia was considered when calcium level was lower than 8.0 mg/dL (reference range 8.2 - 10.2 mg/dL). Temporary hypocalcemia was defined as a calcium level lower than 8.0 mg/dL in at least two consecutive samples (twice daily for 3 days). In these patients, hypocalcemia resolved within days. Conversely, in patients who were symptomatic and required vitamin D with

Table 1: showing the demographic data of both groups regarding age, sex and body mass index.

		Group A	Group B	P value
Age	30---	22	21	NS
	30--44	48	51	
	45--60	30	28	
Sex	Male	39	37	
	Female	61	63	
BMI	MBI < 25 [22---24.9]	36	38	
	MBI < 30 [25---29.9]	44	43	
	MBI > 30[30---34.9]	20	19	

Table 2: shows the operative time in both groups A & B as the maximum, minimum and mean values.

Group	Maximum	Minimum	Mean
A	85	120	100
B	110	140	127

Table 3: shows the amount of blood loss and fluid drained in both groups A & B as the maximum, minimum and mean values.

Group	Operative blood loss			Fluid drained		
	Maximum	Minimum	Mean	Maximum	Minimum	Mean
A	40	60	48	55	30	38
B	9	60	75	80	50	66

or without calcium supplementation, we considered temporary hypocalcemia to be severe when calcium levels remained lower than 8.0 mg/dL for more than 3 days. In these patients, hypocalcemia resolved within 6 months. In patients who required vitamin D and calcium supplementation for more than 6 months, we considered hypoparathyroidism to be permanent [1].

Outcome Parameters

The following parameters were measured to compare the effect of ankaferd blood stopper versus conventional suture-tie technique in decreasing the operative blood loss, operative time, securing laryngeal nerves and parathyroids, postoperative drainage and postoperative wound infection.

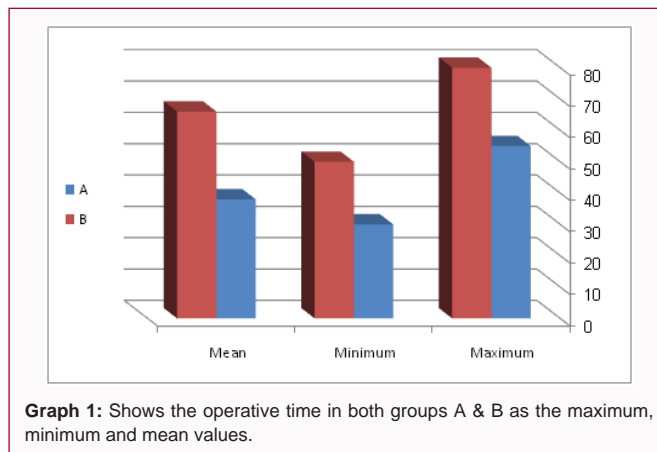
Statistical Analysis

Data collected were processed using SPSS version 15 (SPSS Inc., Chicago, IL, USA). Quantitative data were expressed as means ± SD while qualitative data were expressed as numbers and percentages (%).

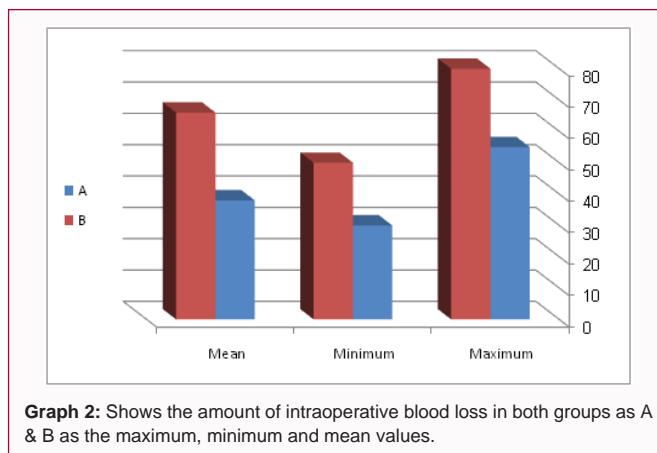
Results

On studying the demographic data of our patients in both groups, the authors found no statistical difference between the two groups regarding age, sex and body mass index and also there was neither operative mortality nor 30 day death in our patients as shown in (Table 1).

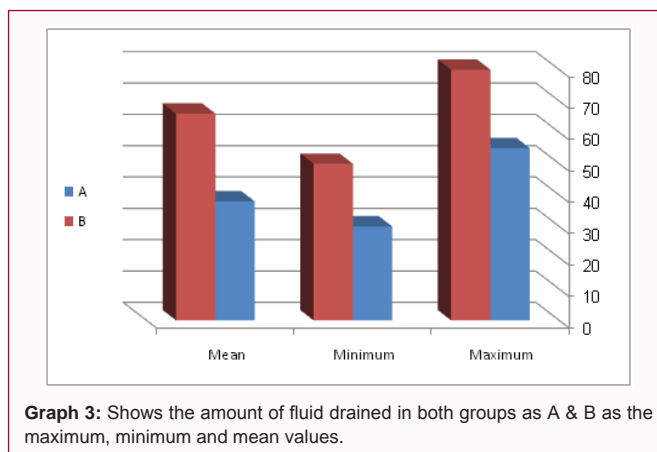
As regard the operative time, in ankaferd-treated group it was between 85-120 min with a mean value of 100.54 ± 11.96 min while in suture-ligation group, the operative time was between 110-140 min with a mean value of 127.1 ± 7.95 minutes and this difference is considered to be extremely statistically significant (t=18.6266, df=198, P≤ 0.0001) (Table 2).



Graph 1: Shows the operative time in both groups A & B as the maximum, minimum and mean values.



Graph 2: Shows the amount of intraoperative blood loss in both groups as A & B as the maximum, minimum and mean values.



Graph 3: Shows the amount of fluid drained in both groups as A & B as the maximum, minimum and mean values.

The amount of intraoperative blood loss using the standard absorptive gauze measuring 30 cm × 30 cm was 40-60 ml in group A (mean 48.45 ± 7.06) and 60-90 in group B (mean 75.84 ± 9.21) respectively and this difference is considered to be extremely statistically significant (t = 23.6026, df=198, P ≤ 0.0001).

(3%) in group A and in 5 patients in group B (5%). No permanent hypoparathyroidism was seen in group A patients but in one patient (1%) of group B, transient hypoparathyroidism occurred in 2 patients (2%) of both groups.

The amount of fluid drained in the postoperative period in group A was 30-55 ml (38.55 ± 7.11) and 50-80 ml (66.28 ± 8.99) respectively and this difference is considered to be extremely statistically significant (t=24.1935, df=198, P≤ 0.0001).

Discussion

During thyroidectomy bleeding may obscure the operative field making safe dissection of recurrent laryngeal nerve and parathyroid gland difficult and prolonging the operative time [2]. Thyroid surgery involves meticulous devascularization of the thyroid gland, which has one of the richest blood supply of all organs, with numerous blood vessels and plexuses entering its parenchyma [1,2]. In general, the essential objectives for thyroidectomy are: sparing the parathyroid glands, avoidance of injury to the laryngeal nerves, an accurate hemostasis and an excellent cosmesis [6]. Therefore, hemostasis is of paramount importance when dividing the various vessels before excising the gland [1,2]. Numerous technical advances have emerged in hemostasis, the suture ligatures, vessel ligating clips, electrocoagulation by mono- or bipolar instruments, and topical hemostatic agents, the use of which is mainly promoted in the last years in thyroid surgery as in other surgical disciplines [7].

Regarding the operative time, the mean operative time in our patients with suturing and electrocauterization came in concordance with those reported in previous studies [1,2,7-9]. The conventional suture knot tying technique requires a large number of surgical ties and this maneuver is time consuming and requires good hemostasis [10]. However, thermal damage to the surrounding structures can occur in the areas of electrocoagulation. Also, it is difficult to satisfy oozing-type bleeding near vulnerable anatomic structures, such as the RLN and the parathyroid glands [3]. However in previous studies, when fibrin glue is used as local hemostatic agent the mean time spent to achieve hemostasis was 23.9 min [11] while on using Floseal, bleeding ceased within 10 min [12]. In the present study, using ankaferd spray hemostasis was achieved rapidly within seconds allowing surgeon to control bleeding properly and therefore the mean operative time and the mean amount of operative bleeding in ankaferd group was statistically reduced. Estimation of intra-operative blood loss is governed by visual method and the clinical assessment with collaboration with the anesthetist. Regarding visual estimation of blood loss; the authors in this present study relied on the standard absorptive gauze measuring 30 cm × 30 cm. When it was soaked by 50% the means that it contains about 25 ml of blood and if totally soaked; 100% this means that it contains 75 ml of blood [13]. The authors reported significant reduction of intra-operative blood loss when they used ankaferd spray directly to the bed of thyroid gland in total thyroidectomy when compared with the conventional suture-tying technique and our data came in agreement with those reported results [3,4].

There are many topical agents examined for the hemostatic effect such as tranexamic acid with its antifibrinolytic activity on perioperative bleeding, fibrin sealant as hemostatic local agent, Floseal, matrix hemostatic agents and Surgicel as an oxidized cellulose patch [7,13-15]. An ideal agent would be effective, inexpensive, bioabsorbable, safe, and easy to use. In literature, however, some adverse events for hemostatic agents have been described, such as, wound infection, edema, nerve entrapment, allergic reaction and misleading appearance on postoperative imaging [15-17]. The use of oxidized cellulose gauze is associated with the relevant possibility of foreign body reactions that can cause undesirable effects, such as an increase in the incidence of seroma [7]. In case of using of Floseal, possible allergic eosinophil rich inflammatory response has resulted in excessive formation of granulation tissue and fibrosis [13,16]. There are numerous publications on adverse effects of the use of Floseal, including small bowel obstruction, excessive synechia

formation, excessive post-operative pain, foreign body reaction resulting in caseating granulomas and microcalcifications mimicking malignancy [18,19]. These topically applied agents really showed reduced mean volume of intraoperative bleeding as well as mean postoperative drainage when compared with the conventional suture knot tying techniques but with some relative side effects [7,13,15-19]. However, ankaferd blood stopper actually reduced both mean volume of intraoperative bleeding and mean postoperative drainage significantly [3,4,20,21].

ABS causes neither a foreign body reaction nor thrombocyte activation and actually allows the regeneration process to be completed with minimal signs of inflammation [22]. The unique mechanism of action of ABS offers a major advantage; not only does it provide hemostasis in patients with normal hemostatic parameters, it can also ensure hemostasis during bleeding episodes in patients with primary and secondary hemostasis impairment, unlike other agents [23-25].

Conclusion

In thyroid surgery like any other surgical interference, meticulous dissection with secured hemostasis are the most important steps to prevent intraoperative and postoperative bleeding. Ankaferd blood stopper seems effective in reducing both operative bleeding and postoperative drainage volumes when compared with the conventional suture and tie maneuver. Regarding its safety, ankaferd causes neither a foreign body reaction nor thrombocyte activation and actually allows the regeneration process to be completed with minimal signs of inflammation.

References

1. Rifaat M, Saber A, Hokkam EN. Total Versus Subtotal Thyroidectomy for Benign Multinodular Goiter: Outcome and Complications. *J Curr Surg*. 2014;4(2):40-45.
2. Al Juraibi W, Ahmed MR, Saber A. Use of Ligasure Sealing Versus Conventional Suture - Ligation in Total Thyroidectomy. *J Surg*. 2016;4(3-1):34-38.
3. Guler M, Maralcan G, Kul S, Baskonus I, Yilmaz M. The Efficacy of Ankaferd Blood Stopper for the Management of Bleeding Following Total Thyroidectomy. *J Invest Surg*. 2011;24:205-10.
4. Bilgili H, Kosar A, Kurt M, Onal IK, Goker H, Captug O, et al. Hemostatic efficacy of Ankaferd Blood Stopper in a swine bleeding model. *Med Princ Pract*. 2009;18(3):165-9.
5. Karakaya K, Ucan HB, Tascilar O, Emre AU, Cakmak GK, Irkorucu O, et al. Evaluation of a new hemostatic agent Ankaferd Blood Stopper in experimental liver laceration. *J Invest Surg*. 2009;22(3):201-6.
6. Dionigi G, Wu CW, Kim HY, Liu X, Liu R, Randolph GW, et al. Safety of energy based devices for hemostasis in thyroid surgery. *Gland Surg*. 2016;5(5):490-494.
7. Tartaglia N, Di Lascia A, Lizzi V, Cianci P, Fersini A, Ambrosi A, et al. Haemostasis in Thyroid Surgery: Collagen-Fibrinogen-Thrombin Patch versus Cellulose Gauze—Our Experience. *Surgery Research and Practice*. 2016;2016(5):1-5.
8. Khafagy AH, Abdelnaby I. Total thyroidectomy: Ligasure versus Clamp & Knot technique for intraoperative hemostasis. *Egyptian Journal of Ear, Nose, Throat and Allied Sciences*. 2013;14(2): 59-65.
9. Ahnen T, Ahnen M, Wirth U, Barisic A, Schardey H, Schopf S. Comparison of an Intraoperative Application of a Haemostatic Agent (PerClot) with Conventional Haemostatic Procedure after Thyroid Resection. *Surg Sci*. 2015;6:239-46.

10. Challa S, Sushama Surapaneni. Sutureless thyroidectomy vasucular control using bipolar electrothermal cautery. *J Evol Med Dent Sci.* 2012;1(6):1083-86.
11. Emir S, Bali İ, Sözen S, Yazar FM, Kanat BH, Gürdal SÖ, et al. The efficacy of fibrin glue to control hemorrhage from the gallbladder bed during laparoscopic cholecystectomy. *Ulus Cerrahi Derg.* 2013;29(4):158-61.
12. Sartelli M, Catena F, Biancafarina A, Tranà C, Piccardo A, Ceccarelli G, et al. Use of Floseal Hemostatic Matrix for Control of Hemostasis During Laparoscopic Cholecystectomy for Acute Cholecystitis: A Multicenter Historical Control Group Comparison (The GLA Study Gelatin Matrix for Acute Cholecystitis). *J Laparoendosc Adv Surg Tech A.* 2014;24(12):837-41.
13. Saber A, Abu-Elela ST, Shaalan KM, Al-Masry AR. Preoperative Prediction of the Difficulty of Laparoscopic Cholecystectomy. *J Surg Surgical Res.* 2015;1(1):015-018.
14. Ujam A, Awad Z, Wong G, Tatla T, Farrell R. Safety trial of Floseal^(®) haemostatic agent in head and neck surgery. *Ann R Coll Surg Engl.* 2012;94(5):336-9.
15. Testini M, Marzaioli R, Lissidini G, Lippolis A, Logoluso F, Gurrado A, et al. The effectiveness of FloSeal matrix hemostatic agent in thyroid surgery: a prospective, randomized, control study. *Langenbecks Arch Surg.* 2009;394(5):837-42.
16. Amit M, Binenbaum Y, Cohen JT, Gil Z. Effectiveness of an Oxidized Cellulose Patch Hemostatic Agent in Thyroid Surgery: A Prospective, Randomized, Controlled Study. *J Am Coll Surg.* 2013;217:221-5.
17. Ujam A, Awad Z, Wong G, Tatla T, Farrell R. Safety trial of Floseal^(®) haemostatic agent in head and neck surgery. *Ann R Coll Surg Engl.* 2012;94(5):336-9.
18. Tublin ME, Alexander JM, Ogilvie JB. Appearance of absorbable gelatin compressed sponge on early post-thyroidectomy neck sonography: a mimic of locally recurrent or residual thyroid carcinoma. *J Ultrasound Med.* 2010;29(1):117-20.
19. Thomas PJ, Tawfic SN. Eosinophil-rich inflammatory response to FloSeal hemostatic matrix presenting as postoperative pelvic pain. *Am J Obstet Gynecol.* 2009;200:e10-e11.
20. Suzuki Y, Vellinga TT, Istre O, Einarsson JI. Small bowel obstruction associated with use of a gelatin-thrombin matrix sealant (FloSeal) after laparoscopic gynecologic surgery. *J Minim Invasive Gynecol.* 2010;17:641-5.
21. Kazancioglu HO, Çakir O, Ak G, Zülfiyar B. The effectiveness of a new hemostatic agent (Ankaferd blood stopper) for the control of bleeding following tooth extraction in hemophilia: a controlled clinical trial. *Turk J Haematol.* 2013;30(1):19-24.
22. Amer MZ, Mourad SI, Salem AS, Abdelfadil E. Correlation between international normalized ratio values and sufficiency of two different local hemostatic measures in anticoagulated patients. *Eur J Dent.* 2014;8(4):475-80.
23. Satar NY, Akkoc A, Oktay A, Topal A, Inan K. Evaluation of the hemostatic and histopathological effects of Ankaferd Blood Stopper in experimental liver injury in rats. *Blood Coagul Fibrinolysis.* 2013;24(5):518-24.
24. Kurt M, Onal IK, Akdogan M, Kekilli M, Arhan M, Sayilir A, et al . Ankaferd Blood Stopper for controlling gastrointestinal bleeding due to distinct benign lesions refractory to conventional antihemorrhagic measures. *Can J Gastroenterol.* 2010;24(6):380-4.
25. Aysan E, Bektas H, Ersoz F, Sari S, Kaygusuz A, Huq GE. Ability of the ankaferd blood stopper[®] to prevent parenchymal bleeding in an experimental hepatic trauma model. *Int J Clin Exp Med.* 2010;3(3):186-91.