



Ear Candling: A Non-Proven Method for Benefits

Nee ST¹ and Athar PP^{2*}

¹Otorhinolaryngology-Head & Neck Surgery Masters Programme, KPJ University College, Malaysia

²ENT, Head & Neck, KPJ Seremban Specialist Hospital/KPJ Healthcare University College, Malaysia

Abstract

Ear candling, also known as auricular candling, "coning" or thermo-auricular therapy (TAT), is believed among most people that functions as an alternative medical practice which is believed to enhance general health. We report a 16-years old Malay male who presented with 1-week history of reduced hearing and pain over the right ear. This symptoms developed after patient went for ear candling which was claimed to soothe the head and ears and for treatment of allergic rhinitis. Otoscopy showed presence of whitish hard waxy material in the right ear canal. The nature and consistency of the foreign body in the right ear was similar to the hardened candle wax. He underwent examination under microscope under general anesthesia. Intra-operative findings showed the candle wax situated deep in the right ear canal and adhered to the tympanic membrane and the surrounding ear canal. The removal of ear wax was performed meticulously as we tried to avoid damage to the tympanic membrane. Multiple pieces of wax candle were removed from the ear canal. External auditory canal was inflamed and tympanic membrane intact. On follow up 1 week, the ear canal was normal and tympanic membrane intact. Ear candling still appeared popular and is heavily advertised although there are no proven benefits that could seem scientific to most people. We would like to highlight and emphasized this to everyone that ear candling is ineffective and potentially dangerous and we do not recommend it at any time for any reason.

Keywords: Ear candling; Wax; Auricular candling; Coning; Thermo-auricular therapy

Introduction

Ear candling, also known as auricular candling, "coning" or thermo-auricular therapy (TAT), believed among most people that functions as an alternative medical practice which is believed to enhance general health [1]. The method is done by putting the end of a hollow candle in the ear canal and lighting up the other end of it. It is also advertised for ear wax and debris removal [1].

The mechanism of action of ear candling remains unclear although there were a lot of benefits being proposed. In the literature by Kianoosh Nahid, it is said that, cerumen can be drawn out from the ear via ear candling by creating negative pressure in the ear canal. Ear candling is not scientifically proven of its effectiveness, in fact, there are a lot of associated complications [2,3]. No evidence is able to suggest the benefits of ear candling.

Here, we present a patient who came with the complication sequel to ear candling. We also would like to highlight the potential complications to this.

Case Presentation

A 16-years old Malay male presented to Ear, Nose and Throat Consultant Clinic with 1-week history of reduced hearing of right ear, not accompanied by ear discharge, giddiness, nausea/vomiting or tinnitus. There was no history of trauma or upper respiratory tract infection. On further history, patient has a history of going to traditional medications where they used candle; claimed to soothe the head and ears and for treatment of allergic rhinitis. After that, patient developed reduced hearing of right ear with minimal pain. Otherwise, he has symptoms suggestive of allergic rhinitis but no on medical treatment. He has no previous medical history and this was the first time, he experienced such a symptom.

On examination of the external ear and auricular area, there was no sign of previous surgery, inflammation or tenderness.

Otoscopy examination showed the presence of whitish hard waxy material in the right ear canal (Figure 1). The nature and consistency of the foreign body in the right ear was similar to the hardened candle wax. Attempt of removal of the foreign body material was performed with presence

OPEN ACCESS

*Correspondence:

Primuharsa Putra bin Sabir Husin Athar,
ENT, Head & Neck, KPJ Seremban
Specialist Hospital, Jalan Toman 1,
Kemayan Square, 70200 Seremban,
Negeri Sembilan, Malaysia, Tel: 06-767
7800; Fax: 06-767 5900;

E-mail: putrani@yahoo.co.uk

Received Date: 23 Jun 2016

Accepted Date: 14 Jul 2016

Published Date: 29 Aug 2016

Citation:

Nee ST, Athar PP. Ear Candling: A Non-Proven Method for Benefits. *Clin Surg*. 2016; 1: 1088.

Copyright © 2016 Athar PP. This is an open access article distributed under the Creative Commons Attribution License, which permits unrestricted use, distribution, and reproduction in any medium, provided the original work is properly cited.

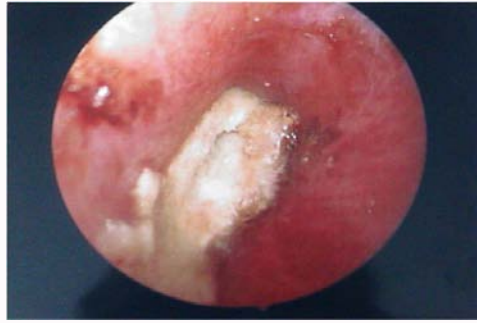

Figure 1: Otoscopic examination showing a whitish waxy material at the anteroinferior wall of the external auditory meatus and in contact with the tympanic membrane.

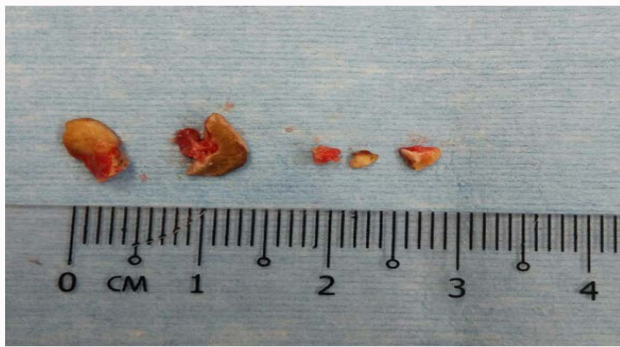


Figure 2: Hardened candle wax in piece meal after removal.

Table 1: Complications associated with Ear Candling [1].

Hot wax burn in or outside the ear
Ear canal occlusions
Tympanic membrane perforations
Secondary ear canal infections with temporary hearing loss
Otitis externa
Trauma to middle ear and ossicles

Table 2: Unproven Benefits of Ear Candling [6].

Regulate blood pressure, Improve hearing, Clear the eyes, Relieve sinusitis, Purify the mind, Reduce TMJ pain and stiffness, Cure otitis externa, Relieve vertigo, Relieve otalgia, Cleanse ear canal, Reduce tension and stress, Improve lymphatic circulation.
--

of the instruments in clinic. However, we were unable to remove the material in the outpatient clinic as the patient has severe otalgia on ear toileting. He was then scheduled for examination under the microscope under general anesthesia. Intra-operative findings showed the candle wax situated deep in the right ear canal and adhered to the tympanic membrane and the surrounding ear canal. The removal of ear wax was performed meticulously as we tried to avoid damage to the tympanic membrane. Multiple pieces of wax candle were removed from the ear canal (Figure 2). External auditory canal was inflamed and tympanic membrane intact. On follow up 1 week, the ear canal is normal and tympanic membrane intact.

Discussion

Ear candling has appeared since the ancient cultures, some have documented ear candle started back in Ancient Egypt [4]. There were

other sources which explained that ear candling was known as "ear cone" because when the cone-shaped pottery was placed into the person's ear, smoke from burning herbs will be funnelled down into the ear canal and this supposedly cleaned the ear canal and pulled the cerumen out by vacuum [5,6].

The practice of ear candling is gaining popularity owing to recent publicity. It can be performed by beauticians or even patient using the kit from home. Ear candling is dangerous and serves no purpose and there is actually no scientific evidence showing effectiveness for use.

A lot of complications have been reported with ear candling (Table 1) [1]. Seely et al. [6] documented their 21 cases of treated ear injuries associated with ear candling. There were also reports where ash remnants and residue from ear candling coating the tympanic membrane [7].

In our case report, we would like to emphasize that benefits of ear candling is not clinically proven (Table 2) [5].

Our patient went for ear candling in view he has the misconception that ear candling able to enhance general health as well as treating allergic symptoms. Furthermore, we would like to highlight the adverse effects of ear candling and create awareness amongst everyone about ear candling is ineffective and dangerous.

The treatment as a complication of ear candling is removal of the ear candle wax which occlude the ear canal meticulously to avoid injury to the surrounding structures. If otalgia still persists despite the removal attempts at the outpatient clinic, hence, this should be done under general anaesthesia for complete removal. After complete removal, a careful inspection of the ear canal for tympanic perforation, and injury to the middle ear or ossicles.

Conclusion

Finally, ear candling still appeared popular and is heavily advertised although there are no proven benefits that could seem scientific to most people. Thus, we need to create awareness to everyone that ear candling is ineffective and potentially dangerous and we do not recommend it at any time for any reason.

References

1. Nahid K, Narayanan P, Jalaluddin MA. Ear candling: A dangerous pleasure? Iranian Journal of Otorhinolaryngology. 2011; 23: 51-54.
2. Rafferty J, Tsikoudas A, Davis BC. Ear candling : Should general practitioners recommend it? Can Fam Physician. 2007; 53: 2121-2122.
3. Zackaria M, Aymat A. Ear candling: a case report. Eur J Gen Pract. 2009; 15: 168-169.
4. Ernst E. Ear candles: a triumph of ignorance over science. J Laryngol Otol. 2004; 118: 1-2.
5. Seely DR, Langman AW. Ear candles. Arch Otolaryngol Head Neck Surg. 1995; 12: 1068.
6. Seely DR, Quigley SM, Langman AW. Ear candles—efficacy and safety. Laryngoscope. 1996; 106: 1226-1229.
7. Kutz W, Fayad JN. Ear candling. Ear Nose Throat J. 2008; 87: 499.