



# Case Report of a New Mutation in MYH-Associated Polyposis

Porpiglia SA, Hall JM, Meyer EJ, Forman DA, Rybak C, Fleider FD, Cooper SH and Farma MJ\*

Fox Chase Cancer Center, Philadelphia, USA

## Abstract

MYH-associated polyposis is an autosomal recessive disorder recognized in the last 10 years. Here we describe a case with a never reported mutation in MYH gene resulting in MYH-associated polyposis.

## Introduction

Colorectal cancer is the third most common type of cancer and there were approximately 60,090 new cases in 2015 [1]. There are two common forms of hereditary colorectal cancer, familial adenomatous polyposis (FAP) and hereditary non-polyposis colorectal syndrome (HNPCC). FAP is due to mutation in the APC gene and HNPCC is caused by mutations in mismatch repair genes. These mutations in the mismatch repair genes leads to microsatellite instability; the most common genes involved are hMSH2, hMLH1, and hPMS1/2. More recently there have been new mutations identified that result in polyposis syndromes. Al-Tassan et al first described a British family with multiple colorectal adenomas and carcinomas who were found to have a G:C→T:A mutation in MYH [2]. Since then multiple biallelic mutations in MYH have been reported, but 70% of the mutations are attributed to Y179C and G396D mutations [3]. MYH-associated polyposis is an autosomal recessive disorder due to mutations in MYH also known as MUTYH [4]. MYH-associated polyposis is now considered to account for 50% of APC mutation negative polyposis [5].

MYH is a DNA glycosylase involved in the base excision repair pathway [6,7]. The importance of the base excision repair pathway is its involvement in repairing mutations caused by reactive oxygen species (ROS) [8]. One of the most common ROS is 8-oxo-7, 8-dihydroguanine (8-oxoG) which is highly mutagenic [6,7,9]. Therefore, mutations in MYH result in high levels of oxidative damage and have excessive G:C→T:A somatic transversions in the APC gene and somatic mutations in the *K-ras* gene [10-12]. Our patient has a mutation not previously described in the MYH gene.

## OPEN ACCESS

### \*Correspondence:

Jeffrey M. Farma, Fox Chase Cancer Center, 333 Cottman Avenue, Philadelphia PA 19111, USA, Tel: 215-728-2419;  
E-mail: Jeffrey.Farma@fccc.edu

Received Date: 16 Jun 2016

Accepted Date: 07 Jul 2016

Published Date: 12 Jul 2016

### Citation:

Porpiglia SA, Hall JM, Meyer EJ, Forman DA, Rybak C, Fleider FD, et al. Case Report of a New Mutation in MYH-Associated Polyposis. *Clin Surg*. 2016; 1: 1063.

Copyright © 2016 Farma MJ. This is an open access article distributed under the Creative Commons Attribution License, which permits unrestricted use, distribution, and reproduction in any medium, provided the original work is properly cited.

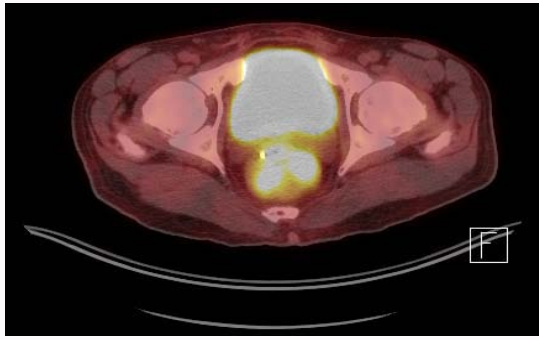
## Case Presentation

A 43 year old Egyptian man presented with a large rectal mass, identified 6 cm from the anal verge. Workup included a colonoscopy that revealed a rectal adenocarcinoma, clinically a Stage III, cTx, cN1, cM0, and more than 75 polyps throughout his colon. Immunohistochemistry (IHC) was performed on the initial biopsy demonstrating expression of MLH1, MSH2, MSH6, and PMS2. Further molecular testing revealed no mutations in the APC gene and no MYH mutations at G382D or Y165C sites. However there was novel biallelic deletion of exon 7 in the MYH gene, which has not previously been reported (Figure 1).

The patient was discussed in our multidisciplinary tumor board and consensus was to begin neoadjuvant chemoradiation therapy. The patient received infusional 5-FU with concurrent radiation which was completed in October of 2011. Following the neoadjuvant chemoradiation therapy, he underwent a laparoscopic total proctocolectomy with end ileostomy in December of 2011. The pathology showed a complete pathologic response and no malignancy was identified in 33 lymph nodes, but there were multiple tubulovillous adenomas seen throughout the specimen (Figure 2). In addition, the specimen was sent for molecular testing which revealed no mutations in the APC gene, no MYH mutation at G382D or Y165C sites, but there was a deletion of exon 7 in the MYH. The deletion of exon 7 in the MYH was a biallelic mutation. Subsequently, he received adjuvant CAPOX from February to June of 2012. His last follow up was January 2014 and there was no evidence of disease.

## Discussion

Since the initial description by Al-Tassan in 2002 [2]. Over 303 variations in MYH have been



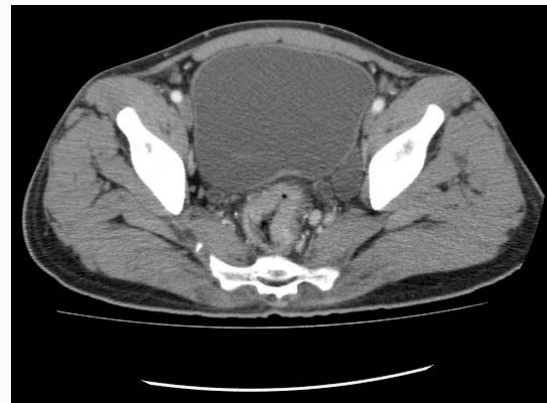**Figure 1:** Pretreatment PET/CT Scan showing the avid rectal cancer.

identified [13]. The deletion of exon 7 in the MYH gene has not previously been described. MYH mutations account for 0.4-1% of colorectal cancers [14,15]. In addition, in the literature 58-60% of patients with polyposis will have colorectal carcinoma [5,16]. Individuals with MYH associated polyposis (MAP) have between 10 and >100 polyps on age of presentation. There have been series looking at the association of phenotype and genotype. Nielson, et al published a large series of 257 patients with MAP reviewing the phenotypes and genotypes of these patients and found Y179C had more severe phenotype. One reason for this more severe phenotype is patients with mutations in G396D typically present at a mean age of 51 years compared to patients with Y179C mutations who present at a mean age of 43 years [5]. Furthermore, 15% of those with G396D mutations had more than 100 polyps and 20% had fewer than 10 polyps compared to Y179C homozygotes where 29% had more than 100 polyps and only 2% had fewer than 10 polyps [5]. Patients with MUTYH mutations are phenotypically similar to attenuated FAP (a milder form of FAP) [17]. However, patients tend to have hyperplastic and sessile serrated polyps [18].

Current screening guidelines from the National Comprehensive Cancer Network (NCCN) recommend testing for MUTYH if there is a personal history of greater than 10 adenomas, the person has known family members with biallelic MUTYH mutations, or those who meet criteria for serrated polyposis syndrome. In addition, when a person presents with polyposis APC mutations should be tested for first and then testing for the two most common northern European founder MUTYH mutations [19]. The current guidelines do not recommend screening the entire MUTYH gene, but only if one founder mutation is identified. Our patient had a homozygous deletion of exon 7 and would not have been identified by routine screening. In addition, the patient is a Coptic Christian from Egypt, a group of people with limited sequence data. The mutational analysis was performed by Myriad Genetic Laboratories. They recently reviewed their patients that had undergone genetic testing for MUTYH founder mutations and patients with colorectal cancer younger than age 50 and less than 10 adenomas. The patients screened for MUTYH founder mutations, 25% had additional MUTYH mutations identified. In addition, those screened who were younger than 50 or less than 10 adenomas, 20% had biallelic mutations that otherwise would have been categorized to monoallelic [20]. Therefore, mutations in MUTYH may be missed in patients being tested only for founder mutations.

## Conclusion

Our patient has a mutation not previously described in the MYH gene and the mutation is not routinely screened for in patients with polyposis. Here we describe a case with a mutation in MYH that



**Figure 2:** Pretreatment CT scan showing rectal cancer and prominent perirectal lymph node.

has never been reported resulting in MYH-associated polyposis. MYH-associated polyposis is now known to be a cause of colorectal cancer. Our patient had a polyposis syndrome consistent with MYH-associated polyposis and the mutation of deletion of exon 7 in MYH is a novel mutation that would have otherwise been missed if the full MUTYH was not sequenced. Therefore, in patients with a suspicion of MYH associated polyposis that test negative for APC gene should be considered for complete MYH gene analysis.

## References

1. Siegel RL, Miller KD, Jemal A. Cancer statistics, 2015. *CA Cancer J Clin.* 2015; 65: 5-29.
2. Al-Tassan N, Chmiel NH, Maynard J, Fleming N, Livingston AL, Williams GT, et al. Inherited variants of MYH associated with somatic G:C->T:A mutations in colorectal tumors. *Nat Genet.* 2002; 30: 227-232.
3. Sampson JR, Jones N. MUTYH-associated polyposis. *Best Pract Res Clin Gastroenterol.* 2009; 23: 209-218.
4. Sieber OM, Lipton L, Crabtree M, Heinimann K, Fidalgo P, Phillips RK, et al. Multiple colorectal adenomas, classic adenomatous polyposis, and germ-line mutations in MYH. *N Engl J Med.* 2003; 348: 791-799.
5. Nielsen M, Joerink-van de Beld MC, Jones N, Vogt S, Tops CM, Vasen HF, et al. Analysis of MUTYH genotypes and colorectal phenotypes in patients With MUTYH-associated polyposis. *Gastroenterology.* 2009; 136: 471-476.
6. Kim YJ, Wilson DM 3rd. Overview of base excision repair biochemistry. *Curr Mol Pharmacol.* 2012; 5: 3-13.
7. Slupphaug G, Kavli B, Krokan HE. The interacting pathways for prevention and repair of oxidative DNA damage. *Mutat Res.* 2003; 531: 231-235.
8. Lindahl T. Instability and decay of the primary structure of DNA. *Nature.* 1993; 362: 709-715.
9. Michaels ML, Cruz C, Grollman AP, Miller JH. Evidence that MutY and MutM combine to prevent mutations by an oxidatively damaged form of guanine in DNA. *Proc Natl Acad Sci U S A.* 1992; 89: 7022-7025.
10. Hucke C, MacKenzie CR, Adjobble KD, Takikawa O, Däubener W. Nitric oxide-mediated regulation of gamma interferon-induced bacteriostasis: inhibition and degradation of human indoleamine 2,3-dioxygenase. *Infect Immun.* 2004; 72: 2723-2730.
11. Lefevre JH, Rodrigue CM, Mourra N, Bennis M, Flejou JF, Parc R, et al. Implication of MYH in colorectal polyposis. *Ann Surg.* 2006; 244: 874-879.
12. Jones S, Lambert S, Williams GT, Best JM, Sampson JR, Cheadle JP. Increased frequency of the k-ras G12C mutation in MYH polyposis colorectal adenomas. *Br J Cancer.* 2004; 90: 1591-1593.

13. [www.lovd.nl/mutyh](http://www.lovd.nl/mutyh).
14. Cleary SP, Cotterchio M, Jenkins MA, Kim H, Bristow R, Green R, et al. Germline MutY human homologue mutations and colorectal cancer: a multisite case-control study. *Gastroenterology*. 2009; 136: 1251-1260.
15. Farrington SM, Tenesa A, Barnetson R, Wiltshire A, Prendergast J, Porteous M, et al. Germline susceptibility to colorectal cancer due to base-excision repair gene defects. *Am J Hum Genet*. 2005; 77: 112-119.
16. Nieuwenhuis MH, Vogt S, Jones N, Nielsen M, Hes FJ, Sampson JR, et al. Evidence for accelerated colorectal adenoma--carcinoma progression in MUTYH-associated polyposis? *Gut*. 2012; 61: 734-738.
17. Venesio T, Balsamo A, D'Agostino GV, Ranzani NG. MUTYH-associated polyposis (MAP), the syndrome implicating base excision repair in inherited predisposition to colorectal tumors. *Front Oncol*. 2012; 2: 83.
18. Boparai KS, Dekker E, Van Eeden S, Polak MM, Bartelsman JF, Mathus-Vliegen EM, et al. Hyperplastic polyps and sessile serrated adenomas as a phenotypic expression of MYH-associated polyposis. *Gastroenterology*. 2008; 135: 2014-2018.
19. National Comprehensive Cancer Network. Genetic/Familial High-Risk Assessment: Colorectal. Version 1. 2014.
20. Landon M, Ceulemans S, Saraiya DS, Strike B, Arnell C, Burbidge LA, et al. Analysis of current testing practices for biallelic MUTYH mutations in MUTYH-associated polyposis. *Clin Genet*. 2015; 87: 368-372.