



Transcatheter Mitral Valve-in-Valve Replacement: The New Frontier in Heart Valve Therapy

Schilling J and Islam AM*

Department of Medicine, Baystate Medical Center, USA

Abstract

Introduction: Surgical valve replacement is not always feasible in patients with severe mitral regurgitation from a failing bioprosthetic valve or severe mitral annular calcification. Off-label use of transcatheter aortic valves has been described in the literature as a possible method of valve replacement for this patient population. We review the literature on this practice as well as present two cases of successful implantation of the Sapien XT valve in the mitral position.

Case Series: Two patients were selected for implantation of a transcatheter valve in the mitral position due to their prohibitively high surgical risk. A transapical approach was used. One of the patients utilized venous-arterio extracorporeal mechanical oxygenation. The procedure was performed in a hybrid OR under general anesthesia. Successful implantation of both valves was achieved with survival beyond 30 days in each patient.

Discussion: There have been 113 cases of valve-in-valve and valve-in-ring procedures described in the literature. There have also been 11 cases of implantation into a native valve with severe mitral annular calcification. Both of these methods are feasible, however the architecture of the native mitral valve annulus is best suited for a dedicated mitral prosthesis. These dedicated transcatheter mitral valves are undergoing early safety and feasibility trials.

Conclusion: There has been early success with utilizing transcatheter aortic valves in the mitral position; however this practice will likely be temporary as dedicated transcatheter mitral valves progress through their development.

OPEN ACCESS

*Correspondence:

Ashequl M. Islam, Department of Medicine, Tufts University School of Medicine, Program Director, Interventional Cardiology Fellowship Baystate Medical Center, 759 Chestnut St, Room # S4652 Springfield, MA 01199, Tel: (413) 794-4492; Fax: 413-794-0198;

E-mail: Ashequl.Islam@bhs.org

Received Date: 25 May 2016

Accepted Date: 06 Jul 2016

Published Date: 11 Jul 2016

Citation:

Schilling J, Islam AM. Transcatheter Mitral Valve-in-Valve Replacement: The New Frontier in Heart Valve Therapy. *Clin Surg*. 2016; 1: 1051.

Copyright © 2016 Islam AM. This is an open access article distributed under the Creative Commons Attribution License, which permits unrestricted use, distribution, and reproduction in any medium, provided the original work is properly cited.

Introduction

Mitral valve regurgitation affects four million people and is the second most common valvular heart disease in the US [1]. In the last decade or so, transcatheter aortic valve replacement (TAVR) has become an alternative approach to surgical aortic valve replacement in high risk and inoperable patients. In the near future, this therapy will possibly be approved for intermediate risk patients. Mitral valve replacement for native or failing bioprosthetic valves has been a challenge in frail, high-risk populations. This is due to prohibitively elevated surgical risk associated with traditional valve replacement or repair. There are numerous reports of off-label transcatheter mitral valve replacement of dysfunctional bioprosthetic mitral valve prosthesis using balloon expandable transcatheter aortic valve bioprosthesis [2]. At this time there are no dedicated transcatheter mitral valves approved for use in the United States; however there are devices are currently in early feasibility and safety trials [3]. We describe two cases of successful transcatheter mitral valve-in-valve replacement with a balloon expandable Sapien XT valve (Edwards Lifesciences) using a transapical approach and review the future of transcatheter mitral valve replacement for primary mitral valve disorders.

Case Presentation

Patient selection

These procedures occurred between March and May 2015 at our single hospital center (Baystate Medical Center, Springfield, Massachusetts USA). Both valves were replaced due to bioprosthetic valve degeneration and severe mitral regurgitation resulting in NYHA Heart Failure Class II-III symptoms and severe pulmonary hypertension despite optimal medical management. These patients met criteria by the current ACC/AHA guidelines for mitral valve replacement surgery [4]. Both patients were evaluated by the multidisciplinary heart valve team and, due to prohibitively high STS risk scores, each was offered transcatheter mitral valve replacement via a trans-apical technique due to the extremely high risk associated with a traditional replacement procedure. The off-label use of the device was described to both of the patients and their families and they were in agreement to

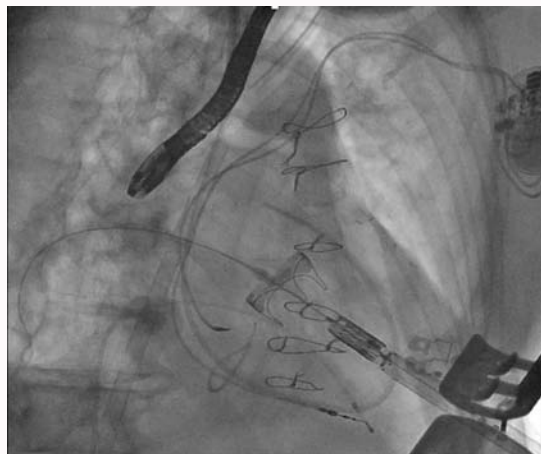


Figure 1: Transapical Delivery System Entering the Left Ventricle.

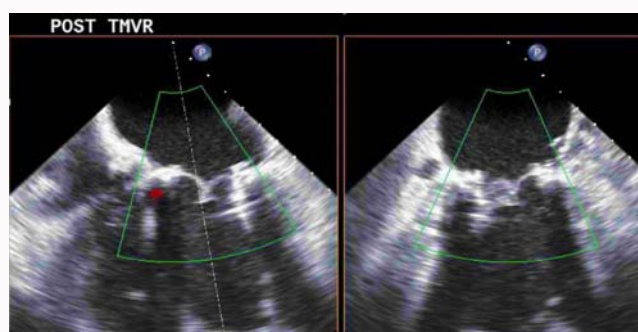


Figure 2: Post-Implantation Transesophageal Echo Showing No Paravalvular Leak.

proceed despite the risks.

The first patient was an 88 year-old male with chronic atrial fibrillation with pacemaker insertion for tachy-brady syndrome, preserved left ventricular ejection fraction, and severe mitral regurgitation due to a degenerated (#33 porcine valve) mitral valve bioprosthesis placed 11 years ago. Now he presents with Class III-IV NYHA heart failure symptoms. Coronary arteries were normal. Pulmonary artery systolic pressures were 65-70mmHg. He was deemed to be inoperable due to severe comorbidities, frailty and cachexia and a 30-day risk of surgical mortality above 12%.

The second patient was a 77 year-old female with history of bioprosthetic mitral valve replacement (#29 tissue valve) for rheumatic mitral regurgitation, tricuspid valve ring annuloplasty, CABG x2, biatrial cryomaze, and left atrial appendage ligation 18 months prior. She presented to an outside facility with recurrent NYHA Class III heart failure symptoms where cardiac catheterization showed patent grafts and a PA pressure of 70/25mmHg. Subsequently, she was transferred to our facility and was found to have severe eccentric mitral valvular regurgitation through the bioprosthetic valve with severe biventricular dysfunction. Her left ventricular ejection fraction was 30% without regional wall motion abnormalities. A malfunctioning and restricted leaflet resulting in severe eccentric mitral regurgitation was noted on the transesophageal echocardiogram. She was also felt to be inoperable. It was decided that she should be placed on transfemoral veno-arterial cardiopulmonary bypass for a short period intraoperatively as she would not likely tolerate rapid ventricular pacing required for valve placement and closure of the left



Figure 3: Novel Transcatheter Mitral Valves (Clockwise from Top Left):
Edwards Lifesciences CardiAQ Valve
Neovasc Inc. Tiara Valve
Medtronic Twelve Intrepid Valve
Abbott Tendyne Valve

ventriculotomy due to severe left and right ventricular dysfunction.

Procedure

Both procedures were performed in a hybrid operating room under general anesthesia with endotracheal intubation. Transfemoral veno-arterial cardiopulmonary bypass support was established in the second patient. Radial and pulmonary arterial pressures were measured throughout both procedures. A temporary pacing wire was advanced from the femoral vein to the right ventricular apex in both cases. During the procedure, a transesophageal echocardiogram in addition to fluoroscopy was performed for visualization of valve placement. In each case a mini thoracotomy was performed at the left fifth intercostal space in order to obtain access to the LV apex. Once the LV apex was exposed, plegets and purse-string sutures were applied prior to obtaining access. Next a left ventricular puncture was obtained using an 18G needle and a 0.035 inch J-tipped guidewire was advanced to the left atrium. In one case the wire was advanced into the right upper pulmonary vein and into the right lower pulmonary vein in the other for optimal coaxial support. Then a 5F angled glide catheter was advanced into the pulmonary vein and the guidewire was exchanged for an extra stiff 0.035 inch Amplatz guidewire. The catheter was removed with the guidewire in place across the mitral bioprosthesis and a 26F Edwards delivery sheath was advanced into the left ventricular cavity (Figure 1). In each case, a 29mm Edwards XT Sapien valve was loaded onto the delivery system. In the second case, once the valve delivery system was ready to be inserted into the left ventricle, the cardiopulmonary bypass system was started. A predetermined coplanar view as well as transesophageal echocardiography was used to confirm valve placement just 1-2 mm above the bioprosthetic ring on the left atrial side. Once advanced and in position, rapid ventricular pacing at 140 to 180 BPM was utilized to drop systolic blood pressure less than 40 mmHg during valve deployment. A trivial paravalvular leak was detected in one case and post-dilation was performed using an extra 2cc of volume in the delivery balloon. Final transesophageal echocardiographic imaging (Figure 2) was performed in both cases and the guidewire was removed. The venoarterial bypass was discontinued and the femoral artery was repaired surgically. The apical sheath was then removed

from the left ventricle using rapid ventricular pacing and the purse-string sutures were drawn for complete hemostasis. A chest tube was inserted in the left pleural cavity and the femoral catheters and sheaths were removed. One patient was extubated in the operating room and the other was extubated later that day. There was survival at 30 days for both patients and echocardiographic evaluation showed no evidence of mitral regurgitation.

Discussion

Use of a transcatheter aortic valve in the mitral position has been described in Europe since 2009 [5]. However, as more centers have adopted TAVR worldwide, off-label mitral valve replacement procedures are becoming more common. Use of the Sapien and Melody valves has been described in cases of primary degeneration of bioprosthetic valves and native mitral valves in the setting of severe mitral annular calcification (MAC). Both degenerative bioprosthetic valves (or mitral rings) and severe MAC offer a reliable and durable surface to anchor external stent of the transcatheter valve, although occasional paravalvular leaks and rare and delayed atrial migration of the transcatheter prosthesis has been described. Delivery of a transcatheter valve into a native mitral valve without MAC or a prior bioprosthesis has not been attempted due to lack of an anchoring substrate.

Two approaches are possible for placement of the valve. The first is a transapical approach, similar to that used in TAVR and as described in our patients. The second is a trans-septal approach via femoral venous access and antegrade delivery of the valve delivery system through a puncture of the interatrial septum from the left atrium into the mitral annulus. Although, the second approach is technically more demanding, it is possibly less invasive and risky in often very sick and frail patients.

Recently, a case series of these transcatheter mitral valve procedures was published as part of a larger review of both aortic and mitral valve-in-valve (or valve-in-ring) replacements. They found that a total of 113 mitral valve-in-valve and valve-in-ring replacements have been reported. Of these cases, 36% were performed trans-septally, and 64% were performed trans-apically. As in our cases, these were offered to older individuals where the re-operative risks were prohibitively high. They found an all-cause 30-day mortality rate of 8.5% and 14-month rate of 20.5%. The major non-fatal complications associated with this off-label procedure are left ventricular outflow tract (LVOT) obstruction and moderate residual paravalvular leaks. Four of the cases showed late development of valve thrombosis which may be an early signal that prolonged anticoagulation could be the preferred strategy for these patients [2].

A second procedure being performed is transcatheter valve implantation in the setting of severe mitral annular calcification (MAC). The proposed theory is that a large amount of calcification of the mitral annulus provides a ring-like scaffolding to support the valve. This procedure was first described in 2013 where a Sapien valve was implanted transapically onto a native valve. Since then, ten other cases have been reported [6]. Long-term data is unknown; however short-term feasibility and survivability have been established.

Thus far, all cases have been in the setting of primary valvular dysfunction. Though functional mitral regurgitation may benefit from this procedure, the lack of an anchoring substrate in these native valves is currently the prohibitive factor.

At this time, dedicated mitral valve prostheses are being

developed by multiple companies and are in preclinical and early clinical or feasibility trials. Early results have been mixed and continued development is needed before large-scale clinical trials can be initiated. One such valve is the Tendyne valve (Abbot). It is a trileaflet porcine pericardial valve attached to a D-shaped nitinol self-expanding frame. The valve is tethered apically to help with stability and seating. The implantation data in the first 12 patients was recently presented showing survival to discharge in all patients. Another valve is the CardiaAQ (Edwards Lifesciences) which is a bovine pericardial trileaflet valve anchoring to both the atrial and ventricular sides of the mitral annulus without exerting radial pressure. It has shown early feasibility and is enrolling subjects in an international multi-center study beginning in June 2016. A third valve is the Tiara valve (Neovasc Inc.) which uses bovine pericardial leaflets and is anchored to the atrium as well as natural valve leaflet apparatus [7]. Another valve is the Twelve valve (Medtronic) first implanted in 2015 and is undergoing a pilot study in Poland [8] (Figure 3).

Conclusion

Presently, the only widely available option for trans-catheter mitral valve replacement is the off-label use of trans-catheter aortic valve prostheses. As seen in ours and other case series, the safety, feasibility, short and intermediate-term success are quite acceptable in patients who are otherwise not surgical candidates. Valve-in-valve and valve-in-ring implantation are the most common, however traditional trans-catheter valve implantation in a native valve with severe MAC is also possible. Several trans-catheter mitral valve replacement concepts are in early clinical or feasibility trials. At the same time, several advancements have occurred in minimally invasive or less invasive mitral valve repair surgeries in the last two decades.

References

1. Iung B, Baron G, Butchart EG, Delahaye F, Gohlke-Bärwolf C, Levang OW, et al. A prospective survey of patients with valvular heart disease in Europe: The Euro Heart Survey on Valvular Heart Disease. *Eur Heart J*. 2003; 24: 1231-1243.
2. Paradis JM, Del Trigo M, Puri R, Rodes-Cabau. Transcatheter Valve-in-Valve and Valve-in-Ring for Treating Aortic and Mitral Surgical Prosthetic Dysfunction. *J Am Coll Cardiol*. 2015; 66: 2019-2037.
3. De Backer O, Piazza N, Banai S, Lutter G, Maisano F, Herrmann HC, et al. Percutaneous transcatheter mitral valve replacement: an overview of devices in preclinical and early clinical evaluation. *Circ Cardiovasc Interv*. 2014; 7: 400-409.
4. Nishimura RA, Otto CM, Bonow RO, Carabello BA, Erwin JP 3rd, Guyton RA, et al. 2014 AHA/ACC guideline for the management of patients with valvular heart disease: a report of the American College of Cardiology/American Heart Association Task Force on Practice Guidelines. *J Am Coll Cardiol*. 2014; 63: e57-185.
5. Lutter G, Quaden R, Osaki S, Hu J, Renner J, Edwards NM, et al. Off-pump transapical mitral valve replacement. *Eur J Cardiothorac Surg*. 2009; 36: 124-128.
6. Puri R, Abdul-Jawad Altisent O, del Trigo M, Campelo-Parada F, Regueiro A, Barbosa Ribeiro H, et al. Transcatheter mitral valve implantation for inoperable severely calcified native mitral valve disease: A systematic review. *Catheter Cardiovasc Interv*. 2016; 87: 540-548.
7. Preston-Maher GL, Torii R, Burriesci G. A Technical Review of Minimally Invasive Mitral Valve Replacements. *Cardiovasc Eng Technol*. 2015; 6: 174-184.
8. Figulla HR, Webb JG, Lauten A, Feldman T. The transcatheter valve technology pipeline for treatment of adult valvular heart disease. *Eur Heart J*. 2016.