



Redo Mitral Valve Surgery Via a Right Thoracotomy with Heart-Lung Machine: Presentation of Two Cases

Deser SB* and Demirag KM

Faculty of Medicine, Department of Cardiovascular Surgery, 19 Mayıs University, Turkey

Abstract

The rate of redo surgeries are increasing on account of previously performed coronary artery bypass graft surgeries, aortic/ mitral valve replacement surgeries due to valve stenosis/ regurgitation, mitral valve repair for ischemic mitral regurgitation, the aging in the population, mechanical valve thrombosis and wearing out of the mechanical valves. Resternotomy, anterolateral right thoracotomy or anterolateral left thoracotomy can be preferred for redo mitral valve surgery. Redo on pump beating heart mitral valve surgery via a anterolateral right thoracotomy is safer and reduces the injury risk of patent grafts, adherent tissues and ventricles. Here we present redo mitral valve replacement of the two patients via anterolateral right thoracotomy.

Keywords: Reoperation; Mitral valve; Thoracotomy

Introduction

The rate of redo surgeries are increasing on account of previously performed coronary artery bypass graft surgeries, aortic/ mitral valve replacement surgeries due to valve stenosis/ regurgitation, mitral valve repair for ischemic mitral regurgitation, the aging in the population, mechanical valve thrombosis and wearing out of the mechanical valves. Mitral valve surgery after previous open heart surgery is a surgical challenge. That may lead to two-threefold increase in the mortality and morbidity rather than primary surgery. Resternotomy, anterolateral right thoracotomy or anterolateral left thoracotomy can be preferred for redo mitral valve surgery. On pump standard median sternotomy approach may lead to injury of the bypass grafts or cardiac structures. History of previous mediastinitis and sternotomies, CABG with functioning grafts and previous aortic valve replacement (AVR) are the indications of thoracotomy approach. Redo on pump beating heart mitral valve surgery via a anterolateral right thoracotomy is safer and reduces the injury risk of patent grafts, adherent tissues and ventricles and also reduces the operation time, reduces amount of blood loss and improve the hemodynamics [1]. However, right pleural dissection in a redo surgery is troublesome and a surgical challenge. Injury of patent CABG such as internal mammary artery (IMA), can be fatal during reoperation via resternotomy.

Case Presentation

Case 1

A 30 years old female with dyspnea (New York Heart Association Functional Class II-III) on exertion and had a history of three times mitral valve replacement surgery, was admitted. Previous mitral valve replacement surgeries were performed 4, 6 and 8 years earlier, respectively. Transthoracic echocardiography revealed moderate mitral valve regurgitation, huge thrombus on the atrial site of the valve. Cardiac catheterization showed patent coronary arteries. European System for Cardiac Operative Risk Evaluation II was 4.05%. Routine preparation for surgery was made and informed consent was taken. External defibrillation pads were placed on the left anterior and posterior chest wall before the incision was made. Under general anesthesia with double lumen intubation, the patient was positioned with the right chest 30° elevated. A anterolateral right thoracotomy was performed through the fourth intercostal space. Cardiopulmonary bypass was initiated via right femoral artery and standard two stage venous cannulation was performed. The patient's body temperature was lowered to 25°C. Ascending aortic root cannula was placed for deairing. Cardiopulmonary bypass was performed without aortic cross-clamping which is known as the 'no-touch technique' due to severe adhesions [2]. The mean arterial perfusion pressure was maintained at over 40 mmHg during surgery in order to keep the aortic valve closed. The patient was kept in the Trendelenburg (head-down tilt) position and continuous aortic root venting was used

OPEN ACCESS

*Correspondence:

Serkan Burç Deser, Department of Cardiovascular Surgery, 19 Mayıs University, Faculty of Medicine, 55139 Samsun, Turkey, Tel: 00905395012015; Fax: 00903624576091; E-mail: sbd983@yahoo.com

Received Date: 20 May 2016

Accepted Date: 03 Jun 2016

Published Date: 08 Jun 2016

Citation:

Deser SB, Demirag KM. Redo Mitral Valve Surgery Via a Right Thoracotomy with Heart-Lung Machine: Presentation of Two Cases. *Clin Surg*. 2016; 1: 1024.

Copyright © 2016 Deser SB. This is an open access article distributed under the Creative Commons Attribution License, which permits unrestricted use, distribution, and reproduction in any medium, provided the original work is properly cited.

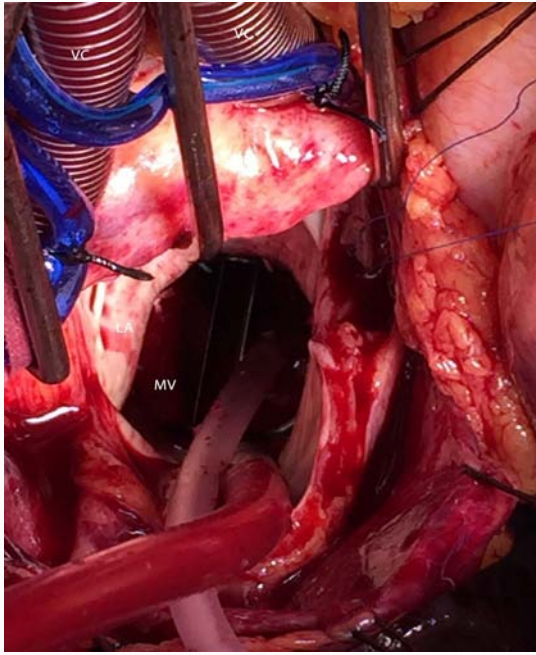


Figure 1: Perioperative view of the thrombosed previous mitral valve on the atrial site. (VC: Vena cava, RA: Right atrium, MV: Mitral Valve, AV: Aortic out Vent, LA: Left Atrium, S: Sucker, AsA: Ascending Aorta).

to prevent air embolism. A longitudinal left atriotomy incision was performed. Tracheoesophageal echocardiography (TEE) monitoring was performed during surgery due to the thrombus debris on it, previously placed mechanical heart valve was almost stucked. Prosthetic mitral valve was replaced with a 27 mm mechanical valve (St. Jude Medical Inc. St Paul, MN, USA) (Figure 1). The patient was weaned from cardiopulmonary bypass after rewarming. On post operative 43. day, respiratory infection and progressive clinical deterioration was developed that led to sepsis despite intensive antibiotic therapy, the patient progressively deteriorated and died.

Case 2

A 70 years old female presented with dyspnea on exertion (New York Heart Association Functional Class II-III) and had previously underwent coronary artery bypass graft (CABG) x2 surgery 4 years ago, was admitted. Cardiac catheterization showed patent bypass grafts. Computed tomography (CT) scan of the chest showed left internal mammarian artery (LIMA) graft courses beneathth sternum. Transthoracic echocardiography revealed severe mitral valve and moderate tricuspid valve regurgitation and the ejection fraction was 47%. European System for Cardiac Operative Risk Evaluation II was 7%. External defibrillation pads were placed on the left anterior and posterior chest wall before the incision was made. Under general anesthesia with double lumen intubation, the patient was positioned with the right chest 30° elevated. The right lung deflation was achieved. A anterolateral right thoracotomy was performed through the fourth intercostal space (Figure 2). Cardiopulmonary bypass was initiated via right femoral artery and standard two stage venous cannulation was performed. TEE monitoring was performed during surgery. Prosthetic mitral valve was replaced with a 29 mm mechanical valve (St. Jude Medical Inc, St Paul, MN, USA) (Figure 2). The patient was kept in the Trendelenburg (head-down tilt) position and continuous aortic root venting was used to prevent air embolism. Patient was weaned from cardiopulmonary bypass after rewarming. The operation was completed without any injury on the patent's

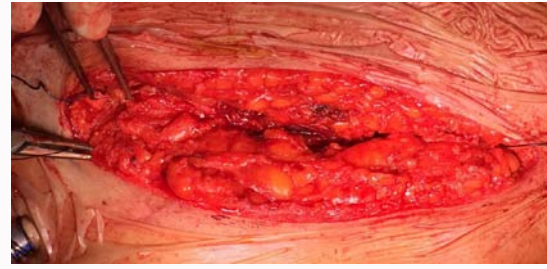

Figure 2: View of the anterolateral right thoracotomy incision.

grafts or cardiac structures and the blood loss was minimal. The heart was not fibrillated and neither aortic cross-clamping nor cardioplegia was required. The patient was discharged on post operative 5. day uneventfully.

Discussion

Mitral valve surgery in the presence of previous sternotomy is a surgical challenge. Redo procedures are technically more complex than primary operations. Lower mortality rate can be achieved with 'no touch technique' in high-risked patients with lower morbidity. During standard sternotomy technique, dissection may lead to injury of the cardiac structures [3]. Avoiding of excessive aortic manipulation and dissection reduces the risk of embolisation. Thoracotomy approach have more advantages rather than a redo sternotomy for LIMA graft that lies beneath the sternum. Retrograde arterial perfusion via femoral artery cannulation reduces the risk of adverse neurologic event. On pump beating heart surgery is superior than the hypothermic fibrillatory arrest and provides sufficient myocardial perfusion during diastole and has a threefold lower risks of stroke [4]. Also cardioplegia leads to interruption of the LIMA grafts. The right thoracotomy approach provides good exposure of the mitral valve if there is not any previous pleural adhesions [5]. Trendelenburg position, continuous aortic root venting and TEE are essential to avoid air embolism. The redo on pump beating heart mitral valve surgery provides a complete myocardial perfusion during diastole which maintains sufficient coronary perfusion to reduce myocardial ischemia and reperfusion injury [6]. Contraindications are including aortic regurgitation, right thoracic pleurodesis, low ejection fraction, multiple previous right thoracotomies, large right chest wall arteriovenous (A-V) malformation and previous right pneumonectomy [7]. In conclusion, we believe that if aortic cross-clamping can not be performed for redo surgeries, on pump beating heart mitral valve surgery via a right thoracotomy can be safely performed compared to standard sternotomy.

References

1. Petracek MR, Leacche M, Solenkova N, Hoff SJ, Absi TS, Ball Sk, et al. Minimally invasive mitral valve surgery expands the surgical options for high-risks patients. *Ann Surg.* 2011; 254: 606-611.
2. Kitamura T, Stuklis RG, Edwards J. Redo mitral valve operation via right minithoracotomy: "no touch" technique. *Int Heart J.* 2011; 52: 107-109.
3. Kim HR, Kim GS, Yoo JK, Lee JW. Minimally Invasive Approach for Redo Mitral Valve Replacement: No Aortic Cross-Clamping and No Cardioplegia. *Korean J Thorac Cardiovasc Surg.* 2015; 48: 126-128.
4. Gammie JS, Zhao Y, Peterson ED, O'Brien SM, Rankin JS, Griffith BP. J. Maxwell Chamberlain Memorial Paper for adult cardiac surgery. Less-invasive mitral valve operations: trends and outcomes from the Society of Thoracic Surgeons Adult Cardiac Surgery Database. *Ann Thorac Surg.* 2010; 90: 1401-1410.

5. Petracek MR, Leacche M, Solenkova N, Umakanthan R, Ahmad RM, Ball SK et al. Minimally Invasive Mitral Valve Surgery Expands the Surgical Options for High-Risks Patients. *Ann Surg.* 2011; 254: 606-611.
6. Uehara K, Minakata K, Funamoto M, Yamazaki K, Marui A, Sakata R. Alternative redo sternotomy in a patient with tracheostoma and patent grafts. *Asian Cardiovascular & Thoracic Annals.* 2014; 22: 852-854.
7. Parlar AI, Cicekcioglu F, Irdem AK, Hijazi A, Altinay L, Katircioglu SF. Mitral Valve Replacement with Beating Heart Technique via Right Thoracotomy in a Patient with Previous Bentall Operation. *Thorac Cardiovasc Surg.* 2010; 58: 246-248.