



Can we enhance the Accuracy of Third Window Syndrome?

Esteban-Sánchez J, Sanz R and Martín-Sanz E*

Department of Otolaryngology, University Hospital of Getafe, Toledo km. 12500 28905 Getafe (Madrid), Spain

Abstract

Introduction: Minor described a syndrome characterized by auditory and vestibular symptoms such as tinnitus, autophony and dizziness provoked by loud sounds or manipulation of auditory external canal. Diagnosis is based in computed tomography to demonstrate a dehiscence of the arcuate eminence. Recent studies show that there are radiological images of dehiscence of superior semicircular canal (SSC) but surgical findings demonstrate a thin bone cover. Many authors demonstrate that there are audiological and electrophysiological changes in VEMPs and EchoG in patients with Third Window Syndrome (TWS), which could enhance the accuracy of the diagnosis.

Material and Methods: We present a retrospective study of 30 patients (39 affected ears) of radiological dehiscence of the semicircular canal. 19 of them have clinical symptoms of TWS (clinical cohort) and 20 have just radiological evidence of the dehiscence without clinical manifestations (radiological cohort).

Both cohorts underwent a complete audiological and electrophysiological (cervical and ocular VEMPs at 500 Hz and 1000 Hz and Electrocochleography (EchoG)) studies.

Results: Presence of cervical and ocular VEMPs, elicited with 500 and 1000 Hz, were significantly greater in the clinical cohort than the radiological group. Thresholds of cVEMPs at 500 Hz and 1000 Hz and o-VEMPs at 1000 Hz are statistically significant lower in the clinical cohort. Amplitude of c-VEMPs at 500 Hz were greater in clinical cohort than the radiological one. No significant differences were found in the EchoG findings between both groups.

Conclusions: VEMPs results can help to make a better accuracy of TWS. EchoG can't differentiate patients with TWS of those with only a radiological dehiscence.

Keywords: Vertigo; Third window syndrome; Superior semicircular canal; VEMPs; Extratympanic EchoG

OPEN ACCESS

*Correspondence:

Eduardo Martín-Sanz, Department of Otolaryngology, University Hospital of Getafe, Toledo km. 12500 28905 Getafe (Madrid), Spain, Tel: 0034637532038; E-mail: emartinsanz@gmail.com

Received Date: 03 May 2016

Accepted Date: 20 May 2016

Published Date: 25 May 2016

Citation:

Esteban-Sánchez J, Sanz R, Martín-Sanz E. Can we enhance the Accuracy of Third Window Syndrome?. *Clin Surg.* 2016; 1: 1018.

Copyright © 2016 Martín-Sanz E. This is an open access article distributed under the Creative Commons Attribution License, which permits unrestricted use, distribution, and reproduction in any medium, provided the original work is properly cited.

Introduction

Minor et al. [1] in 1998 described the superior canal dehiscence (SCD) syndrome, a condition characterized by auditory and vestibular symptoms such as pulsatile tinnitus, autophony, and dizziness provoked by loud sounds or Valsalva maneuver. The presence of a SCD creates a third mobile window which allows sound or pressure-induced motion with attenuation of the perilymph flow in oval and round window [1]. The presence of this dehiscence and previously described symptoms make the diagnosis of third window syndrome (TWS). In order to diagnose SCD it is necessary to show a bony defect at the level of the arcuate eminence of the superior semicircular canal (SSC) on computed tomography (CT) [2]. Recent studies show better results using a multi-slice computed tomography (MSCT) with a cone beam protocol, consisting in an oblique parasagittal view to demonstrate the entire course of the superior semicircular canal. If the diagnosis of TWS rests only on imaging tests we could misdiagnose some patients because MSCT tends to overestimate the rate and size of dehiscences [3]. It is relatively frequent in other clinical scenarios to find a radiological dehiscence in tegmen antri, without surgical evidence of that finding [4], so prevalence of TWS in normal population is unknown. Several studies show a variable rate of dehiscence of temporal bone in cadaveric dissection from 0.7% to 8.5% [5]. To enhance the accuracy of the diagnosis, several electrophysiological tests are used to identify those patients with SCD. High sensitivity of cervical and ocular vestibular evoked myogenic potential (c-VEMPs and o-VEMPs) to detect TWS has been reported by several authors [6,7]. These authors describe abnormal larger amplitude and lower thresholds in cVEMPs and oVEMPs. Furthermore lower thresholds at 1 and 2 kHz are also described as characteristic of SCD. It is also well described that abnormalities of the cochlear summing potential (SP) are identified in inner ear disorders such as Menière's disease and perilymphatic fistula in electrocochleography (EcoG) [8]. These SP abnormalities reflect altered

electrophysiologic and/or hydrodynamic function in the inner ear in patients with SCD. Several approaches are described to repair this third window and make a resurface of the bony dehiscence such as middle cranial fosa [9] or transmastoid approach [10]. To avoid the presence of three windows an obliteration of the round window [9] is also described with good clinical response. A complete normalization of both EchoG and VEMPs parameters after the occlusion of the third window is also described [11,12]. The potential complications of surgery makes mandatory to enhance the accuracy of the diagnosis and identify properly those patients with a real dehiscence of SSC.

Objectives

The aim of this study is to describe audiometric and electrophysiological findings (cervical and ocular VEMPs and EchoG) in patients with dehiscence of superior semicircular canal. Our hypothesis is that those patients with an isolated radiological dehiscence without clinical manifestations do not accomplish the TWS. To further improve accuracy we can use complementary audio-vestibular tests like audiometry, VEMPs and EchoG.

Methods

This was a retrospective based cohort study. The subjects of this study were outpatients who first came to our Oto-Neurology or Otolaryngology Unit between January 2011 and September 2015. Patients with symptoms and/or signs of conductive hypoacusis were derived to the Otolaryngology Unit. Patients with conductive hypoacusis but with any of the following symptoms such as auditory fluctuation, Tullio's phenomenon, tinnitus, autophonia, or aural fullness were referred to the Oto-Neurology Unit. In Otolaryngology Unit, all patients underwent a complete clinical history, an audiometric test and after that a temporal bone CT scan was performed to every patient with a conductive hypoacusis. CT's technique followed predefined temporal bone protocols including axial images and multislices images of parasagittal plane for the arcuate eminence and a 3D reconstruction model. Every test was examined by the same radiologist. Those patients of the Otolaryngology Unit with a finding of dehiscence in the superior semicircular canal, were selected and constitute the radiological cohort. In the Oto-Neurology Unit, all patients underwent alike a complete clinical history, a physical examination and a complete audiometric test. Patients were asked about the occurrence of vertigo spells and every auditory symptoms as previously described. CT scan was performed to these patients with classical symptoms of TWS and a conductive hypoacusis looking for a semicircular canal dehiscence following the same protocol previously described. These patients constitute the clinical cohort. Once CT scans were indicative of SCD, every patient of both cohorts was re-evaluated and underwent a vestibular test battery consisting in 500 Hz and 1000 Hz tone burst cervical and ocular VEMPs, extratympanic EchoG and Tullio test. Patients with inconsistent or incomplete results in any of the vestibular tests performed were excluded.

Audiometry

Audiometry was performed in a soundproofed booth (IAC mini 250), and the findings were reported in pure-tone averages (PTAs), which were computed by taking the average of the four frequencies (0.5, 1, 2 and 3 kHz), and the speech discrimination score (SDS).

VEMPs

VEMPs was performed as previously reported by the authors [13], using standard BERA equipment (SmartEP' Intelligent Hearing

Systems'). To record cervical VEMPs (cVEMPs), each subject was tested while sitting down and turning their head away from the stimulated ear to contract the sternocleidomastoid muscle (SCM). The active electrode was placed on middle of the upper third of the SCM and a reference electrode was placed on the chin. The ground electrode was placed on the forehead. For the recording of ocular VEMPs (oVEMPs), the subject was sitting down, looking maximally upwards, with surface EMG electrodes. For each eye the active recording electrode was placed 1cm below the centre of each lower eyelid. The reference and ground electrode were placed on the chin and forehead, respectively. Acoustic stimuli were presented through inserted earphones. Acoustic stimuli were both 500 and 1000Hz tone bursts presented five times/second. The rise-plateau-fall time was 1-2-1. VEMP threshold and response amplitude were measured at a stimulus of 100, 90, 80, 70 and 60 dB HL. The EMG from each side was amplified and band pass filtered (10 Hz to 1.5 kHz). Results from 200 repetitions in each ear were averaged. The peak to peak amplitude (μ V) was measured for P13-N23 potentials. Complete absence of a response was considered if a response could not be determined above the noise floor. To estimate the relative response in both ears, we used the Interaural Difference (IAD) ratio, calculated as: (right ear amplitude - left ear amplitude) \div (right ear amplitude + left ear amplitude) \times 100. In our laboratory, we interpreted the VEMP results based on the absolute value of the IAD ratio from 35 normal subjects. The results revealed a mean \pm SD IAD ratio of 18.66% \pm 8.12%. A cVEMP a response was defined as abnormal when absent for only the affected ear or when the IAD ratio exceeded 50%.

EchoG

Extratympanic EchoG was performed together with audiometry and was performed by the same audiologist for all patients. The test was performed as previously reported by the authors [14], in an electrically and acoustically shielded room with the patient in the supine position. Electrocochleography was performed with standard BERA equipment (SmartEP' Intelligent Hearing Systems') with a silver wire electrode sheathed with a polyethylene tube with a hydrogel tip (Lilly TM-Wick electrode') placed on the tympanic membrane. Monaural stimuli consisting of alternating polarity clicks (99-dB normal hearing level) presented at a rate of 8.1 per second were used. Responses were averaged for 1,000 stimuli using a 10-ms time base. The evoked potential activity was band pass filtered from 5 to 1,500 Hz. The click-evoked SP amplitude was defined as the difference in the amplitude between pre-stimulus baseline and the first dip, and the AP amplitude was measured from the baseline to the first negative peak. After the identification of both points, the SP/AP ratio was calculated. The 95% upper limit for the baseline SP/AP ratio obtained from the normal control group in a previous study [14] was 0.50. Therefore, in this study, an SP/AP ratio of 0.50 or greater was considered indicative of endolymphatic hydrops.

Tullio phenomenon

For the of Tullio phenomenon testing, an audiometry was performed with the same soundproofed (IAC mini 250). Both ears were stimulated at 100 dB in 500, 1000, 2000 and 3000 Hz frequencies, while an analysis of the oculomotor responses was performed with Frenzel glasses. Symptomatic response to this stimuli and the presence of a nystagmus was considered as a positive Tullio test.

Results

30 patients (39 affected ears) were included in the present study.

Table 1: Demographic data.

Affected ear (right/left)	9/10	10/10
Age Mean (Range)	53 (40-74)	64(50-75)
Sex distribution (Men/Women)	38,5/61,5%	60%/40%
Follow up Mean LSD	6,811,6	5,711,5

Table 2: Results of presence, threshold and amplitude of cervical and ocular VEMPs with a tone burst stimuli at 500 Hz and 1000Hz.

VEMPs			Clinical cohort	Radiological Cohort	Significance
500Hz	Presence	Cervical	100%	30%	P<0,05
		Ocular	85%	10%	P<0,05
	Threshold	Cervical	75±13,42 dB	92,5±9,57	P=0,034
		Ocular	81,67±11,1 dB	100±10,2	P=0,14
Amplitude	Cervical	4,93±6,97	0,522±0,24	P=0,034	
	Ocular	2,95±1,63	0,4±0,05	P<0,051	
1000Hz	Presence	Cervical	100%	20%	P<0,001
		Ocular	85%	10%	P<0,001
	Threshold	Cervical	75,71±10,89	95±7,07	P=0,030
		Ocular	77,55±8,66	100±1,20	P=0,031
Amplitude	Cervical	1,76±0,66	0,78±0,32	P=0,056	

19 patients were included in the clinical cohort and 20 patients in the radiological cohort. Demographic data are represented in Table 1. The affected ear in clinical cohort was right and left sided in 9 and 10 cases respectively, with a mean age of 53 years (40-74). Sex distribution was 38, 5% men and 61,5% women. Mean follow up was 6, 8±1.6 years. In radiological cohort the affected ear was the right one in 10 cases and left one in another 10 cases. Mean age of 64 years (50-75) with 60% men and 40% women. Mean of follow up was 5,7±1,5 years.

Clinical results

As shown in Figure 1, in the radiological cohort, 50% of tinnitus and a 10% of patients had autophonia and same percentage for Tullio phenomenon. None of them had vertigo or dizziness, aural fullness and neither positive fistula test. In contrast, clinical cohort had a 84,6 % of presence of tinnitus, 76,9% of presence of autophonia, 69,2% of aural fullness, 53,8% of vertigo. Is founded a 38, 5% of Tullio phenomenon and 30, 8% of fistula sign in complementary examination.

Audiometric results

Mean air-conducted PTA in clinical cohort was 27, 02±10,45dB and air-conducted PTA in radiological cohort was 38, 75±14,15 dB. No significant statistical differences were observed (p=0, 29). Mean bone-conducted PTA in clinical cohort was 18, 27±10,68dB and bone-conducted PTA in radiological cohort was 30, 45±10, 95 dB. Significant statistical differences were observed (p=0,012) with a lower bone conduction threshold in clinical cohort.

VEMPs results

VEMPs results are shown in table 2. In the clinical cohort a 100% and 85% of patients of 500 Hz tone burst cVEMPs and oVEMPs, respectively had an identifiable record in the clinical cohort. Similar results for VEMPs at 1000 Hz, with a rate of 100% for cervical and 85% for ocular VEMPs. In the radiological cohort, rates of 30 and 10% respectively for cVEMPs and oVEMPs were found at 500 Hz, and 20 and 10% respectively for cervical and ocular VEMPs at 1000 Hz. The presence of both cervical and ocular VEMPs were significantly lower

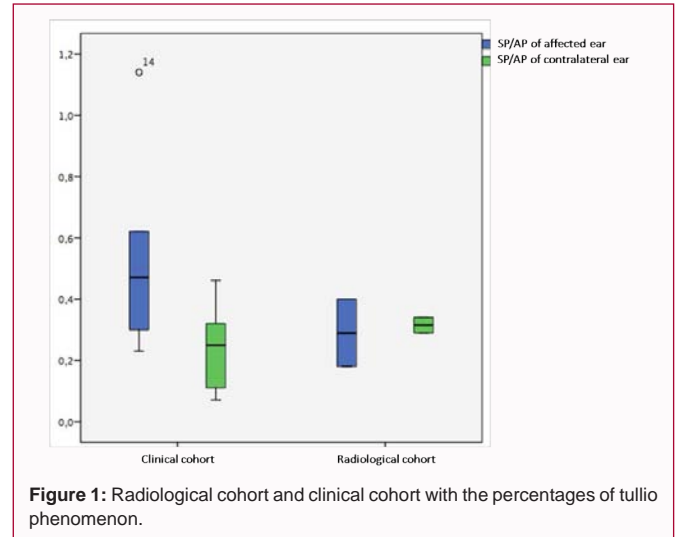


Figure 1: Radiological cohort and clinical cohort with the percentages of tullio phenomenon.

(p<0.05) in the radiological cohort. The 500 Hz cVEMPs thresholds were significantly lower (p=0,034) in the clinical cohort patients with a mean of 75±13, 42 dB, compared to radiological cohort 92, 5±9, 57. No statistical significant differences (p=0, 14) were observed in the 500 Hz oVEMPs thresholds between both clinical cohort (81, 67±11, 1dB) and radiological cohort (100±10,2dB). Similar significant differences were observed in 1000 Hz cVEMPs thresholds with a mean of 75, 71±10,89 dB in clinical cohort compared with 95±7,07dB in radiological cohort (p=0,030). Results of 1000 Hz oVEMPs thresholds also show significant differences between clinical cohort (77, 55±8,66dB) and radiological cohort 100±1,20 dB (p=0,031). Significant differences (p=0,034). Were observed in the analysis of the amplitude of the 500 Hz cVEMPs at 100 dB in clinical cohort (4, 93± 6, 97µV) compared to the radiological cohort (0, 52 ±0, 24 µV). Analysis of the 500 Hz oVEMPs amplitude 2,95±1,63 vs. 0,4±0,05 and 1000 Hz cVEMPs 1,76±0,66 vs. 0,78±0,32 did not show any significant difference between both cohorts (p=0.051 and 0.056, respectively)

Echog results

As seen in Figure 1, no statistically significant differences were observed (p=0,34), when the mean SP/AP ratio in clinical cohort (0,42±0,06) was compared to the radiological cohort (0,34±0,03). There are 4 patients (21%) in clinical cohort with a SP/AP ratio over 0, 5 and only 1 patient (5%) in radiological cohort. This is the limit in our laboratory considered as normal like we described before in material and methods. Although SP/AP ratio is nearly normal, this result in both cohorts is greater than normal population with no radiological dehiscence. These results are shown in previous publications of these authors.

Discussion

Since its initial description in 1998 many reports have described the prevalence, clinical manifestations, radiological evidence and electrophysiological findings of TWS [1]. Carey et al. [16] reported a 0,5% ratio of SSCD in a study of 1000 temporal bone dissections, and studies like Elmali et al. [15] conclude the frequency of SCD in 7% of temporal bones in a consecutive population of 850 patients with different vestibular symptoms like vertigo, deafness, and fullness. A developmental anomaly of the cranial base has been proposed as a possible cause of SCD, with the congenitally thin bone of the superior canal at risk from disruption because of trauma or pressure of the temporal lobe dura (in cases of arcuate eminence defects) [16].

Precise anatomo-physiologic explanatory model remains unclear, but manifestations can be explained by the third-window hypothesis. In this theory, the presence of a dehiscence in the superior canal creates a third mobile window in addition to the oval and round windows in the inner ear system. This window allows sound or pressure-induced motion of the stapes to produce a flow of lymph in the superior canal. The anomalous transmission may be manifested in auditory signs such as conductive hyperacusis (a normal air auditory threshold with GAP) or conductive hearing loss with preserved stapedial reflexes. The vestibular clinical signs described are a nystagmus provoked by sound or pressure changes [17]. This model fits adequately with our clinical cohort, where all patients had characteristic symptoms of SCD. On the contrary, patients in the radiological cohort, had no clinical symptoms in spite of the CT scan evidence. Recent evidence remind us the relative importance of this adjunctive information in CT scan because errors in this technique can lead to the appearance of dehiscence when thin bone still remains intact over the superior canal and is possible to perform an unnecessary surgery. There are few studies describing characteristics of patients with only a CT scan dehiscence without symptoms or with a near-dehiscence in CT scan [12,18]. Results in auditory test show a conductive hypoacusis in both groups included in this study. There is a similar air-conducted threshold in both groups but a lower bone-conducted threshold is seen in clinical cohort with a greater GAP. These findings are similar to other author's publications [20]. Our VEMPS results in the clinical cohort are comparable with other authors like Kantneer [6] or Taylor RL [7] these authors show a greater amplitude with lower thresholds in cervical and ocular VEMPs. This studies also show a greater response in those patients with SSCD when stimuly in greater frequencies like VEMPs at 1000 Hz and 2000 Hz. In our clinical cohort, a greater presence rate in cervical and ocular VEMPs at 500 Hz and 1000 Hz was observed. In the same way, thresholds were lower in clinical cohort as other authors have reported [7]. If a significant percentage of patients in the radiological cohorts had neither clinical symptoms nor characteristics VEMPs results, a false positive result of the CT scan should be suspected. Since the treatment of such condition is mainly surgical, we should take into consideration that diagnosis of TWS should not rely just in imaging techniques. Amplitude in c-VEMPs at 100 dB and 500 Hz is significative greater in clinical cohort in our population in the same way as previous publications. In case of o-VEMPs at 500 Hz and 100 dB and c-VEMPs at 1000 Hz the significance is in the limit with a $p=0,051$ and $0,058$ respectively. Probably these results are consequence of the limited number of patients included in our study. Also the chronic condition of this syndrome and the unknown inner ear dynamics tend to fluctuate as well as seen in Meniere disease. Further investigations should be made with a greater number of patients to check these results and may be in this study with more population these results will be significatives. In our study we did not find any significant differences in SP/AP ratio between patients of both clinical and radiological cohort. These results are different that those published by many authors like Adams et al. [8] or Arts et al. [19]. For example, Adams's study describe the mean of SP/AP ratio greater (0, 62) in case group vs. 0,29 in control group, but recent studies like Mehta et al. [20] describe a similar SP/AP ratio in patients with a dehiscence and patients with a thin bone over the SSC so this complementary technique cannot distinguish patients with a real dehiscence of SSC versus those with a thin bone covering the SSC. In our study, value of SP/AP ratio is greater that normal population described in previous publications of authors [14]. We have to notice that in this study there is not a control cohort with

normal patients (without dehiscence of SSC). In both groups there is a radiological finding of dehiscence of this canal, so that reason can explain the absence of significance between both groups.

Conclusions

- Only de presence of a SCD is not enough to make a diagnosis of a TWS.
- To make a diagnosis of a third window syndrome are necessary clinical manifestations
- Electrophysiological test like cervical and ocular VEMPs at 500 Hz and 1000 Hz can help us to make a better accuracy of this syndrome to not overestimate the rate of this pathology.
- EchoG does not allow us to differentiate those patients with a real TWS of those with only a radiological dehiscence.

References

1. Minor LB, Solomon D, Zinreich JS, Zee DS. Sound- and/or pressure induced vertigo due to bone dehiscence of the superior semicircular canal. *Arch Otolaryngol Head Neck Surg.* 1998; 124: 249-258.
2. Seon Bae J, Lim HW, Suk An Y, Ju Park H. Acquired Superior Semicircular Canal Dehiscence Confirmed by Sequential CT Scans. *Otology & Neurotology.* 2013; 34: 45-46.
3. Eibenberger K, Carey J, Ehtiati T, Trevino C, Dolberg J, Haslwanter T. A Novel Method of 3D Image Analysis of High-Resolution Cone Beam CT and Multi Slice CT for the Detection of Semicircular Canal Dehiscence. *Otology & Neurotology.* 2014; 35: 329-337.
4. Rogha M, Hashemi SM, Mokhtarinejad F, Eshaghian A, Dadgostar A. Comparison of Preoperative Temporal Bone CT with Intraoperative Findings in Patients with Cholesteatoma. *Iran J Otorhinolaryngol* 2014; 26: 7-12.
5. Nadgir RN, Ozonoff A, Devaiah AK, Halderman AA, Sakai O. Superior semicircular canal dehiscence: congenital or acquired condition? *AJNR Am J Neuroradiol.* 2011; 32: 947-949.
6. Kantneer C, Gürkov R. Characteristics and clinical applications of ocular vestibular evoked myogenic potentials. *Hearing Research. Hear Res.* 2012; 294: 55-63.
7. Taylor RL, Bradshaw AP, Halmagyi GM, Welgampola MS. Tuning characteristics of ocular and cervical vestibular evoked myogenic potentials in intact and dehiscent ears. *Audiol. Neurootol.* 2012; 17: 207-218.
8. Adams ME, Kileny PR, Telian SA, El-Kashlan HK, Heidenreich KD, Mannarelli GR, et al. Electrocochleography as a diagnostic and intraoperative adjunct in superior semicircular canal dehiscence syndrome. *Otol Neurotol.* 2011; 32: 1506-1512.
9. Shaia WT, Diaz RC. Evolution in surgical management of superior canal dehiscence síndrome. *Curr Opin Otolaryngol Head Neck Surg.* 2013; 21: 497-502.
10. Amodi HA, Makki FM, McNeil M, Bance M. Transmastoid resurfacing of superior semicircular canal dehiscence. *Laryngoscope.* 2011; 121: 1117-1123.
11. Wenzel A, Ward BK, Ritzl EK, Gutierrez-Hernandez S, Della Santina CC, Minor LB, et al. Intraoperative neuromonitoring for superior semicircular canal dehiscence and hearing outcomes. *Otol Neurotol.* 2015; 36: 139-145.
12. Penninger RT, Tavassolie TS, Carey JP. Cone-beam volumetric tomography for applications in the temporal bone. *Otol Neurotol* 2011; 32: 453-460.
13. Martín-Sanz E, Vargas Salamanca E, Marqués Cabrero A, Esteban J, Muerte I, Sanz-Fernández R. Value of clinical data and vestibular testing in a population of 101 patients with recurrent vestibulopathy.. *Clin Otolaryngol.* 2014; 39: 311-315.

14. Martín-Sanz E, Esteban Sánchez J, González Juliao M, Zschaecck Luzardo C, Mato Patino T, Riesco L, et al. Extratympanic electrocochleography in Ménière's disease. *Acta Otorrinolaringol Esp.* 2012; 63: 421-428.
15. Elmali M, Polat AV, Kucuk H, Atmaca S, Aksoy A. Semicircular canal dehiscence: frequency and distribution on temporal bone CT and its relationship with the clinical outcomes. *Eur J Radiol.* 2013; 82: 606-609.
16. Carey JP, Minor LB, Nager GT. Dehiscence or thinning of bone overlying the superior semicircular canal in a temporal bone survey. *Arch Otolaryngol Head Neck Surg.* 2000; 126: 137-147.
17. Minor LB, Solomon D, Zinreich JS, Zee DS. Sound- and/or pressure induced vertigo due to bone dehiscence of the superior semicircular canal. *Arch Otolaryngol Head Neck Surg.* 1998; 124: 249-258.
18. Tavassolie TS, Penninger RT, Zuniga MG, Minor LB, Carey JP. Multislice computed tomography in the diagnosis of superior canal dehiscence: how much error, and how to minimize it? *Otol Neurotol.* 2012; 33: 215-222.
19. Arts HA, Adams ME, Telian SA, El-Kashlan H, Kileny PR. Reversible electrocochleographic abnormalities in superior canal dehiscence. *Otol Neurotol.* 2009; 30: 79-86.
20. Mehta R, Klumpp ML, Spear SA, Bowen MA, Arriaga MA, Mary Ying YL. Subjective and objective findings in patients with true dehiscence versus thin bone over the superior semicircular canal. *Otol Neurotol.* 2015; 36: 289-294.