Clinics in Surgery

Case Report
Published: 10 Sep, 2020

Virtual and Surgical Reconstruction of an Unusual Midface Injury Caused by a Glider Plane Wing

*Zoltán Raskó[1], Balázs Erdőhelyi[2], Endre Varga[3] and Bertalan Dudás[4,5]**

[1]Department of Oral and Maxillofacial Surgery, University of Szeged, Hungary

[2]Department of Image Processing and Computer Graphics, University of Szeged, Hungary

[3]Department of Traumatology, University of Szeged, Hungary

[4]Lake Erie College of Osteopathic Medicine (LECOM), USA

[5]Department of Anatomy, Histology and Embryology, University of Szeged, Hungary

Abstract

Purpose: In the present study we demonstrate the surgical reconstruction of a unique midface injury caused by a glider plane accident. Additionally, we demonstrate the usefulness of an in-house developed software that allows preoperative surgical planning using three-dimensional models of the injured sites.

Methods: Reconstruction was carried out with the help of a novel virtual preoperative planning procedure developed by our team. Axial CT scans were used to generate the three-dimensional geometry of the skull and then preoperative virtual fracture repairs were performed by plate fixation using in-house developed JMed software system (TraumArt Ltd.; Department of Traumatology and Department of Image Processing and Computer Graphics, University of Szeged, Szeged, Hungary). The software is designed to render a three-dimensional model of the lesioned areas using CT images, and it allows the user to perform preoperative virtual surgical planning. According to the set parameters, surgical procedure was performed five days after the accident when facial swelling and hematoma were fully elapsed.

Results: Primary wound healing took place without infectious complications. Movements of the left eye were successfully preserved, and excellent visual acuity was recorded. No facial asymmetry was detected, and the esthetic results were fairly acceptable for the patient.

Conclusion: Our in-house developed software system appears to be an effective tool to render a three-dimensional model of the injury and test surgical options of facial reconstruction preoperatively on this model. This software may prove to be a valable asset in various surgical fields in the future.

Keywords: Maxilla; Fracture; Surgery; Three-dimensional model; Software

OPEN ACCESS

***Correspondence:**
Bertalan Dudas, Lake Erie College of Osteopathic Medicine (LECOM), 1858 West Grandview Boulevard, Erie, PA 16509, USA, Tel: 814-866-8142; Fax: 814-866-8411;
E-mail: bdudas@lecom.edu

Received Date: *29 Jul 2020*
Accepted Date*: 05 Sep 2020*
Published Date*: 10 Sep 2020*

Citation:
Raskó Z, Erdőhelyi B, Varga E, Dudás B. Virtual and Surgical Reconstruction of an Unusual Midface Injury Caused by a Glider Plane Wing. Clin Surg. 2020; 5: 2941.

Introduction

The restoration of the midface integrity after serious injury could represent a stupendous task in maxillofacial surgery. The three-dimensional feature of the bony structure of the midface demands careful preoperative planning, which is essential for the selection of the precise methodology of reconstruction [1]. Three-dimensional models rendered from Computed Tomography (CT) images are useful for preoperative planning [2,3]; however, their static nature does not support the virtual process of reassembling the individual bony fragments. The aim of this case report is twofold; we demonstrate a case of an unusual injury that has been reconstructed using a unique approach that involves a novel virtual preoperative planning procedure.

Case Presentation

A 31-year-old truck driver was admitted to the emergency department with extensive facial injuries. The patient's face was compromised by the left wing of a glider plane that missed the landing zone as the pilot attempted to regain altitude but failed in lack of upthrust (Figure 1).

Endotracheal intubation was carried out on site. Following CT scans taken in the trauma center (Figure 2), the patient was transferred directly to the operating room, where tracheostomy, initial damage control and soft tissue management were performed according to the protocols [4]

Figure 1: The site of the accident; the glider plane wing is wedged into the windshield of the truck cabin.

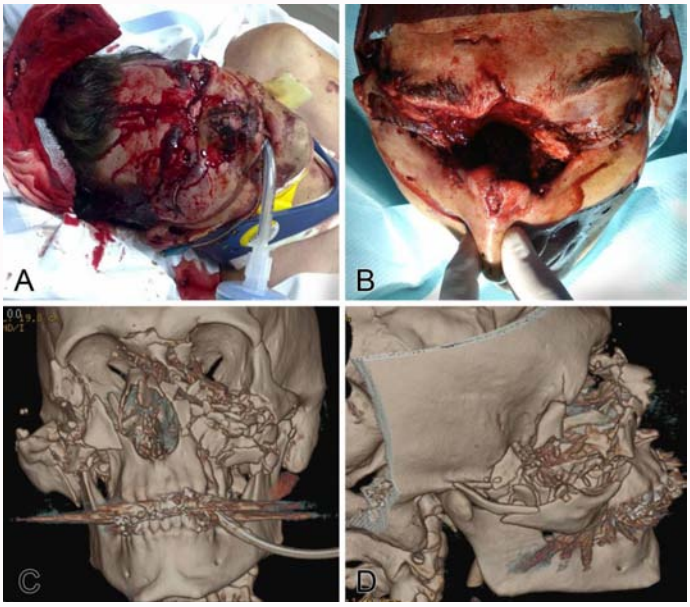

Figure 2: Extensive facial damage of the patient. (A) Initial evaluation of the patient in the CT scanner. (B) Extensive defect in the midline on the facial area with the right eye completely destroyed. (C, D) Three-dimensional CT reconstruction of the facial damage.

[4] followed by mandibulo-maxillary fixation. Since a steady point in the midline of the face could not be identified, we attached the cartilaginous part of the nasal septum to the periosteum of the frontal bone with absorbable sutures to achieve temporary stability for the mid-face (Figure 2A). Complete destruction of the right eye was noted during an ophthalmologic assessment (Figure 2B). After the initial operative phase, the patient was managed on the intensive care unit; intravenous broad-spectrum prophylactic antibiotic treatment was administered.

The classification of the patient's fractures [5] was extremely challenging due to massive fragmentation of the bones during the facial trauma. Three-dimensional CT reconstructions revealed complete destruction of the mid-face, right orbital cavity and the naso-ethmoid region (Figure 2C, 2D).

The patient was alert and responsive on the third postoperative day and reduction of facial swelling was discernible. Ophthalmology examination of the left eye was possible since it suffered significantly less trauma than the right one; eye-movements were not impeded, the patient had full field of view and intact vision. After the primary soft tissue management, no signs of infection were detected on the facial lacerations indicating that facial restoration could be planned.

First, a three-dimensional geometrical model of the fractured facial cranium was created using axial CT images taken by a LightSpeed™ 4.X multi-slice, helical CT scanner in range of 0.625 mm. Since these images were in medical imaging standard file format (DICOM), they served as an input for the JMed software system (TraumArt Ltd.) [6], developed by the Department of Traumatology and Department of Image Processing and Computer Graphics (University of Szeged, Szeged, Hungary). This software was designed with the intention of creating a three-dimensional model from the CT scans that can be used for performing preoperative virtual surgical planning. Using this approach, the bony

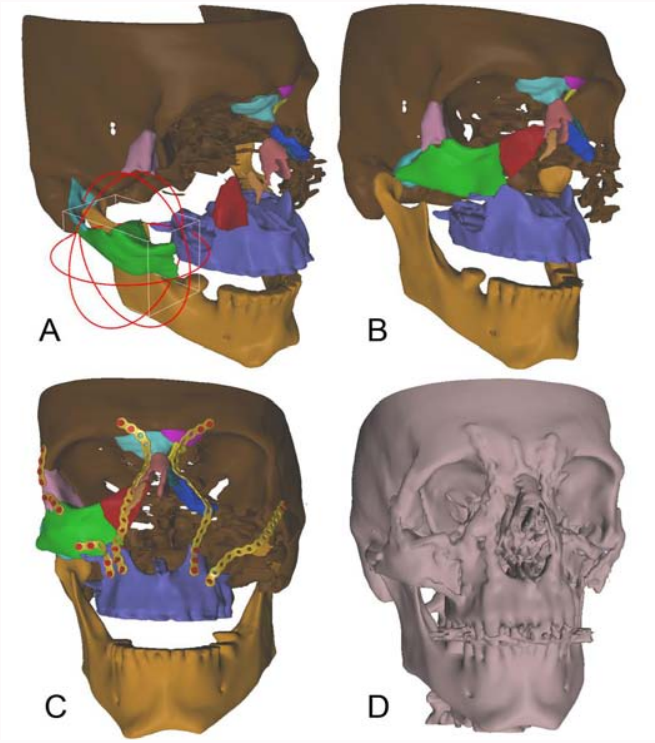

Figure 3: Preoperative planning and the results. (A) Segmented three-dimensional skull model with fragments of the midface fracture; every single fragment could be inserted in a virtual box, and moved in space. (B) Fractured fragments were assembled to achieve normal anatomical position; preformed plates were applied and stabilized by screws. (C) Preoperative plan and the subsequent (D) postoperative control show no significant difference.

fragments that were considered to be important for the integrity and stability of the mid-face were identified first followed by an anatomical reduction of the lesion by moving the fragments either one-by-one or in selected groups (Figures 3A-3C). A single major maxillary fragment was considered as an important pillar that can provide a solid point for reconstruction when attached to the supraorbital part of the frontal bone as well as to the left zygoma (Figures 3A-3C). We have decided to avoid setting plates close to the left orbit due to the risk of emerging retrobulbar hematoma and eventual blindness of the patient. Therefore, bridging mini-plates were used in this region. By setting the precise location of the plates and the holding screws, we were able to determine the best approach for exploration; nevertheless due to the extensive soft tissue trauma, additional incisions to the already existing lesions were not necessary, further decreasing the risk of subsequent soft tissue damage.

According to the virtual planning, surgical procedure was performed five days after the accident when facial swelling and hematoma were fully resolved. Mandibulo-maxillary fixation was maintained with four intermaxillary fixation screws and wire loops. Exposure of the naso-ethmoid area and insertion of the bridging plates were carried out through the initially sutured traumatic wounds. The cranial part of the maxillary fragment was exposed by intra-oral approach and the subcutaneously inserted bridging plates were secured with screws. The purpose of using the subcutaneous bridging plates was to preserve the periosteal blood supply of small comminuted bony fragments. This way the maxillary fragment was stabilized on the frontal bone extending over the naso-ethmoid area.

Fragments of the right orbital frame were oriented to outline their original anatomical position; although minor bony fragments were missing, this was necessary for appropriate secondary ophthalmologic rehabilitation. The procedure was performed through the already existing conjunctiva wound as well as *via* intraoral approach. The remains of the destroyed right eyeball and surrounding muscles were exenterated. Following the procedure, the conjunctiva socket was directly closed by sutures. The naso-ethmoid fragments were stabilized with micro-plates and screws.

Primary wound healing was documented without infectious complication. Movements of the left eye were successfully preserved. Full field of vision and excellent visual acuity was recorded during postoperative ophthalmologic examination. No facial asymmetry was detected, and the nasal dorsum appeared to be set in the midline (Figures 4A-4C). Since the crowns of the frontal and premolar teeth were damaged, complete dental rehabilitation, *i.e.* full crown restoration of the upper jaw was carried out with the result of appropriate occlusion and good esthetical features. The movements of the mandible were also adequate with painless mouth opening in 48 mm range (Figure 4D). Despite the scars over the destroyed right orbit, the esthetic results were fairly acceptable for the patient. Postoperative CT scans (Figure 3D) demonstrated excellent adherence to the preoperative plan (Figures 3A-3C).

Discussion and Conclusion

Management of the presented compound mid-face fracture is a great challenge for any maxillofacial team. Although a number of softwares that can be used to create models from three-dimensional CT scans are readily available for visualization of the fractures, these systems do not provide options to re-assemble the bone fragment virtually [7]. Since preoperative planning is crucial for successful surgery, a more interactive approach to reconstruct the lesioned area has tremendous benefits. The method we have outlined in the present study using a software developed by our institution provides a valuable

Figure 4: Postoperative results. (A-C) The patient's face one year postoperatively. Esthetic features are acceptable. (D) Occlusional state one year postoperatively.

instrument for moving the broken bony fragments virtually, either separately or in groups. This way, identification of the most important fragments of a compound fracture, as well as virtual anatomical reconstruction and mini-plate stabilization can be performed before the actual surgical intervention is carried out, decreasing the risk of postoperative complications and the necessity of changing the restorative approach during the surgery. Moreover, the three-dimensional virtual model of the preoperative plans can be made accessible in the operating room during the reconstruction, reducing the need for improvisation and decreasing intraoperative time. As we have demonstrated, the consequent functional and esthetic results using this method were excellent and readily acceptable for the patient who could return to his normal daily life.

In conclusion, the presented case could highlight the necessity of careful soft tissue management and mindful, preoperative planning for the treatment of a complex mid-face demolition. The operational technique – subcutaneously inserted bridging plates - can be considered as a unique procedure, since it is not mentioned in the literature of maxillofacial trauma treatment [8-10]. The method described in the present paper can be used for preoperative planning via virtual osteosynthesis, thus, the duration of the surgical procedure can be greatly reduced. Moreover, the technique can be also utilized for educational purposes during the training and testing of novice trauma surgeons.

Acknowledgement

JMed program was provided for preoperative planning procedure by TraumArt Ltd.

References

1. Schmelzeisen R, Schramm A. Computer-assisted reconstruction of the facial skeleton. Arch Facial Plast Surg. 2003:5(5):437.
2. Manson PN. Computed tomography use and repair of orbitozygomatic fractures. Arch Facial Plast Surg. 1999:1(1):25-6.
3. Haug RH, Pittman T. Computed tomography of head injury. Atlas Oral Maxillofac Surg Clin North Am. 2002:10(2):149-66.
4. Hochberg J, Ardenghy M, Toledo S, Ardenghy ME, Miura Y, Schiebel F. Soft tissue injuries to face and neck: Early assessment and repair. World J Surg. 2012:25(8):1023-7.
5. Manson PN, Stanwix MG, Yaremchuk MJ, Arthur JN, Hui-Chou H, Rodriguez ED. Frontobasal fractures: Anatomical classification and clinical significance. Plast Reconstr Surg. 2009:124(6):2096-106.
6. Erdőhelyi B, Varga E, Kuba A. Surgical planning tool with biomechanical simulation. Int J Comp Assist Rad Surg. 2007;2:S262-72.
7. Hohlweg-Majert B, Schön R, Schmelzeisen R, Gellrich NC, Schramm A. Navigational maxillofacial surgery using virtual models. World J Surg. 2005:29(12):1530-8.
8. Paskert JP, Manson PN, Iliff NT. Nasoethmoidal and orbital fractures. Semin Ophthalmol. 1989:4(3):148-60.
9. O'Connel DA, Futran ND. Reconstruction of the midface and maxilla. Curr Opin Otolaryngol Head Neck Surg. 2010:18(4):304-10.
10. Futran ND. Maxillofacial trauma reconstruction. Facial Plast Surg Clin North Am. 2009:17(2):239-51.