



Urgent Mitral Valve Replacement in a Patient with Multiple Peripheral Emboli due to Endocarditis

Yildirim F^{1*}, Taner Kurdal A¹, Ozturk T², Tetik O¹ and Iskesen I¹

¹Department of Cardiovascular Surgery, Celal Bayar University School of Medicine, Turkey

²Department of Anesthesiology and Reanimation, Celal Bayar University School of Medicine, Turkey

Abstract

A 45 year old male patient was operated because of acute arterial occlusion in the left leg and after that in the next day; the bilateral upper extremity arterial occlusion was developed. The patient was undergone bilateral upper extremity embolectomies and urgent mitral valve operation. He was diagnosed as acute infective endocarditis and appropriate antibiotic therapy was started. Three weeks later, he was operated because of the hemorrhagic drainage from left femoral incision due the rupture of the mycotic aneurysm. The patient was discharged without complications related to operation.

Introduction

Infective endocarditis is a life threatening infection of heart tissues and it has been defined as a clinical condition since the 1950s [1,2]. The clinical diagnosis of endocarditis needs the increased suspicion due to nonspecific clinical presentations like fever of unknown origin, fatigue, malaise, myalgia and weight loss. Embolic complications are common clinical findings of infective endocarditis and have prognostic importance for early surgical decision [3]. Here we presented a case with multiple emboli as first finding and the source was cardiac infective endocarditis tissue.

Case Presentation

In this case report we presented an infective endocarditis patient with multiple recurrent peripheral emboli; one lower extremity and both upper extremities. The patient was 45 years of age, male who had undefined fever for lasting a week. He was a worker at the medical disposal company. He was admitted to emergency service with sudden onset of pain in left lower extremity. The left femoral pulse could not be palpated; the extremity was pale, cold and painful. He was operated due to acute arterial occlusion, the embolic material was removed and the blood supply of the extremity was resumed. The patient had 3/6 systolic murmur at cardiac apex without any previous heart disease history and the other systemic examinations were normal but only fever nearly 38°C. On the next day he was examined at the echocardiography laboratory to determine the source of emboli. The echocardiography report showed moderate mitral regurgitation, mild tricuspid regurgitation and mild pulmonary hypertension measured as 30 mmHg of pulmonary artery pressure. The left ventricular end-diastolic and end-systolic diameter were 5,4 and 3,7 cm, left atrium was 3,7 cm; ejection fraction was 60%. There was a vegetative view at the left atrial side of the posterior leaflet of the mitral valve with 1,9X2,5 cm in size (Figure 1 and 2). The two blood culture samples for infective endocarditis were taken. At the night of the same day approximately 20 hours later the first embolectomy, the patient had complains of pain, coldness and color changes of both of the upper extremity simultaneously. Then we observed the loss of brachial, radial and ulnar pulses bilaterally. We performed the embolectomies under local anesthesia. Nearly 0,8X2 cm length bullet shaped, similar size embolic material were removed from right and left brachial artery consecutively. Postoperatively both of the two radial pulses were palpated. The next day urgent mitral valve operation was performed with standard mitral valve surgical procedure. The exposure of the mitral valve showed the protruded vegetation to the atrial side over the posterior leaflet (Figure 3). A1, P1, P2 anatomical areas were observed as totally destructed. Under the P1 area, there was a vegetation of 1.2x2 cm in size over the large area (Figure 4). There was no perianular abscess formation. After the removal of the diseased valve, the tissue defect over left atrium and left ventricular sides were covered by pericardial patch. The valve sutures were applied on the posterior annulus with pericardial strip. The valve with vegetations was removed and replaced by mechanical bileaflet valve (Medtronic ATS Medical, Inc 24 mm Mitral AP valve).

OPEN ACCESS

*Correspondence:

Yildirim F, Department of Cardiovascular Surgery, Celal Bayar University School of Medicine, Turkey, E-mail: fundanizamoglu@yahoo.com

Received Date: 20 May 2016

Accepted Date: 03 Jun 2016

Published Date: 09 Jun 2016

Citation:

Yildirim F, Taner Kurdal A, Ozturk T, Tetik O, Iskesen I. Urgent Mitral Valve Replacement in a Patient with Multiple Peripheral Emboli due to Endocarditis. Clin Surg. 2016; 1: 1025.

Copyright © 2016 Yildirim F. This is an open access article distributed under the Creative Commons Attribution License, which permits unrestricted use, distribution, and reproduction in any medium, provided the original work is properly cited.

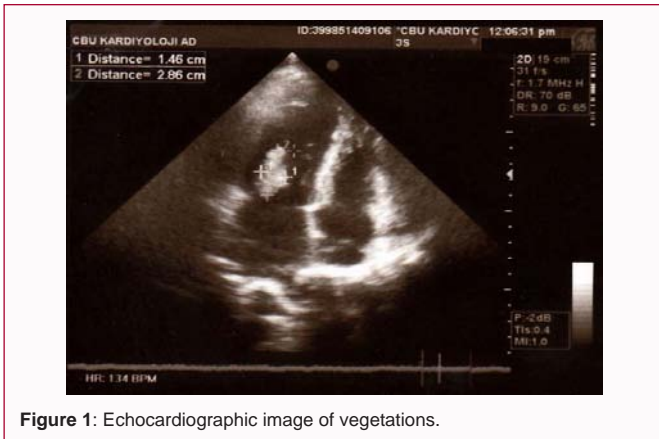

Figure 1: Echocardiographic image of vegetations.

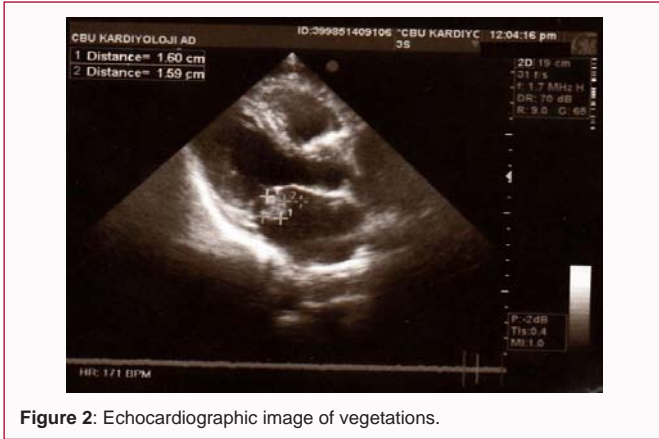

Figure 2: Echocardiographic image of vegetations.

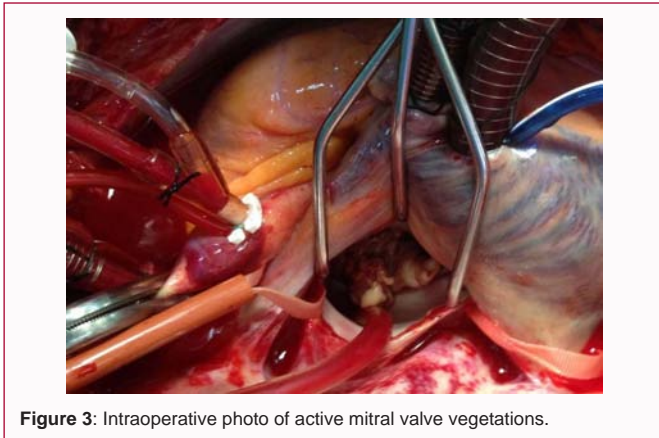


Figure 3: Intraoperative photo of active mitral valve vegetations.

The results of microbiological study was reported as Gram positive bacteria (*Staphylococcus epidermidis*) and recommended antibiotic therapy was started as vancomycin, gentamicin intravenously and rifampicin orally because the patient was working at medical disposal facility. Three-weeks later from the left lower extremity embolectomy operation there was some swelling and hemorrhagic drainage from the previous incision area at the left femoral region in the groin, then pseudoaneurysm was detected. The operation was planned under local anesthesia with the opening of previous surgical site. It was observed that approximately 5 x 8 cm sized ruptured, mycotic aneurysm in the left femoral artery. The artery was exposed and femoral embolectomy was performed proximally and distally, and continuity of circulation was maintained. The lumen of the artery was filled by fibrin and exudative material due to the nature of the mycotic aneurysm. Then the arterial defect was repaired with ipsilateral

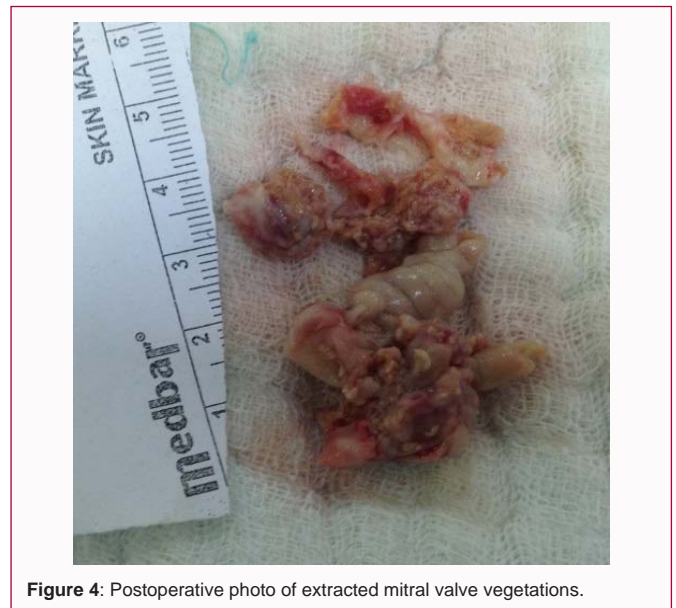

Figure 4: Postoperative photo of extracted mitral valve vegetations.

saphenous vein patch-plasty technique. The left femoral pulse was obtained in the postoperative period. The patient received antibiotic therapy for eight weeks after the valve replacement at the infectious disease clinic.

Discussion

We operated the patient with the active mitral valve endocarditis urgently because of three peripheral embolectomy interventions and also high risk of recurrent emboli that could affect the other organ systems. As in the study of Rizzi and et al, the assessment of the embolic risk in individual patient is difficult [3]. The embolic episodes were seen early in the course of the disease even before the diagnosis of infective endocarditis. The presence of large vegetation with or without previous embolism was also reported as an indication for operation in French series published by Hubert [4]. According to the Modified Duke Criteria [5] for the diagnosis of infective endocarditis, our case had one major criteria and two minor criteria. The echocardiographic finding of vegetation was one of the major criteria. Fever and multiple major arterial emboli were accepted as two minor criteria. We used mechanical bileaflet valve due to urgency of the surgery, availability of the mechanical valve and the young patient age. We did not observe any complication related to surgery.

Conclusion

In conclusion, the recurrent multiple peripheral emboli without central nervous system involvement is an important urgent surgical intervention of infective endocarditis as in our case. We recommend the operation as soon as possible to prevent the more serious embolic complications that could affect the prognosis of the disease.

References

1. Klein M, Wang A. Infective endocarditis. Journal of Intensive Care Medicine. 2014 October; 1-13.
2. Thanavaro KL, Nixon JVI. Endocarditis 2014: An update. Heart & Lung. 2014; 43: 334-337.
3. Rizzi M, Ravasio V, Carobbio A, Mattucci I, Crapis M, Stellini R, et al. Predicting the occurrence of embolic events: an analysis of 1456 episodes of infective endocarditis from the Italian Study on Endocarditis (SEI). BMC Infect Dis. 2014; 14: 230-240.

4. Hubert S, Thuny F, Resseguier N, Giorgi R, Tribouilloy C, Le Dolley Y, et al. Prediction of symptomatic embolism in infective endocarditis: construction and validation of a risk calculator in a multicenter cohort. *J Am CollCardiol.* 2013; 62: 1384–1392.
5. Nishimura AR, Otto MC, Bonow OR, Carabello AB, Erwin PJ, Guyton AR, et al. 2014 AHA/ACC Guideline for the management of patients with valvular heart disease. *J Am CollCardiol.* 2014; 63: 57-185.