Clinics in Surgery

Case Report
Published: 28 Nov, 2016

Treatment of Bilateral Iliac Aneurysms with Gore Iliac Branch Endoprostheses: Case Report and Review of the Literature

Sruthi Muluk[1]* and Naval Udgiri[2]

[1]Harvard College, USA

[2]Department of Vascular Surgery, St. Vincent Regional Health System, USA

Abstract

Introduction: Bilateral common iliac aneurysms that extend to the distal portion cannot be readily treated with standard endografts. A common strategy for unilateral iliac aneurysms is to embolize and cover the internal iliac on the side of the aneurysm, but this strategy is associated with significant side effects. The coil/cover approach is particularly undesirable for bilateral iliac aneurysms. The recent introduction of the Gore Iliac Branch Endoprosthesis (IBE) facilitates preservation of flow to the internal iliac. In this paper, we describe the first reported case of using two IBE devices to treat a patient with bilateral iliac aneurysms.

Case Presentation: A 75-year old male presented with asymptomatic bilateral common iliac aneurysms. He was treated with bilateral Gore Excluder® Iliac Branch Endoprostheses. The patient tolerated the procedure well and follow-up imaging showed no endoleak and patency of all relevant arteries.

Discussion: Bilateral common iliac aneurysms which extend to the distal iliac pose a problem because the traditional coil/cover strategy can lead to symptoms such as sexual dysfunction and buttock claudication. There are several other methods of treating this subset of aneurysms, including iliac branch devices (IBDs). The early literature on the use of IBDs is promising. This case presentation demonstrates that bilateral IBDs can be successfully used in patients with suitable anatomy.

Keywords: Bilateral iliac aneurysms; Endoprostheses; Chronic warfarin therapy; Iliac aneurysms (IA)

OPEN ACCESS

****Correspondence:***

Sruthi Muluk, Harvard College, 294 Dunster Mail CTR, 945 Memorial Drive Cambridge, MA 02138-7544, USA, Tel: 724-513-6541, (412) 359-3714; E-mail: sruthimuluk@college.harvard.edu

Received Date: *29 Aug 2016*
Accepted Date*: 08 Nov 2016*
Published Date*: 28 Nov 2016*

Citation:

Muluk S, Udgiri N. Treatment of Bilateral Iliac Aneurysms with Gore Iliac Branch Endoprostheses: Case Report and Review of the Literature. Clin Surg. 2016; 1: 1179.

Introduction

Bilateral common iliac aneurysms that extend to the distal portion cannot be readily treated with standard endografts. A common strategy for unilateral iliac aneurysms is to embolize and cover the internal iliac on the side of the aneurysm, but this strategy is associated with significant side effects. The coil/cover approach is particularly undesirable for bilateral iliac aneurysms. The recent introduction of the Gore Iliac Branch Endoprosthesis (IBE) facilitates preservation of flow to the internal iliac. In this paper, we describe the first reported case of using two IBE devices to treat a patient with bilateral iliac aneurysms.

Case Presentation

A 75-year-old male presented with asymptomatic bilateral common iliac aneurysms, which were discovered incidentally during workup for bladder infection. The patient had a history of obesity, stroke, myocardial infarction, and severe congestive heart failure. He had an automatic internal cardiac defibrillator (AICD) placement and was on chronic warfarin therapy. On exam, his abdomen was obese. His iliac aneurysms were not palpable. He had strong femoral pulses, and his lower extremities were well perfused. His CT angiogram demonstrated a small aortic aneurysm, a 4.2 cm left common iliac aneurysm (CIA), and a 2.3 cm right CIA which extended into the internal iliac (Figure 1A and 1B). The internal iliac aneurysm measured 3.1 cm. The patient was deemed to be too high risk for open repair. Rather than sacrifice either internal iliac, we proceeded with bilateral iliac branch endograft repair using two Gore Excluder® Iliac Branch Endoprostheses (IBE). The Gore IBE is indicated to be used in conjunction with the Gore Excluder aortic device. The IBE is designed to mate with the aortic device to achieve full exclusion of both the aortic and iliac

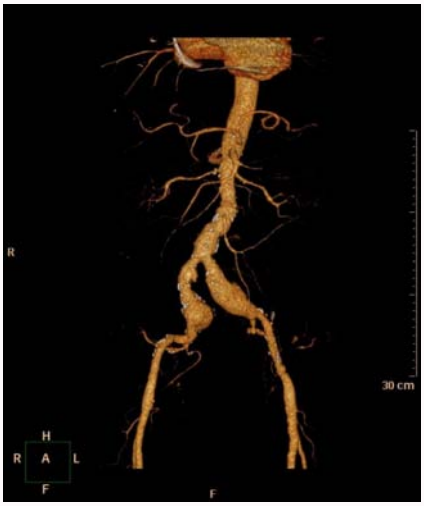

Figure 1A: 3-D reconstruction of aortoiliac segment depicting bilateral iliac aneurysms.

Figure 1B: Rotated 3-D reconstruction showing extension of the right common iliac aneurysm into the internal iliac.

aneurysmal components.

Bilateral percutaneous femoral access was achieved. The Gore IBE has a two-wire system, one for the center channel and another which was pre-cannulated through the iliac branch gate. Both wires were passed through the left femoral artery into the common iliac, using a 16-FrenchGore Dryseal® sheath. The pre-cannulated wire was snared from the right groin, following which the IBE device was passed into the left common iliac (Figure 2A, 2B and 2C). The IBE was partially deployed to expose its main body and the internal iliac gate (Figure 2D). Following this, with the crossing wire held under tension, a 12-French sheath was passed from the right side into the internal iliac gate (Figure 2D and 2E). The left internal iliac was then cannulated and the internal iliac stent-graft deployed (Figure 2F and 2G). The crossing 12-French sheath was then removed (Figure 2H). The mirror-image process was carried out on the right side, taking care to ensure a seal beyond the right internal iliac aneurysm. At this time, we noted that the left internal iliac stent-graft had migrated distally (Figure 3A), reducing the seal zone in the gate. For this reason, we re-accessed the left IBE from the right and placed a second

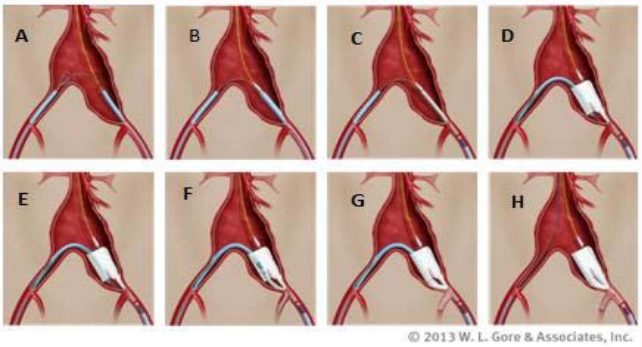

Figure 2: Step-by-step deployment of the Gore IBE. See text for further details on each panel.

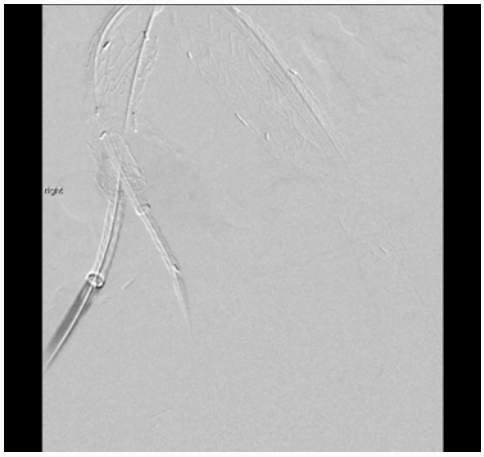

Figure 3A: Fluoroscopic image showing the gap between the left internal iliac stent-graft and the IBE gate.

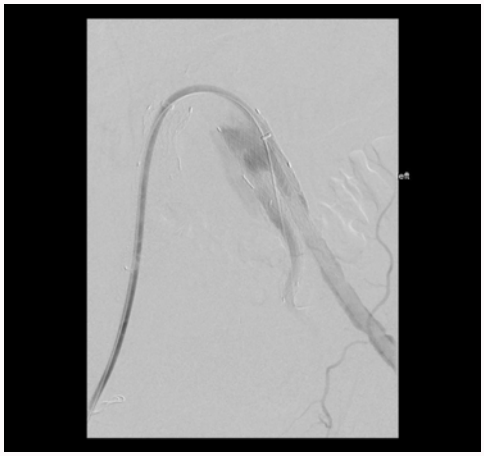

Figure 3B: Fluoroscopic image depicting repeat cannulation of left internal iliac prior to deployment of the second stent-graft.

internal iliac stent-graft (Figure 3B). Once the IBEs were in place, a standard Gore aortic endograft was deployed just below the left renal artery (the lower of the two). Right and left bridge pieces connecting the aortic endograft to the IBEs were then deployed. An angiogram demonstrated a successful outcome, with wide patency of both renal arteries and both internal iliacs, with no endoleak (Figure 4). The patient tolerated the procedure well. Follow-up imaging showed that the grafts were patent with no endoleak present (Figure 5A and 5B).

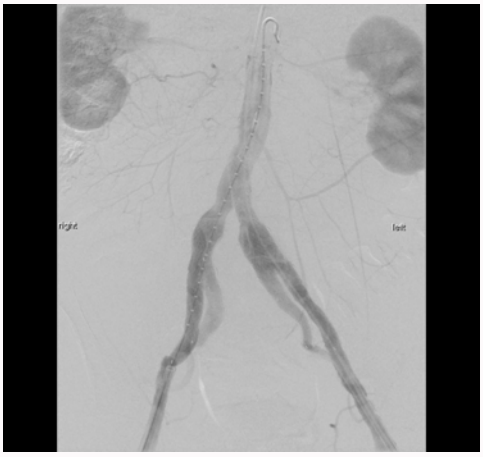

Figure 4: Completion angiogram demonstrating patency of both renal arteries and both internal iliacs.

Figure 5A: One-month follow-up axial CTA image showing the common iliac arteries. No endoleak is observed.

Figure 5B: One-month follow-up axial CTA image showing patent right and left external and internal iliac stent-grafts.

Discussion

Iliac aneurysms (IA), either bilateral or unilateral, appear along with abdominal aortic aneurysms (AAA) in 20-30% of patients [1]. In cases where the aneurysm reaches the distal portion of the common iliac, a traditional stent-graft is not an option as there is no location for adequate seal within the common iliac.

One solution to this problem is to extend the graft into the external iliac artery. This requires embolization of the internal iliac to prevent Type II endoleak, and it effectively cuts off blood flow to the internal iliac artery. Blocking the internal iliac can have adverse effects such as buttock claudication and sexual dysfunction. Sexual dysfunction can affect 15-60% of patients with unilateral internal iliac coverage and 80% of patients with bilateral coverage [2]. Buttock claudication was found to occur in 28-38% of patients on the side of embolization [3,4]. Many surgeons have adopted the approach that the embolization/cover strategy is acceptable if it can be limited to one side. However, even unilateral internal iliac coverage is not free of morbidity.

Another option is open surgery. Quite often, however, patients, such as the one discussed in this case report, have substantial comorbidities which make open surgery too risky. The other option is to perform an endovascular procedure that includes revascularization of the internal iliac. There are a few options when it comes to such revascularization. First, a surgical bypass that connects the external iliac to the internal iliac can be performed prior to the graft placement. This can be a difficult operation and is only rarely used. A second option is the "sandwich technique," [5] in which side-by-side grafts are placed into the external and internal iliac arteries. This method generally requires arm access for placement of the internal iliac graft, although contralateral femoral access may suffice for certain aortic endografts such as the AFX graft made by Endologix. Moreover, the sandwich technique can be problematic because of gutter leak. A final option, discussed in this case report, is a branched iliac graft, whether "home-made" or commercial. This option preserves internal iliac flow without requiring arm access or risk of gutter leak. However, home-made grafts are off-label and difficult to construct, while commercial iliac branched devices (IBDs) can be expensive, especially for bilateral CIAs.

IBD configurations have been classified as straight, helical, or bifurcated-bifurcated [6]. Multiple studies have found that current-generation IBDs can be implanted with success rates ranging from 75-100% [1,7-12]. It is apparent that results have improved over time with better device design [1,13,14]. Early published results using the Gore IBE, which was only recently approved by the FDA, have demonstrated excellent outcomes among carefully selected patients, with technical success of 93-95% and low morbidity [4,12].

However, there is still room for improvement in device design. According to Gray et al. [15], more than 40% of iliac aneurysms would not be amenable to therapy with the Cook Zenith Iliac Side Branch Stent Graft. Pearce et al. [16] found that only 35% of common iliac aneurysms would be eligible for Cook and Gore devices, based on their "Instructions for Use". The major reason for exclusion was the internal iliac landing zone. IBD design must be enhanced to allow for shorter and more diseased landing zones.

Branch devices can be used for unilateral or bilateral iliac aneurysms. The few studies which investigated bilateral iliac aneurysms revealed that the IBDs can be effective in this condition [11,17-19]. One study mentioned the need to place a graft in a healthy aorta in order to support the IBD. The authors expressed hope that new IBDs would be developed which would be able to stand on their own in the iliac artery [20].

Conclusion

To our knowledge, no study has previously reported the use of bilateral Gore Excluder® IBE devices. The current case report demonstrates that in patients with suitable anatomy, bilateral IBEs can be deployed with good technical and clinical success. More study and literature will help to further reinforce this conclusion.

References

1. Malina M, Dirven M, Sonesson B, Resch T, Dias N, Ivancev K. Feasibility

of a branched stent-graft in common iliac artery aneurysms. J Endovasc Ther. 2006; 13: 496-500.

2. Ghosh J, Murray D, Paravastu S, Farquharson F, Walker MG, Serracino-Inglott F. Contemporary Management of Aorto-iliac Aneurysms in the Endovascular Era. Euro J Vasc Endovasc Surg. 2009; 37: 182-188.

3. Taudorf M, Gronvall J, Schroeder TV, Lonn L. Endovascular Aneurysm Repair Treatment of Aortoiliac Aneurysms: Can Iliac Branched Devices Prevent Gluteal Claudication? J Vasc Interv Radiol. 2016; 27: 174-180.

4. Schneider DB, Matsumura J, Oderich GS, Lee JT, Peterson BG. SS27. Pivotal Results for the Gore Excluder Iliac Branch Endoprosthesis for Treatment of Aortoiliac Aneurysms in the IBE 12-04 Prospective, Multicenter Study. J Vasc Surg. 2016; 63: 226S-227S.

5. Lobato AC, Camacho-Lobato L. The sandwich technique to treat complex aortoiliac or isolated iliac aneurysms: results of midterm follow-up. J Vasc Surg. 2013; 57: 26S-34S.

6. Oderich GS, Greenberg RK. Endovascular iliac branch devices for iliac aneurysms. Perspect Vasc Surg Endovasc Ther. 2011; 23: 166-172.

7. Karthikesalingam A, Parmar J, Cousins C, Hayes PD, Varty K, Boyle JR. Midterm results from internal iliac artery branched endovascular stent grafts. Vasc Endovascular Surg. 2010; 44: 179-183.

8. Haulon S, Greenberg RK, Pfaff K, Francis C, Koussa M, West K. Branched grafting for aortoiliac aneurysms. Eur J Vasc Endovasc Surg. 2007; 33: 567-574.

9. Greenberg RK, West K, Pfaff K, Foster J, Skender D, Haulon S, et al. Beyond the aortic bifurcation: branched endovascular grafts for thoracoabdominal and aortoiliac aneurysms. J Vasc Surg. 2006; 43: 879-886.

10. Parlani G, Verzini F, De Rango P, Brambilla D, Coscarella C, Ferrer C, et al. Long-term results of iliac aneurysm repair with iliac branched endograft: a 5-year experience on 100 consecutive cases. Eur J Vasc Endovasc Surg. 2012; 43: 287-292.

11. Loth AG, Rouhani G, Gafoor SA, Sievert H, Stelter WJ. Treatment of iliac artery bifurcation aneurysms with the second-generation straight iliac bifurcated device. J Vasc Surg. 2015; 62: 1168-1175.

12. Schonhofer S, Mansour R, Ghotbi R. Initial results of the management of aortoiliac aneurysms with GORE(R) Excluder(R) Iliac Branched Endoprosthesis. J cardiovasc surg. 2015; 56: 883-888.

13. Karthikesalingam A, Hinchliffe RJ, Holt PJ, Boyle JR, Loftus IM, Thompson MM. Endovascular aneurysm repair with preservation of the internal iliac artery using the iliac branch graft device. Eur J Vasc Endovasc Surg. 2010; 39: 285-294.

14. Paraskevas KI, Mollendorf C, Fernandes E, Fernandes R, Tielliu IF, Verhoeven EL. EVAR for aortoiliac aneurysms, including iliac branched grafts. J cardiovasc surg. 2012; 53: 67-72.

15. Gray D, Shahverdyan R, Jakobs C, Brunkwall J, Gawenda M. Endovascular aneurysm repair of aortoiliac aneurysms with an iliac side-branched stent graft: studying the morphological applicability of the Cook device. Eur J Vasc Endovasc Surg. 2015; 49: 283-288.

16. Pearce BJ, Varu VN, Glocker R, Novak Z, Jordan WD, Lee JT. Anatomic suitability of aortoiliac aneurysms for next generation branched systems. Ann Vasc Surg. 2015; 29: 69-75.

17. Ferreira M, Monteiro M, Lanziotti L. Technical aspects and midterm patency of iliac branched devices. J Vasc Surg. 2010; 51: 545-550.

18. Kim JT, Jeon YS, Lim HK, Kim YS, Yoon YH, Baek WK. Endovascular Treatment of Isolated Bilateral Common Iliac Artery Aneurysms Using Iliac Branched Stent Graft. Vasc Specialist Int. 2014; 30: 87-90.

19. You JH, Park HK, Park CB. Endovascular repair of bilateral iliac artery aneurysm with branched iliac stents: case report and review of the current literature. J Korean Surg Soc. 2013; 85: 145-148.

20. Kassaian SE, Abbasi K, Al-Sibaie AA. Endovascular treatment of isolated bilateral internal iliac artery aneurysms with a branched endograft: a case report. J Tehran Heart Cent. 2013; 8: 116-118.