



# Through Knee Amputation: A Neglected Alternative to above Knee Amputation

Bergman H\* and Metcalfe M

Department of Plastic Surgery, University Hospitals Birmingham NHS Foundation Trust, UK

## Abstract

Lower limb amputation is a major, life-changing procedure associated with high levels of morbidity and mortality. The care surrounding an amputation requires a thoroughly planned MDT approach, with careful consideration of pre-operative medical, surgical and functional optimization. Planning needs to be individualized to each patient and must include their functional needs and capacity for rehabilitation. In modern practice, lower limb amputations are most commonly performed at the Below-Knee (BKA) or Above Knee (AKA) level. Despite well documented functional benefits over AKA, the lesser known Through-Knee Amputation (TKA) seems to have fallen out of favor with vascular surgeons, comprising less than 2% of major lower limb amputations.

## Introduction

Despite being a life-saving intervention dating back to the 17<sup>th</sup> Century, most literature focuses on either trauma or malignancy [1,2], instead of the two most common causative pathologies - peripheral vascular disease and diabetes mellitus [3]. Patients with these conditions carry significant residual co-morbidity, high mortality risk, have statistically poorer social support and often engage in unhealthy lifestyle choices [4]. All of these factors negatively impact their chances of successful rehabilitation [5]. Therefore, these patients are likely to have poorer outcomes than those of the general civilian or military population used in much of the trauma-based literature [5].

This paper aims to review the literature; discussing appropriate patient selection for TKA and AKA and evaluating their medical and functional outcomes. Additionally, it will compare modern variations in surgical TKA technique and present our own modification - the Condylar sparing method.

## OPEN ACCESS

### \*Correspondence:

Henry Bergman, Department of Plastic Surgery, University Hospitals Birmingham NHS Foundation Trust, Birmingham, UK,  
E-mail: [henry.bergman@nhs.net](mailto:henry.bergman@nhs.net)

Received Date: 16 Nov 2020

Accepted Date: 08 Dec 2020

Published Date: 18 Dec 2020

### Citation:

Bergman H, Metcalfe M. Through Knee Amputation: A Neglected Alternative to above Knee Amputation. *Clin Surg*. 2020; 5: 3020.

Copyright © 2020 Bergman H. This is an open access article distributed under the Creative Commons Attribution License, which permits unrestricted use, distribution, and reproduction in any medium, provided the original work is properly cited.

## Mechanical Advantages

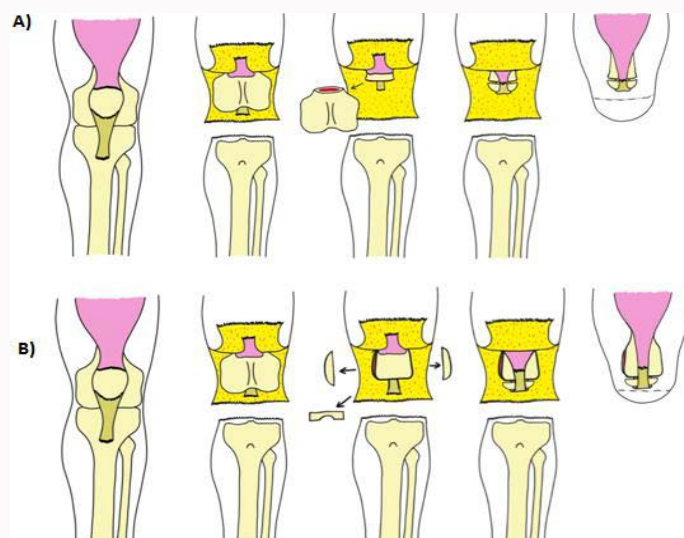
A TKA has functional superiority compared to the AKA in both ambulatory and non-ambulatory cohorts. Practically, the intact femur provides a full weight bearing surface to ambulate on [6,7]. Furthermore, the large surface area of the intact femoral condyles prevents prosthesis related skin damage by allowing even distribution of pressure [6,7]. Preservation of the adductor musculature maintains greater power, reduces the energy expenditure of ambulation, and provides valuable proprioceptive function [6,7]. Compared to an AKA the process of fitting a prosthesis is simplified, with no need for the complex strapping or belt fitting requiring to attach an AKA prosthesis [6]. For the non-ambulatory patient, the extra length and weight awarded by the TKA provides valuable counter-balance when sitting and a powerful lever to assist in transferring [8].

In contrast, the only mechanical benefit of an AKA over a TKA is the greater physical space provided by removing part of the distal femur. This allows for better alignment and rotation of the prosthesis - essentially allowing a prosthetic knee joint to sit at the same level as the contralateral side, and allows for the use of shock-absorbing attachments [6,7].

## Concerns

Despite its well documented mechanical advantages, the through knee amputation remains cautiously utilized in most centers. Concerns typically surround poor wound healing [1,6], failure in rehabilitation, general mortality and morbidity and rate of revision to AKA.

Multiple individual studies, literature reviews and meta-analyses exist documenting the progressive loss of function as the level of amputation becomes more proximal [9-13]. BKA patients have a greater chance and greater quality of full rehabilitation in nearly all cases - except in those where the residual tibial stump is too short to provide an effective knee lever [2].



**Figure 1:** Alternative methods of through-knee amputation;

**A:** Minimal supracondylar amputation; the knee joint is opened via a traditional anterior and posterior flap; the femoral condyles fully excised and the patella fixed to the femoral stump to create a new articular surface. The quadriceps tendon is fixed to the posterior cruciate ligament, and soft tissue envelope closed with a transverse anterior scar.

**B:** Condylar shave modification; the knee joint is opened via a traditional anterior and posterior flap; the femoral condyles are excised and epiphysis shortened to create a 'box' stump. The quadriceps tendon is fixed to the posterior cruciate ligament and, soft tissue envelope closed with a transverse anterior scar.

Compared to an AKA, more patients with a TKA were able to walk 500 meters [14], had greater documented daily usage of a prosthesis (76% compared to 50%) [15], lower rates of no prosthesis use (12% compared to 39%) [15], and greater rates of satisfaction with rehabilitation (62% compared to 33%) [16]. However, despite this, physician rated satisfaction with rehabilitation remains low [2] the precise reason for this is unclear. Traditional TKA stumps (with bulky femoral condyles) are consistently found to have poorer patient rated cosmesis [16]; however, with modern modifications in technique this is possible to improve [6].

Return to theatre rate remains a concern for many clinicians, with TKA requiring revision in 9% to 27.9% of cases compared to 5% to 12.4% of cases of AKA [6,9,17-20]. There was consistently no significant difference reported in the level of mortality between AKA and TKA patients [17,18]; even when accounting for the higher rate of return to theatre. Neither TKA, nor return to theatre was independent risk factors for mortality [17,18]. There was variability in the amount of post-op pain reported: with the large LEAP trial indicating no difference between AKA, TKA and BKA [2], while a similarly large meta-analysis indicated TKA patients had significantly more pain than those with an AKA [14]. Other post-operative complications such as cardiopulmonary or genitourinary complications were comparable between TKA and AKA [17].

Specifically reported rates of wound complication (Infection or dehiscence) were variable, with 71% to 81% of wounds healing by primary intention [6,9,10,19-21]. Although within the acceptable range [6], these numbers are thought to be disproportionately high due to the long posterior flap traditionally used for the tissue envelope in TKA.

## Surgical Advantages and Modifications

Through-knee amputation typically consists of surgical disarticulation of the knee joint with ligation of the popliteal vessels and sciatic nerve [22]. Crucially, there is maintenance of the adductor and quadriceps muscle groups and formation of a long posterior

soft tissue envelope for closure of the stump [22]. This procedure has technical advantages over BKA and AKA in that it is relatively atraumatic, incurs minimal blood loss and potentially requires no cutting of muscle and bone [21,22]. Additionally it is quicker and easier to perform, potentially being a more accessible option to the more junior surgeon. In complex amputations where the patient may have undergone prior Orthopedic intervention; this avoids the need to remove or divide intra-medullary nails or metallic plating.

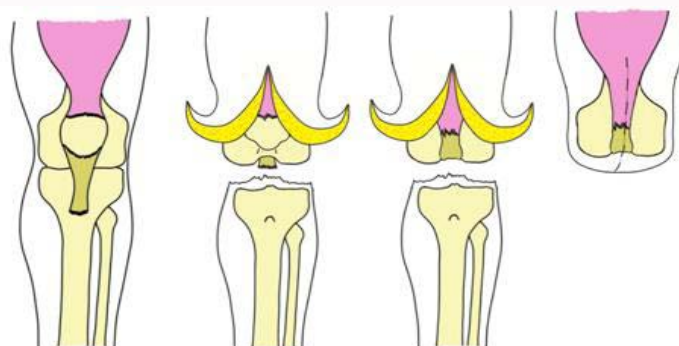
Multiple modifications exist, aiming to improve stump cosmesis and use of a functional prosthesis [23]. These typically require shaving or complete excision of the femoral condyles 10 or minimal supracondylar amputation [8,24], with formation of a new weight bearing femoral epiphysis using the discarded patella. All of these modifications incur greater trauma, blood loss, operating time, surgical training and expense. These variations are summarized in the figure below (Figure 1).

In our vascular unit (Lister Hospital - Stevenage) a through-knee amputation is performed with a modified incision running anterior to posterior - similar to that of a Skew flap. No bone or muscle cutting is performed, and the knee is disarticulated - discarding the patella and fixing the quadriceps tendon to the Posterior collateral ligament. This method of closure requires no long posterior flap vulnerable to ischaemia [1] - a key disadvantage of other described variations (Figure 2).

## Careful Patient Selection

Given the benefits and risks of TKA discussed above, careful patient selection may be able to identify those most likely to benefit and spare those likely to fail.

Taylor et al. described a list of factors likely to impact negatively on rehabilitation [5]; pre-operative poor ambulation (10x RR of failure) being the most significant alongside increasing age over 60 (RR 2.7), dementia, end-stage renal failure and advanced coronary artery disease (RR: 2) [5]. These factors; particularly advanced coronary



**Figure 2:** Condylar sparing modification of through-knee amputation – performed at Lister Hospita.

artery disease and vascular dementia; are common to most patients with significant peripheral vascular disease. Similarly, diabetes mellitus is the most common cause of end-stage renal failure in the UK. This paper goes on to suggest, perhaps dramatically, that such high-risk patients would be better served by a palliative primary AKA than a TKA [5]. Additionally, advancing age and peripheral vascular disease were found to be negatively predictive of wound healing [1] - attributed to the vulnerable long skin flaps of the traditional TKA method.

Patient co-morbidities are the best described predictor of morbidity and mortality - important for their global recovery and survival, not just their functional outcomes as described by Taylor et al. They may reflect these patients' poor fitness for surgery in general.

It may not necessarily be true that patients who are unlikely to fully ambulate with prosthesis require a palliative AKA. Indeed, other authors regard TKA as the treatment of choice in this scenario [6,8,25]; incurring reduced physiological burden of surgery and superior sitting and transferring support [25].

## Discussion

On review, it would seem that the functional advantages of the TKA come with a reasonable risk of revision to an AKA and lingering concerns about primary wound healing [1]. These patients are likely to have undergone extensive medical and surgical treatment in order to save their limb prior to being considered for amputation. In most patients, this will have involved undergoing extensive imaging, suffering long-standing pain and disability, long-term antibiotic therapy and multiple challenging surgeries. Some may wish to have no further intervention, and mitigate their risk of revision by undergoing a palliative AKA. This may be particularly relevant in those who have a high risk of failure of ambulation (as per Taylor et al.) [5] Or those at risk of wound complication (patients unwilling to give up smoking). However, some patients who have undergone this extensive prior-intervention may wish to try everything to preserve as much function as possible - acknowledging the risk of further revision. This approach is likely more appropriate for the younger, less co-morbid patient who has a reasonable chance of rehabilitation [6], or those who would benefit from a less physiologically stressful surgery or an increased ability to transfer.

The advances in surgical technique described above go some way in improving cosmesis, function and potentially reducing wound complications [6], compared to the procedures original design. However, at present, level of surgical training is a barrier against its selection - with many Surgeons having only been trained to perform

AKA or BKA, or being unable to perform the “patella fix” required in many variations of the traditional TKA. The Condylar sparing modification discussed above is simple to learn - requiring little training, quick to perform, requires no bone cutting or complex fixation and is relatively atraumatic to the patient. Additionally, the modified incision may improve the rates of wound complication typically afflicting the vascular and diabetic cohort of amputees [1].

## Conclusion

In summary, through knee amputation is an important surgical option providing functional benefits at a cost of increased risk of revision to the patient. With careful patient selection, this may be used in preference to above knee amputation. It is important that this does not fall out of practice, and it remains part of the discussion with the patient and MDT. Multiple modifications to the traditional technique are described - each offering a specific benefit, however it is unclear at present how their outcomes may compare or which is superior. Further research is required to delineate an optimum technique for use in diabetic and Vasculopathic patients. Specifically, a prospective study of outcomes of the condylar sparing modification would likely be of value in establishing its benefits compared to other approaches.

## References

1. Baumgartner R. Knieexartikulation und transgenikuläre Amputation. *Operative Orthopädie und Traumatologie*. 2011;23(4):289-95.
2. Behr J, Friedly J, Molton I, Morgenroth D, Jensen MP, Smith DG. Pain and pain-related interference in adults with lower-limb amputation: Comparison of knee-disarticulation, transtibial, and transfemoral surgical sites. *J Rehabil Res Dev*. 2009;46(7):963-72.
3. Hagberg E, Berlin OK, Renström P. Function after through-knee compared with below-knee and above-knee amputation. *Prosthet Orthot Int*. 1992;16(3):168-73.
4. Higgins T, Klatt J, Beals T. Lower Extremity Assessment Project (LEAP) - The best available evidence on limb-threatening lower extremity trauma. *Orthop Clin North Am*. 2010;41(2):233-9.
5. Houghton A, Allen A, Luff R, McColl I. Rehabilitation after lower limb amputation: A comparative study of above-knee, through-knee and Gritti-Stokes amputations. *Br J Surg*. 1989;76(6):622-4.
6. Majeski J. Modified supracondylar amputation of the femur. *Am Surg*. 2004;70(3):265-7.
7. Kock HJ, Friederichs J, Ouchmaev A, Hillmeier J, Gumpfenberg SV. Long-term results of through-knee amputation with dorsal musculocutaneous flap in patients with end-stage arterial occlusive disease. *World J Surg*. 2004;28(8):801-6.
8. Lim S, Javorski MJ, Halandras PM, Aulivola B, Crisostomo PR. Through-

- knee amputation is a feasible alternative to above-knee amputation. *J Vasc Surg.* 2018;68(1):197-203.
9. Moran BJ, Buttenshaw P, Mulcahy M, Robinson KP. Through-knee amputation in high-risk patients with vascular disease: Indications, complications and rehabilitation. *Br J Surg.* 1990;77(10):1118-20.
  10. Morse BC, Cull DL, Kalbaugh C, Cass AL, Taylor SM. Through-knee amputation in patients with peripheral arterial disease: A review of 50 cases. *J Vasc Surg.* 2008;48(3):638-43.
  11. Schmiegelow MT, Sode N, Riis T, Lauritzen JB, Duus BR, Lindberg-Larsen M. Re-amputations and mortality after below-knee, through-knee and above-knee amputations. *Dan Med J.* 2018;65(12):A5520.
  12. Nellis N, Van De Water JM. Through-the-knee amputation: An improved technique. *Am Surg.* 2002;68(5):466-9.
  13. Penn-Barwell JG. Outcomes in lower limb amputation following trauma: A systematic review and meta-analysis. *Injury.* 2011;42(12):1474-9.
  14. Duis KT, Bosmans JC, Voesten HGJ, Geertzen JHB, Dijkstra PU. Knee disarticulation: Survival, wound healing and ambulation. A historic cohort study. *Prosthet Orthot Int.* 2009;33(1):52-60.
  15. Albino FP, Seidel R, Brown BJ, Crone CG, Attinger CE. Through knee amputation: Technique modifications and surgical outcomes. *Arch Plast Surg.* 2014;41(5):562-70.
  16. Cull DL, Taylor SM, Hamontree SE, Langan EM, Snyder BA, Sullivan TM, et al. A reappraisal of a modified through-knee amputation in patients with peripheral vascular disease. *Am J Surg.* 2001;182(1):44-8.
  17. Met R, Janssen LI, Wille J, Langezaal AE, van de Mortel RWH, van de Pavoordt EDWM, et al. Functional results after through-knee and above-knee amputations: Does more length mean better outcome? *Vasc Endovascular Surg.* 2008;42(5):456-61.
  18. Taylor SM, Kalbaugh CA, Blackhurst DW, Hamontree SE, Cull DL, Messich HS, et al. Preoperative clinical factors predict postoperative functional outcomes after major lower limb amputation: An analysis of 553 consecutive patients. *J Vasc Surg.* 2005;42(2):227-35.
  19. Siev-Ner I, Heim M, Wershavski M, Adunsky A, Azariat M. Why knee disarticulation (through-knee amputation) is appropriate for non ambulatory patients. *Disabil Rehabil.* 2000;22(18):862-4.
  20. Krajbich JI. Lower-limb deficiencies and amputations in children. *J Am Acad Orthop Surg.* 1998;6(6):358-67.
  21. Kulkarni J, Pande S, Morris J. Survival rates in dysvascular lower limb amputees. *Int J Surg.* 2006;4(4):217-21.
  22. Raichle K. Prosthesis use in persons with lower- and upper-limb amputation. *J Rehabil Res Development.* 2008;45(7):961-72.
  23. Sansam K, Neumann V, O'Connor R, Bhakta B. Predicting walking ability following lower limb amputation: A systematic review of the literature. *J Rehabil Med.* 2009;41(8):593-603.
  24. Fowkes FGR, Aboyans V, Fowkes FJI, McDermott MM, Sampson UKA, Criqui MH. Peripheral artery disease: Epidemiology and global perspectives. *Nat Rev Cardiol.* 2017;14(3):156-70.
  25. Nehler MR, Coll JR, Hiatt WR, Regensteiner JG, Schnickel GT, Klenke WA, et al. Functional outcome in a contemporary series of major lower extremity amputations. *J Vasc Surg.* 2003;38(1):7-14.