



The Use of a Free Auricular Flap to Reconstruct a Large Full Thickness Nasal Defect

Chawla R, Thomas G and Johnson D*

Department of Plastic and Reconstructive Surgery, Oxford University Hospitals NHS Foundation Trust, UK

Abstract

Full thickness defects of the nose represent a difficult reconstructive challenge, especially when the defects are large. Vascularised chondrocutaneous free flaps from the root of the auricular helix can adequately serve to reconstruct the nose including the alar. We present a case of full thickness reconstruction of a near heminasal defect measuring over 12 cm² involving the nasal sidewall, alar and vestibular lining using a large free auricular flap.

Keywords: Nasal reconstruction; Auricular flap, Vestibular lining

Introduction

Full thickness defects of the nose represent a difficult reconstructive challenge, especially when the defects are large [1]. These defects are often seen after trauma, surgical resection or congenital deformities. For successful reconstruction, selected tissue must be similar to nasal structure in color, consistency and contour [2]. Local flaps such as forehead or nasolabial flaps may result in significant additional facial scarring that may require multiple revisions [3]. Vascularised chondrocutaneous free flaps from the root of the auricular helix can adequately serve to reconstruct the nose including the alar [4]. It can provide excellent symmetry, good color match and the donor defect can often be hidden [5,6]. The structural similarity between the alar and the auricular helices has allowed the use of vascularised free auricular flaps in order to reconstruct large nasal defects. The free auricular flap has several advantages [7]. Size can be tailored to the needs of the reconstruction which is especially important in large defects [8]. There are many similarities in the structure, contour, thickness and color match between the helical rim and the ala nasi which may minimise the need for further revision surgery and can provide superior aesthetic results when compared to local flap options [9]. Additionally this flap facilitates reconstruction of the base of the ala nasi at the alar-cheek angle and it provides an acceptable donor defect as it can easily be hidden with temporal hair [10]. We present a case of full thickness nasal reconstruction of the nasal sidewall, alar and vestibular lining using a large free auricular flap.

Case Presentation

A 69 year old man presented with recurrent Squamous Cell Carcinoma (SCC) to his right nasal sidewall and alar. It was previously resected six years prior and resurfaced using a full thickness skin graft. The recurrent SCC was treated using Mohs micrographic surgery, which successfully excised the full thickness soft tissue defect. Bony margins remained which necessitated further surgical excision including the piriform bone margin and the surrounding areas. This large full thickness defect (Figure 1) measuring 3 cm × 4 cm was temporarily resurfaced using a split thickness skin graft. Histological margins were clear and the patient underwent a staging CT which was unremarkable. Six months after the initial excision, reconstruction was performed using a large free auricular flap from the contralateral ear.

Operative procedure

A one stage free auricular flap, employing the root of the left helix and the adjacent skin from the conchal bowl was selected to reconstruct the full thickness right sided nasal defect. The procedure was performed under general anaesthesia. The right nasolabial artery and vein were isolated through an incision along the nasolabial fold. An outline of the nasal defect measuring 3 cm × 4 cm was outlined on the superior helix of the left ear and included part of the conchal skin which was to form the vestibular lining. The proximal superficial temporal vessels were exposed and harvested with the flap in order to achieve an adequate pedicle length. The donor vessels from the flap were anastomosed to the nasolabial artery and vein. Standard microvascular techniques were employed

OPEN ACCESS

*Correspondence:

David Johnson, Department of Plastic and Reconstructive Surgery, Oxford University Hospitals NHS Foundation Trust, Headley Way, Headington, Oxford OX3 9DU, UK, Tel: 01865 231085;

E-mail: david.johnson@ouh.nhs.uk

Received Date: 01 Apr 2019

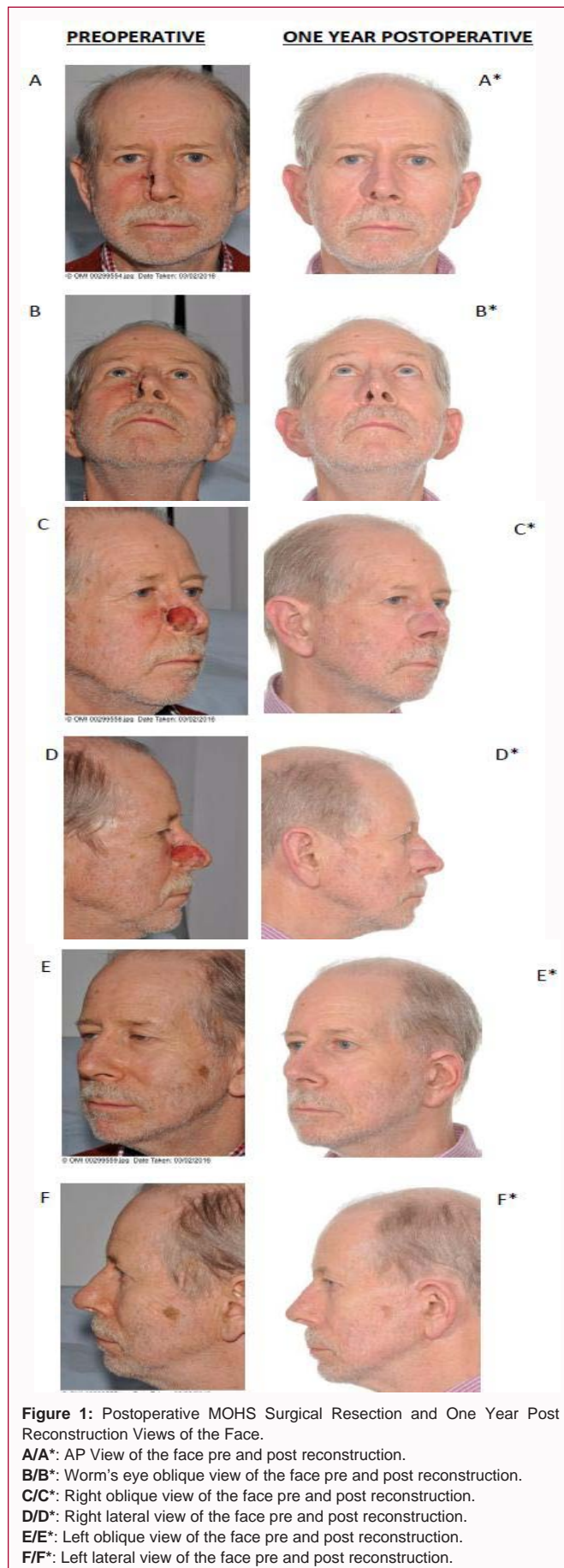
Accepted Date: 10 May 2019

Published Date: 16 May 2019

Citation:

Chawla R, Thomas G, Johnson D. The Use of a Free Auricular Flap to Reconstruct a Large Full Thickness Nasal Defect. *Clin Surg*. 2019; 4: 2431.

Copyright © 2019 Johnson D. This is an open access article distributed under the Creative Commons Attribution License, which permits unrestricted use, distribution, and reproduction in any medium, provided the original work is properly cited.



using 9-0 Ethilon sutures. The flap was inset using 5-0 Monocryl and 6-0 Prolene (Ethilon). The donor defect was closed primarily using a combination preauricular transposition flap. The donor defect was closed Surgipro (Covidien). The patient had routine postoperative discharged home after four days of helical rotation and a using 3-0 Vicryl and 5-0 flap monitoring and a minor flap debulking of the pedicle was performed six months later.

Discussion and Conclusion

Reconstruction of nasal defects is complex and must consider three nasal components; skin, osteocartilaginous framework and vestibular lining. Large defects present a particular reconstructive challenge. Many methods have been described. Traditionally these defects have been reconstructed by using pedicled flaps or with the use of composite grafts. Local pedicle flap options include nasolabial flaps, which can often be bulky and would require additional procedures to reconstruct the vestibular lining. Septal mucosal flaps can provide this; however, the disadvantages of these methods are that they would only be suitable for reconstructing smaller areas. Pedicled flaps could also include the versatile forehead flap. The forehead flap would be able to provide a large area, however, these flaps tend to be bulky, cause unsightly donor site scars and necessitate a number of staged surgical procedures. Auriculotemporal composite grafts can be utilized as an option to reconstruct the cartilaginous framework of the nose, but require a large inset area to allow the composite graft to gain a blood supply and so would be unsuitable in this case. Ideal options for the nasal defect in our case would include a single stage procedure able to reconstruct multiple nasal subunits, including all three nasal components, causing minimal donor site morbidity to the patient and provide a satisfactory aesthetic outcome. Here we present a case of a near total heminasal full thickness defect measuring over 12 cm². We have successfully demonstrated that the free auricular flap has achieved many desired aspects of nasal reconstruction; it has effectively reconstructed multiple nasal subunits including both lining and external vestibular skin, provided an ideal skin and color match and it has achieved a satisfactory aesthetic result, and with minimal donor site morbidity. Although this flap has been described in the literature as a recognized method of nasal reconstruction, it has mostly been used to reconstruct small defects. To our knowledge, this case is one of the largest described flaps of its kind. We have demonstrated that this flap is capable of reconstructing large full thickness nasal defects over 12 cm². We advocate use of this flap in very large heminasal defects as it successfully reconstructs multiple nasal subunits including the lining, cartilaginous support and external skin in one stage. Unlike in the series described by Yim [11] we have not found it necessary to use perform interpositional vein or artery grafting.

References

1. Antunes MB, Chalian AA. Microvascular reconstruction of nasal defects. *Facial Plast Surg Clin North Am.* 2011;19(1):157-62.
2. Holzmann D, Forster NA, Vital D, Giovanoli P. Reconstruction of Defects Involving the Nasal Ala and the Nasolabial Fold: The Role of the Microvascular Prehelical Rim Graft. *ORL J Otorhinolaryngol Relat Spec.* 2015;77(5):255-61.
3. Karaaltın MV, Karaaltın AB, Orhan KS, Cavdar G. Pre-auricular and ascending helical free composite flap in reconstructing an alar defect resulting from a human bite: a case report. *Kulak Burun Bogaz Ihtis Derg.* 2011;21(3):167-70.
4. Lassus P, Husso A, Vuola J, Lindford AJ. More than just the helix: A series

- of free flaps from the ear. *Microsurgery*. 2018;38(6):611-20.
5. Lin W, Qing Y, Liu J, Cen Y. Alar flap combined with free auricular composite flap for the reconstruction of nasal alar defect. *J Craniofac Surg*. 2015;26(2):562-4.
 6. Park SS. Reconstruction of nasal defects larger than 1.5 centimeters in diameter. *Laryngoscope*. 2000;110(8):1241-50.
 7. Parkhouse N, Evans D. Reconstruction of the ala of the nose using a composite free flap from the pinna. *Br J Plast Surg*. 1985;38(3):306-13.
 8. Pribaz JJ, Falco N. Nasal reconstruction with auricular microvascular transplant. *Ann Plast Surg*. 1993;31(4):289-97.
 9. Shenaq SM, Dinh TA, Spira M. Nasal alar reconstruction with an ear helix free flap. *J Reconstr Microsurg*. 1989;5(1):63-7.
 10. Shimizu F, Oatari M, Uehara M. Choice of recipient vessels for nasal ala reconstruction using a free auricular flap. *J Plast Reconstr Aesthet Surg*. 2015;68(7):907-13.
 11. Yim S, Eun SC. Chondrocutaneous Preauricular Free Flap for Reconstruction of Nasal Defects Aided by Interposition Vascular Graft. *J Craniofac Surg*. 2017;28(7):1842-6.