Clinics in Surgery

Research Article
Published: 15 Aug, 2016

The Treatment of Pediatric Supracondylar Humerus Fractures: Experience in a Tertiary Medical Center in a Rural State

*Karnes JM and Lubicky JP**

Department of Orthopaedics, West Virginia University, USA

Abstract

Background: In our rural state, most children with supracondylar humerus fractures (SCFs) are referred to our tertiary care medical center. Over a 4+ year period, the one pediatric orthopaedic surgeon in the state surgically treated more than 200 SCFs using a standard protocol. Closed reduction (CR) and percutaneous pinning was attempted in all cases. Open reduction and percutaneous pinning (OR/PP) was required in some. The purpose of this study was to review one surgeon's experience with the surgical treatment of SCF with a focus on fracture type and pattern and the need for open reduction as well as the incidence of nerve injuries.

Methods: Institutional Review Board approval for a retrospective chart review was attained and medical records of pediatric patients treated at our institution between 01/2010 and 09/2014 were reviewed. Current Procedural Terminology codes 24538, 24545, and 24546 were used to identify patients. Data were examined using summary statistics and Chi-square tests.

Results: Two hundred four patients were included in this study and 25 eventually required OR/PP for definitive management. The following factors were not statistically associated with OR/PP: fracture pattern, Gartland classification, laterality of extremity, or gender; however, age, presence of neurological symptoms on initial evaluation, and energy of fracture etiology were significantly associated. In 71 cases, a "U" shaped distal fragment was identified. The most common neurological symptoms on initial presentation were anterior interosseous nerve palsy (n=10, 4.9%) and non-dermatomal paresthesias (n=5, 2.5%). Factors significantly associated with neurological symptoms on initial presentation included: need for open reduction, medial-lateral pinning construct, Gartland Type III injury, age, and "U-shaped" fracture pattern.

Conclusions: No identified fracture pattern was significantly associated with need for open reduction; however, a previously undescribed "U-shaped" fracture pattern did have a significant association with neurological symptoms. Patients most likely to require OR/PP for a SCF were children over the age of five who presented with neurological symptoms on initial evaluation and/or had a high-energy injury etiology. The main indication for OR/PP was failure to achieve a satisfactory CR. Orthopaedic surgeons managing these fractures should have a low threshold to transition to an open procedure in patients with these risk factors if closed fracture reduction cannot be achieved expeditiously.

Level of Evidence: Level IV, case series

Keywords: Supracondylar fracture; Open reduction

OPEN ACCESS

Correspondence:
John P. Lubicky, Department of Orthopaedics, West Virginia University, P.O. Box 9196, Morgantown, WV 26506-9196, Tel: 304-293-1312; Fax: 304-293-7042;
E-mail: jlubicky@hsc.wvu.edu

Received Date: *20 May 2016*
Accepted Date*: 10 Aug 2016*
Published Date*: 15 Aug 2016*

Citation:
Karnes JM, Lubicky JP. The Treatment of Pediatric Supracondylar Humerus Fractures: Experience in a Tertiary Medical Center in a Rural State. Clin Surg. 2016; 1: 1082.

Introduction

Supracondylar humerus fractures (SCFs) are common injuries in pediatric populations, especially in the 0-3 and 4-7 year old age groups [1]. Treatment for this injury is guided by the stability and displacement of the opposing fracture fragments. Nearly all patients with Gartland Type II and all Type III injuries require operative intervention to maintain a stable reduction. Closed reduction with percutaneous pinning (CR/PP) is the preferred method of surgical management as it minimizes operative morbidity and enhances functional recovery. However, many authors have recommended a low threshold to use open reduction with percutaneous pinning (OR/PP) if closed reduction maneuvers fail or vascular compromise is encountered [2-9]. Repeated closed reduction attempts can cause soft tissue trauma, vascular, nervous, and physeal injuries, and compartment

Figure 1: Posterior to anterior sloping fracture demonstrated in a lateral radiograph.

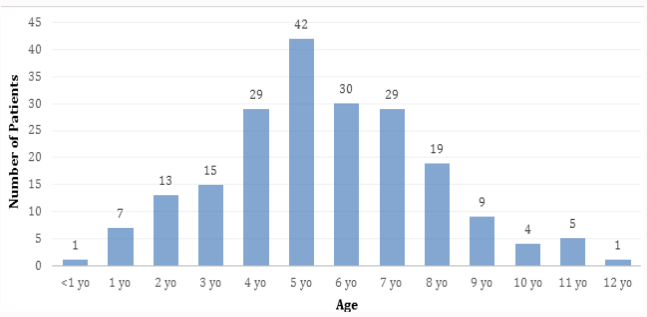

Figure 2: Age distribution of patients included in study.

syndrome [8,10]. OR/PP of SCFs has been established as a safe and reliable procedure. Identifying fracture patterns and types that are likely to fail closed reduction may facilitate safer and more efficient operative strategies [2,11-13]. In our rural state, most children with displaced supracondylar fractures are referred to our tertiary care medical center. During the period of this study, there was only one fellowship trained pediatric orthopaedic surgeon in the state. The primary purpose of this retrospective study was to report on that one surgeon's experience in the surgical treatment of SCF over a 4+ year time period with a focus on the need for open reduction and to determine if a specific fracture pattern was more likely to require that intervention. We hypothesized that a posterior to anterior, downward sloping fracture pattern would be more likely to require OR/PP due to unstable fracture anatomy and fragment displacement due to muscle forces (Figure 1). We also wanted to evaluate the incidence of nerve injuries related to this injury and risk factors for these injuries.

Materials and Methods

Patients were identified using Current Procedural Terminology (CPT) codes 24538, 24545, and 24546; all pediatric patients identified using this search were included in the study. Medical records and radiographs of all patients treated between 01/2010 and 09/2014 at our academic institution were retrospectively reviewed. Inclusion criteria were Gartland Type II and III non-pathologic SCFs in a previously uninjured elbow in skeletally immature children. Surgical management was provided under the direction of one experienced pediatric orthopaedic surgeon using the same protocol for all patients. Closed reduction was first attempted and OR/PP was reserved for cases with evidence of vascular compromise or failed closed reduction. An all-lateral pin construct was the preferred arrangement, but a medial-lateral construct was used when additional stability was required.

Table 1: Fracture etiology for patients included in analysis. All-terrain vehicle (ATV), motor vehicle collision (MVC).

Etiology	(n)	Percent of Sample
Fall	186	91.2%
ATV/Dirtbike/Go-kart	10	4.9%
Person landed on patient's arm	3	1.5%
MVC	2	1.0%
Sledding	2	1.0%
Suspected abuse	1	0.5%

Table 2: Nerve symptoms encountered on the initial, preoperative physical examination. Anterior interosseous nerve (AIN), posterior interosseous nerve (PIN).

Nerve Symptoms	(n)	Percent of Nerve Injuries	Percent of Sample
AIN Palsy	10	34.5%	4.9%
None-specific anesthesia or paresthesia	5	17.2%	2.5%
Median n. paresthesia	3	10.3%	1.5%
Radial n. palsy	3	10.3%	1.5%
Ulnar n. Paresthesia	2	6.9%	1.0%
PIN Palsy	1	3.4%	0.5%
Median n. anesthesia	1	3.4%	0.5%
Radial n. paresthesia	1	3.4%	0.5%
Combined PIN Palsy and Ulnar n. paresthesia	1	3.4%	0.5%
Combined AIN and Ulnar palsy	1	3.4%	0.5%
Combined Ulnar and Median n. paresthesia	1	3.4%	0.5%

Data collected included age, gender, injury etiology, open or closed fracture upon initial evaluation, side of injury, extension or flexion pattern, Gartland classification, time between injury and surgery, and presence of a nerve or vascular injury on initial evaluation. Anterior-posterior and lateral radiographs were reviewed by the authors and notable findings were recorded and discussed. Treatment-related data collected included open or closed reduction of the fracture, pin orientation, postoperative neurovascular injury, and failure to achieve union. Data analysis consisted of descriptive statistics and Chi-squared studies. Significance was set at $p<0.05$.

The primary outcomes assessed were the incidence of open reduction and its relationship to fracture pattern and perioperative neurological symptoms. Secondary outcome variables were indications for open reduction, incidence of pre/postoperative neurovascular injury, types and risks of nerve injury, and pinning technique.

Results

Two hundred twenty-four patients were identified and 204 met inclusion criteria and were entered into the study. Their charts and radiographs were reviewed. The majority of injuries occurred in females (114, 55.9%) and the average age was 5.5years (range 1 to 12) (Figure 2). One hundred twenty-eight children (62.7%) injured their left upper extremities with a fall being the most common etiology (91.2%) (Table 1). One hundred eighty-five (90.7%) of the patients were treated within 24 hours of injury, 13 (6.4%) had a delayed

Figure 3: Example of "U-shaped" fracture pattern of the distal humeral epiphysis with the anterior view. Seventy-one patients (34.8% of sample) presented with this injury.

presentation to our facility and subsequently underwent treatment more than 24 hours after injury [the medical records of six (2.9%) did not document the time of injury]. Two patients (0.9%) presented with an open fracture, no patients had a documented vascular injury, and 29 (14.2%) presented with paresthesia, anesthesia, or palsy on initial examination of the affected extremity (Table 2). Of 29 patients presenting with neurological symptoms, eight (27.6%) had a general decrease in sensation to light touch or reported paresthesias that resolved by discharge from the hospital. The remaining 21 (72.4%) had more specific symptoms with the most common being an anterior interosseous nerve (AIN) palsy (ten patients, 48%), followed by a radial nerve palsy (three patients, 14%), ulnar nerve paresthesia (two patients, 10%), and median nerve paresthesia (two patients, 10%) (Table 2).

Review of initial radiographs demonstrated 91 (44.5%) Gartland extension Type II injuries and 103 (50.5%) Type III injuries. Five (2.5%) were flexion type injuries and five (2.5%) injuries did not clearly meet the Gartland criteria. Seventy-one patients (34.8%) demonstrated a "U-shaped" fracture pattern where the most proximal portion of the distal humeral fragment was smoothly concave when viewed in the anterior-posterior view (Figure 3) and ten patients (4.9%) presented with a posterior to anterior sloping fracture. Of the 71 "U-shaped" fractures, 32 (45.1%) were posterolaterally displaced, 30 (42.3%) were posteromedially displaced, and nine (12.6%) were displaced in a direct posterior direction.

All 204 patients included in this study underwent operative management for their SCFs and 25 patients (12.3%) required open reduction (OR) (Table 3). Patients with suspected vascular injury (n=3) initially underwent successful closed reduction with percutaneous pinning, but subsequently lost radial and ulnar pulses and developed a pale, cool hand. In all cases, the pins were removed, the fracture site

Table 3: Indications for open reduction.

Indications for Open Reduction	(n)	Percent of Total Population of Open Reductions
Failed Closed Reductions	17	(68%)
Suspected Vascular Injury	3	(12%)
Open Fracture	2	(8%)
Other	3	(12%)

Table 4: Factors significantly associated with open reduction as determined by Chi-squared analysis. All-terrain vehicle (ATV), motor vehicle collision (MVC).

Population	(n) of Open Reductions	Percent with Open Reductions	p value
Less than 5 years 5 Years and Older	3 22	4.6% 15.8%	0.006
No Neurological symptoms Neurological symptoms	18 7	11.6% 28.0%	0.024
Fall High Energy (ATV, MVC, etc.)	20 5	10.8% 71.4%	0.0019

Table 5: Factors not significantly associated with open reduction as determined by Chi-squared analysis.

Population	(n) of Open Reductions	Percent with Open Reductions	p value
Posterior to Anterior Sloping Fractures	0	0	NA
Gartland Type II Injuries Gartland Type III Injuries	6 14	6.2% 11.9%	0.11
Left Right	14 11	10.9% 14.5%	0.45
Male Female	8 17	8.9% 14.9%	0.193
Non "U – Shaped Fractures" "U – Shaped Fractures"	12 13	9.9% 18.3%	0.054

was exposed, and the vessels were inspected. No vascular injury was found in any case and all patients recovered without incident. Both open fractures underwent OR. Of the 71 patients with a "U-shaped" fracture pattern, 13 (18.3% of the "U-shaped" fracture types) needed open reduction accounting for 52% of all open reductions. Statistical associations between independent factors and incidence of open reduction are demonstrated in Table 4 and 5. No specific fracture pattern was associated statistically with need for OR/PP.

One hundred forty-two (69.6%) fractures achieved stable fixation with an all-lateral pin construct, which was the preferred technique. Fifty-eight (28.4%) required a medial and lateral pin configuration and four (2%) had pins with supplementary hardware placed as an all-lateral construct failed to provide adequate stability. Patients requiring medial-lateral pin constructs had a higher incidence of perioperative neurological symptoms ($p<0.0001$), a higher incidence of open reduction ($p=0.007$), and were more likely to have a Gartland Type III fracture ($p<0.0001$); this construct was more commonly required in patients older than five years ($p=0.007$). Twenty patients (9.8%) initially presented without any neurological symptoms but reported having symptoms at either the immediate postoperative examination or in a subsequent outpatient visit. The most common complaint reported was ulnar nerve paresthesia (seven patients, 3.4%) and ulnar nerve palsy (seven patients, 3.4%) (Table 6). However, all neurologic symptoms had resolved or were continuing to resolve at the last office visit and no patient had a permanent functional deficit at the last follow-up.

Considering all 204 patients, the overall incidence of perioperative nerve symptoms was 49 (24.0%), which included complaints that resolved prior to discharge perhaps indicating that the incidence of true nerve injury might be over-represented. Two patients (0.9%) required open exploration for ulnar nerve palsy that failed to improve with typical conservative treatment; both patients had "U-shaped" fractures. In both cases, the nerves were in continuity but surrounded by scar. When the 71 patients with the "U-shaped" fracture pattern were analyzed separately, 26 (36.6% of the "U-shaped" fracture population and 53.1% of all patients exhibiting neurological symptoms) were found to exhibit perioperative neurological

Table 6: Patients that reported neurological symptoms following surgery, but did not report any symptoms prior to the procedure. Anterior interosseous nerve (AIN), posterior interosseous nerve (PIN).

Nerve Symptoms	(n)	Percent of Nerve Injuries	Percent of Sample
Ulnar nerve paresthesia	7	35.0%	3.4%
Ulnar nerve neuropraxia	7	35.0%	3.4%
Nonspecific anesthesia	2	10.0%	1.0%
AIN palsy	3	15.0%	1.5%
PIN palsy	1	5.0%	0.5%

symptoms. Also, perioperative neurological symptoms were more commonly reported in patients with a Gartland Type III injury ($p<0.0001$), in patients requiring open reduction ($p<0.005$), and in patients five years and older ($p<0.0001$).

Discussion

This retrospective review evaluated 204 Gartland Type II and III supracondylar humerus fractures that were treated with either CR/PP or OR/PP between 01/2010 and 09/2014 by one surgeon at a single academic institution. The reported incidence of open reduction for supracondylar fractures varies widely in the literature from 2.6% to 50% [3-7,14-23] and seems to be influenced by study selection criteria. Our 12.3% incidence of open reduction compares similarly to a recent case series from another academic tertiary referral center [18]. Other studies that reported a markedly lower incidence of open reduction were published nearly 20 years ago, which may reflect changes in practitioner attitudes toward surgical management [14]. The operative management of Gartland Type II and III supracondylar humerus fractures is well established, with most literature advocating for OR/PP for failed closed reduction. Achieving bony apposition must be accomplished with minimal compromise of the soft tissue which can be disrupted with repeated reduction attempts [8,10]. Several authors have suggested that factors commonly associated with open reduction can most easily be classified as either patient specific, injury pattern, or treatment specific variables.

Patient specific

A previous case series reported that age is significantly associated with open reduction (7.7 y/o vs. 5.9 y/o) [3]. Our results were similar; the average age of a patient undergoing OR/PP was 6.3 y/o (vs.5.4 y/o for CR/PP) and children five years and older were more likely to require OR/PP ($p=0.007$). It is our suspicion that age is a proxy variable for soft tissue density surrounding the fracture site, which can limit the ability to manipulate fracture fragments. Similar difficulties have been described in obese patients with the same injuries [5,24] and have been attributed to a decreased ability to manipulate the osseous structures through the increased subcutaneous tissue thickness.

Injury pattern

Although we found that open reductions more commonly occurred in Gartland Type III injuries, a result that is consistent with other case series [5,8], data analysis determined that it was not statistically significant; this finding could be related to the relatively small number of open reduction cases. Nevertheless, it makes intuitive sense as the degree of displacement and damage to the surrounding soft tissue is a consequence of the energy of the traumatic injury and fractures with greater displacement result in a greater likelihood of soft tissue interposition within the fracture site. Structures such as periosteum [13], brachialis or flexor-pronator muscle [16], or median/ulnar/radial nerve [8,22] have been proposed to be the main contributing factor for supracondylar fracture irreducibility as they serve as a mechanical block to reduction. Furthermore, vascular structures trapped within the fracture gap also commonly lead to open reduction, not only due to preventing re-approximation of the fracture fragments but, more importantly, for preservation of the distal blood supply. In addition to preventing proper apposition of the fracture fragments, the humeral metaphysis can "buttonhole" through the brachialis, which physically restrains the fragments and has been commonly associated with the need for open reduction [8,13,22,25,26].

Reported fracture characteristics associated with a higher incidence of open reduction can be classified into two categories, transverse and comminuted fragments. Transverse fracture patterns with bayonet apposition increase the risk of brachialis interposition and oblique supracondylar fractures that extend proximal-lateral to distal-medial were found to have a higher incidence of flexor-pronator entrapment [16]. The second group is comprised of patterns that are mechanically unstable due to comminution, orientation of the fracture lines along areas of the bone that resist loading [8,13,16], and the thin bone of the distal humerus, which destabilizes the reduction due to concentration of deforming forces across a small surface area [7]. There is a discrepancy that emerges over the direction of displacement and the incidence of open reduction as some results suggest that posteromedial displacement has a higher association with open reduction [8] and others suggest that posterolateral displacement has a higher association with open reduction [16].

Treatment specific

Because our patient population is predominantly rural, patients often present several days after injury. Of the 13 patients that were evaluated more than 24 hours following injury, only one patient (7.7%) required open reduction, compared to the 12.4% of 185 children that were treated within 24 hours of injury representing 92% (23/25) of the open reductions in this series. This finding is consistent with several other series that found that the incidence of open reduction was not higher in patients that were not immediately treated [6,17,18,27-30], but conflicts with other series suggesting that delayed treatment leads to a higher incidence of open reduction [5]. As the increased difficulty in achieving reduction in the delayed setting is thought to be caused by peri-fracture swelling of the surrounding tissue [31], patients that were treated more than 24 hours following injury in our series may very well have been beyond the period of peak swelling.

Complications

There were no compartment syndromes, pin tract infections, wound healing complications, or loss of fixation without a traumatic etiology (n=2). There were only three suspected vascular injuries that were encountered after closed reduction of a fracture. Immediately after discovering this clinical finding, the pins were removed and the injury site was explored with no vessel injury found. Therefore, no true vascular injury was encountered in this series. The most commonly encountered complication was transient neurological symptoms [n=49(24.0%) with symptoms present only on preoperative examination and n=41(20.1%) with symptoms that were present on both preoperative and postoperative examinations]. Patients undergoing open reduction had a higher incidence of transient neurological symptoms than patients receiving closed reduction (52% vs. 20%).

The main limitation of this study is its retrospective design. However, it documents the outcome of treatment by one pediatric

orthopaedic surgeon working in a single hospital with a consistent treatment protocol for every patient. Therefore, there was no variation in how these patients were managed. Another limitation which has not been actively raised in other studies is the reliability of the neurovascular examination in these young patients. Trying to determine specific motor function, sensation, or even obtaining pulses can be challenging in these scared children who are in pain. What was found to be a postoperative deficit may have, infact, been present preoperatively and was not detectable. Also, length of follow-up was not standardized in terms of an absolute time period. Because of the rural nature of the practice, many patients came from long distances to the medical center. The parents often found it a hardship to return for repeated follow-ups and therefore follow-up was terminated as soon as issues were resolved or resolving. Obviously, more data may have been available if standard follow-up periods had been followed.

Data from this retrospective review did not support our hypothesis that a posterior to anterior sloping fracture would be associated with a higher incidence of OR/PP. In fact, no patients that demonstrated this pattern required it. To our knowledge, this report is the first to describe a "U-shaped" supracondylar humerus fracture that demonstrated a higher, although not statistically significant, incidence of OR/PP as well as a statistically significant association of OR/PP with neurological symptoms on initial presentation. If the sample size were larger, we anticipate that a statistical association between the "U-shaped" fracture pattern and open reduction would be made.

In conclusion, no identified fracture pattern was significantly associated with need for open reduction; however, a previously undescribed "U-shaped" fracture pattern did have a significant association with neurological symptoms. Patients most likely to require OR/PP for a supracondylar humerus fracture were children over the age of five who presented with neurological symptoms on initial evaluation and/or had a high-energy injury etiology. The main indication for open reduction/percutaneous pinning was failure to achieve a satisfactory closed reduction. Orthopaedic surgeons managing these fractures should have a low threshold to transition to an open procedure in patients with these risk factors if closed fracture reduction cannot be achieved expeditiously.

References

1. Cheng JC, Ng BK, Ying SY, Lam PK. A 10-year study of the changes in the pattern and treatment of 6,493 fractures. J Pediatr Orthop. 1999; 19: 344-350.
2. Cramer KE, Devito DP, Green NE. Comparison of closed reduction and percutaneous pinning versus open reduction and percutaneous pinning in displaced supracondylar fractures of the humerus in children. J Orthop Trauma. 1992; 6: 407-412.
3. Aksakal M, Ermutlu C, Sarisozen B, Akesen B. Approach to supracondylar humerus fractures with neurovascular compromise in children. Acta Orthop Traumatol Turc. 2013; 47: 244-249.
4. Walmsley PJ, Kelly MB, Robb JE, Annan IH, Porter DE. Delay increases the need for open reduction of type-III supracondylar fractures of the humerus. J Bone joint Surg Br. 2006; 88: 528-530.
5. Sun LJ, Wu ZP, Yang J, Tian NF, Yu XB, Hu W, et al. Factors associated with a failed closed reduction for supracondylar fractures in children. Orthop Traumatol Surg Res. 2014; 100: 621-624.
6. Donnelly M, Green C, Kelly IP. An inconvenient truth: treatment of displaced paediatric supracondylar humeral fractures. Surgeon. 2012; 10: 143-147.
7. Barlas K, George B, Hashmi F, Bagga T. Open medial placement of Kirschner wires for supracondylar humeral fractures in children. J Orthop Surgery. 2006; 14: 53-57.
8. Fleuriau-Chateau P, McIntyre W, Letts M. An analysis of open reduction of irreducible supracondylar fractures of the humerus in children. Can J Surg. 1998; 41: 112-118.
9. Ladenhauf HN, Schaffert M, Bauer J. The displaced supracondylar humerus fracture: indications for surgery and surgical options: a 2014 update. Curr Opin in pediatr. 2014; 26: 64-69.
10. Cramer KE, Green NE, Devito DP. Incidence of anterior interosseous nerve palsy in supracondylar humerus fractures in children. J Pediatr Orthop. 1993; 13: 502-505.
11. Mulhall KJ, Abuzakuk T, Curtin W, O'Sullivan M. Displaced supracondylar fractures of the humerus in children. Int Orthop. 2000; 24: 221-223.
12. Kazimoglu C, Cetin M, Sener M, Agus H, Kalanderer O. Operative management of type III extension supracondylar fractures in children. Int orthop. 2009; 33: 1089-1094.
13. Kumar R, Kiran EK, Malhotra R, Bhan S. Surgical management of the severely displaced supracondylar fracture of the humerus in children. Injury. 2002; 33: 517-522.
14. Mehlman CT, Crawford AH, McMillion TL, Roy DR. Operative treatment of supracondylar fractures of the humerus in children: the Cincinnati experience. Acta orthop Belg. 1996; 62 Suppl 1: 41-50.
15. Chen W, Li X, Zheng Z, Zeng Y, Meng L, Zhang J, et al. [Retrospective analysis of complications of supracondylar fracture of humerus in children]. Zhongguo Xiu Fu Chong Jian Wai Ke Za Zhi. 2010; 24: 315-318.
16. Reitman RD, Waters P, Millis M. Open reduction and internal fixation for supracondylar humerus fractures in children. J Pediatr Orthop. 2001; 21: 157-161.
17. Abbott MD, Buchler L, Loder RT, Caltoum CB. Gartland type III supracondylar humerus fractures: outcome and complications as related to operative timing and pin configuration. J Child Orthop. 2014; 8: 473-477.
18. Kronner JM Jr, Legakis JE, Kovacevic N, Thomas RL, Reynolds RA, Jones ET. An evaluation of supracondylar humerus fractures: is there a correlation between postponing treatment and the need for open surgical intervention? J Child Orthop. 2013; 7: 131-137.
19. Khoshbin A, Leroux T, Wasserstein D, Wolfstadt J, Law PW, Mahomed N, et al. The epidemiology of paediatric supracondylar fracture fixation: a population-based study. Injury. 2014; 45: 701-708.
20. Mazda K, Boggione C, Fitoussi F, Pennecot GF. Systematic pinning of displaced extension-type supracondylar fractures of the humerus in children. A prospective study of 116 consecutive patients. J Bone Joint Surgery Br. 2001; 83: 888-893.
21. Mangwani J, Nadarajah R, Paterson JM. Supracondylar humeral fractures in children: ten years' experience in a teaching hospital. J Bone Joint Surg Br. 2006; 88: 362-365.
22. Oh CW, Park BC, Kim PT, Park IH, Kyung HS, Ihn JC. Completely displaced supracondylar humerus fractures in children: results of open reduction versus closed reduction. J Orthop Sci. 2003; 8: 137-141.
23. Houshian S, Mehdi B, Larsen MS. The epidemiology of elbow fracture in children: analysis of 355 fractures, with special reference to supracondylar humerus fractures. J Orthop Sci. 2001; 6: 312-315.
24. Sangkomkamhang T, Singjam U, Leeprakobboon D. Risk factors for loss of fixation in pediatric supracondylar humeral fractures. J Med Assoc Thai. 2014; 97: S23-28.
25. Archibeck MJ, Scott SM, Peters CL. Brachialis muscle entrapment in displaced supracondylar humerus fractures: a technique of closed reduction and report of initial results. J Pediatr Orthop. 1997; 17: 298-302.

26. Rasool MN, Naidoo KS. Supracondylar fractures: posterolateral type with brachialis muscle penetration and neurovascular injury. J Pediatr Orthop. 1999; 19: 518-522.

27. Leet AI, Frisancho J, Ebramzadeh E. Delayed treatment of type 3 supracondylar humerus fractures in children. J Pediatr Orthop. 2002; 22: 203-207.

28. Ozkoc G, Gonc U, Kayaalp A, Teker K, Peker TT. Displaced supracondylar humeral fractures in children: open reduction vs. closed reduction and pinning. Arch Orthop Trauma Surg. 2004; 124: 547-551.

29. Iyengar SR, Hoffinger SA, Townsend DR. Early versus delayed reduction and pinning of type III displaced supracondylar fractures of the humerus in children: a comparative study. J Orthop Trauma. 1999; 13: 51-55.

30. Sibinski M, Sharma H, Bennet GC. Early versus delayed treatment of extension type-3 supracondylar fractures of the humerus in children. J Bone Joint Surg Br. 2006; 88: 380-381.

31. Paradis G, Lavallee P, Gagnon N, Lemire L. Supracondylar fractures of the humerus in children. Technique and results of crossed percutaneous K-wire fixation. Clin Orthop Relat Res. 1993; 297: 231-237.