Clinics in Surgery

Research Article
Published: 11 Nov, 2021

The Library of Images, an Instrument for Rule Out CT Scan in the Emergency Department, During COVID Times, in Patients with Liver Resections Using Coagulation Necrosis

Adela Golea[1]*, Raluca Tat[1], Eugenia Maria Lupan[1], Nadim Al Hajar[2], Radu Badea[3] and Simona Mărgărit[4]

[1]*Department of Emergency Medicine, University of Medicine and Pharmacy, Romania*

[2]*Department of Surgery, University of Medicine and Pharmacy, Romania*

[3]*Department of Ultrasound, University of Medicine and Pharmacy, Romania*

[4]*Department of Anesthesiology and Intensive Care, University of Medicine and Pharmacy, Romania*

Abstract

The pandemic period, in which patients with liver tumor pathology presented in the emergency department for various acute febrile conditions, exposes them to numerous irradiating examinations for diagnosis purposes. The large number of imagistic investigations performed in the emergency departments due to the agglomeration of cases during the pandemic, increases the waiting time until an abdominal computer tomography is performed and the result is obtained.

Understanding the parenchymal structural changes caused by the use of coagulation necrosis provides pathophysiological support for the interpretation of changes observed in postoperative ultrasonographic examination and the differentiation of residual scar aspects from other complications and reduces the number of exposures to high class imagistic investigations. There were selected, in this retrospective study, 82 patients examined in the Ultrasonography Department with liver tumor. In case of 49 (59.75%) patients are opted for the coagulation necrosis technique only, with intraoperative ultrasound guidance and CT confirmation of the postoperative ultrasonographic aspects. Only 40 (48.78%) patients had an evolution without complication or tumor recurrence and remain on study evaluation, 32 (39.02%) of patients with lesion under 4cm from selected patients develop scar with immobile air artifacts ultrasound aspect.

The analysis of the selected image library allowed the description of the evolution of the postoperative ultrasonographic changes at 3/6/9 months. The description of an examination algorithm based on the ultrasonographic aspects identified in the imaging database of an expert center can be a diagnostic support tool for emergency physicians, for the purpose of a rapid exclusion rule (rule-out for CT scan) and reducing the number of emergency CT scans.

Keywords: Emergency; Liver tumor; Ultrasound monitoring; Postoperative ultrasonography, Immobile air trapping

OPEN ACCESS

Correspondence:
Adela Golea, Department of Emergency Medicine, University of Medicine and Pharmacy, 3-5 Clinicilor Street, Cluj-Napoca, Romania, E-mail: Adela.Golea@umfcluj.ro

Received Date: *24 Sep 2021*
Accepted Date*: 08 Nov 2021*
Published Date*: 11 Nov 2021*

Citation:
Golea A, Tat R, Lupan EM, Al Hajar N, Badea R, Mărgărit S. The Library of Images, an Instrument for Rule Out CT Scan in the Emergency Department, During COVID Times, in Patients with Liver Resections Using Coagulation Necrosis. Clin Surg. 2021; 6: 3351.

Introduction

The importance of the problem

The pandemic period in which patients with liver tumor pathology present in the emergency department for various acute febrile conditions, that also require the investigation of tumor complications, exposes them to numerous irradiating examinations for diagnosis purposes.

The large number of imagistic investigations in the emergency departments due to the agglomeration of pandemic cases, increases the waiting time until an abdominal computer tomography is performed and the result is obtained.

In this context, the imaging centers' experience in complex ultrasonographic (pre/intra/post surgery of the liver) examination may provide supporting data for the exclusion of scarring or of differential diagnosis, especially for liver abscess, quite common (1.6% to 13%) in post-resection

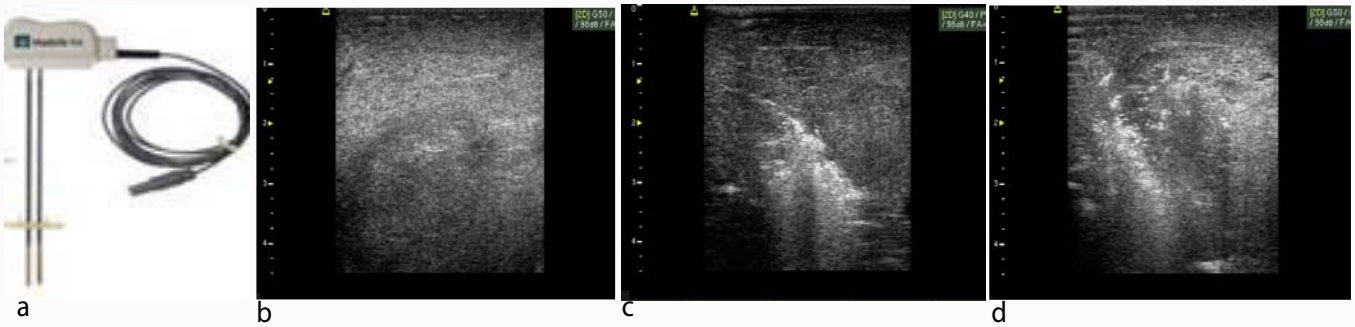

Figure 1: Habib device (a) and the intraoperative (b) aspect (personal image library) of creating the section tranche (c) by coagulation necrosis (d), using the device. (Personal US images library).

patients [1].

The growing worldwide incidence of primary (hepatocyte, ductal, mesenchymal or mixed) and secondary liver tumors has necessitated the development of diagnostic and therapeutic protocols. The most common liver tumor is hepatocellular carcinoma, with an annual incidence of 300,000 to 1 million new cases, the area distribution being conditioned by risk factors, the highest being found in Sub-Saharan Africa [2]. Liver cancer ranks 5th in the world in term of incidence and in terms of mortality it ranks 3rd [2]. Ultrasonography, through its low cost price, sensitivity and increased specificity of the method, is the first intention examination in the diagnostic screening of liver tumors in population risk groups.

Current oncological concepts promote surgical therapies of segmental excision within oncological limits, preserving as much of the liver parenchyma as possible. The association of ultrasound – guided radioablation with surgical excision allowed the preservation of the functional parenchyma, the creation of a resection tranche within oncological safety limits and implicitly reduced the number of recurrences.

Dynamic tracking of sequela ultrasonographic changes of surgical techniques reduces the exposure to CT scans, allowing an early approach to associated acute pathologies, in the emergency department.

Ultrasound - guided ablation using the "Habib 4x" device achieves an area of peritumoral necrosis, with the aim of obtaining the demarcation of the tumor surface and the resection inside the area of coagulation necrosis. Ultrasonographic guidance allows visualization of the occurrence of peritumoral necrosis and intratumoral changes of necrosis-liquefaction (Figures 1a-1d).

In order to increase the sensitivity and specificity of the ultrasonographic examination, it is necessary to know the intraoperative cellular changes produced by the "Habib 4x" device.

Imaging exploration

The physical basis of the ultrasonographic examination is represented by the amount of ultrasound transmitted and reflected, this depending on the density and resistivity of the tissues interposed in the way of the ultrasound beam. The change in the physical and chemical condition of the tissue components following exposure to high temperatures leads to changes in tissue density and implicitly the ultrasonographic appearance related to decreased resistivity, the appearance of perinecrotic edema and pseudoaerial artifacts by microbubbles forming (immobile air trapping) when reaching the boiling points of different structures.

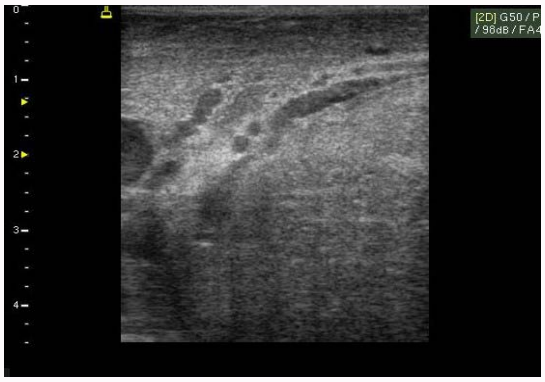

Figure 2: Intraoperative examination Sludge aspects inside the blood vessel (personal library of US images).

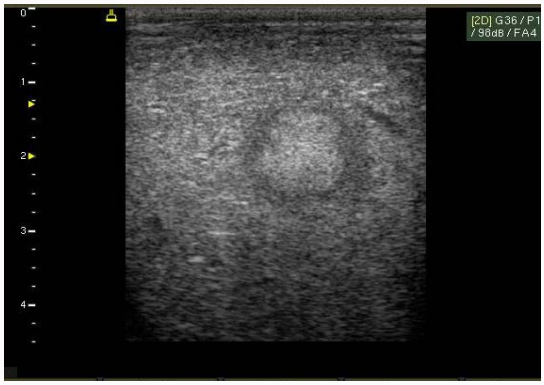

Figure 3: Intraoperative examination peritumoral halo (personal library of US images).

The physical phenomena that appear determine repercussions on the ultrasonographic aspect, as follows:

a) Heating - liquefaction: Decrease in tissue density, ultrasound appearance becoming hypoechoic; b) The blood becomes fluid as the temperature increases, but the figurative elements degrade and upon cooling they aggregate into stackings/conglomerates, creating a viscous fluid, with the appearance of sludge in the vessels and with the appearance of intravascular thrombosis (Figure 2); c) Cellular ischemia caused by vascular changes will lead to alteration of transmembrane hydroionic exchanges, with the appearance of transudation, followed by exudation and sometimes cellular apoptosis, and the destruction of specific tissue architecture and the

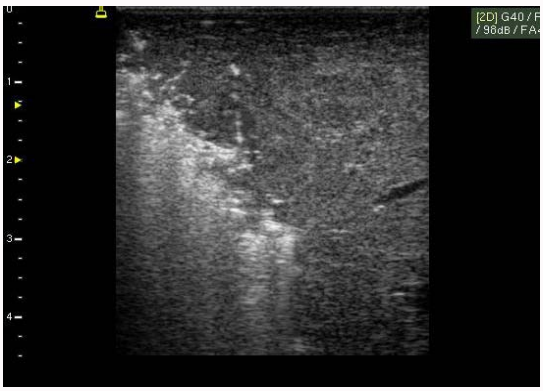

Figure 4: Intra operative examination: Post-operative air artifact "immobile air trapping" (personal library of US images).

transformation of the homogeneous ultrasound aspect of the liver texture into an inhomogeneous area with echogenic elements; d) The appearance of perilesional interstitial edema by mixed mechanism (liquefaction, transudation) will determine the decrease of tissue density at this level and the ultrasound appearance of a hypoechoic halo around the resection area (Figure 3), which over the time will evolve by reduction in size and fibrosis; e) Reaching the boiling point of different structures will cause their destruction, and the formation through coagulation, when cooling, of necrotic masses of different degrees and extensions, ultrasound translated by inhomogeneous areas, with echogenic elements, depending on density, and immobile air elements (echogenic with posterior artifact)defined by ultrasound as the sign "immobile air trapping" (Figure 4).

The dynamic 2D ultrasonographic examination and the comparison of imaging results are the decisive elements for the integration of the clinical imaging result and the increase of the diagnostic accuracy of the examination in 2D mode.

In the specialty literature, the post operative follow-up is performed with high-performance imaging methods such as contrast computer tomography and magnetic resonance during and at the end of treatment. In this context, the contrast – enhanced ultrasonographic examination technique has emerged, which improves the classical ultrasonographic examination technique, especially regarding the evaluation of tumor – type vascularization, and which is indicated to be performed for recurrences monitoring every 3 months [3,4]. Essential for ultrasonographic monitoring is the comparison of the preoperative, early postoperative and the evolving aspects. It is important in the ultrasonographic examination to know the morphopathological changes produced at the tissue level, which can induce complex ultrasonographic aspects depending on the water content and fibrous tissue change in time, implicitly the change of tissue density and acoustic impedance [3].

The aim of the study was to retrospectively evaluate the images archived in the library and identifying the ultrasonographic dynamic postoperative signs visualized in patients registered with pre/intra/postoperative examinations, to describe an algorithm for identifying postoperative sequela (rule out), with an eye to reducing exposure to irradiating CT examinations during a pandemic and optimizing emergency care in patients with acute febrile pathology associated with liver tumor comorbidities.

The description of an examination algorithm based on the ultrasonographic aspects identified in the imaging database can be a diagnostic support tool for emergency physicians with the purpose of a rapid diagnosis and the reduction of the number of CT examinations.

Materials and Methods

The study is a retrospective analysis of postoperative ultrasonographic images from patients with liver tumors operated using the "Habib 4x" device and validated by CT scans. Ultrasonographic changes were identified in the first 3 months, at 6 months, at 9 months and after 9 months after surgery, to describe an emergency decision algorithm of the need for computer tomography investigation, for febrile patients with liver tumor comorbidities operated by the radio ablation method, with the induction of coagulation necrosis.

The study group included ultrasonographic images stored in jpeg format, from our library of images, from 82 patients examined in the Ultrasonography Department of the Emergency Clinical Hospital "O. Fodor" from Cluj Napoca, between October 2006 and July 2008, with the followings election criteria: 1) Age over 18 years; 2) Preoperative ultrasonographic diagnosis of liver tumor; 3) Intra and postoperative ultrasonographic examination after surgery with Habib 4x radioablation procedure, with the induction of coagulation necrosis; 4) The confirmation of postoperative ultrasound aspects of CT scans in selected patients from the database.

The evaluated images were stored by a physician with at least 5 years of experience in ultrasonographic examinations, using a portable PICO SONOACE device, with multifrequency convex transducer (2 MHz to 5 MHz) and multi frequency linear transducer (5 MHz to 10 MHz), with color Doppler, power Doppler and harmonic tissue examination capacity. The analysis of the imaging data was performed retrospectively based on the existing records, by a physician with at least 15 years of experience in ultrasonographic examinations.

The ultrasound elements followed were: The resection cavity (with transudate, detritus, clots); peri-resection parenchymal in homogeneity, magma appearance, hypoechoic with echogenic elements by incorporating static air bubbles in the coagulation necrosis (specific artifact observed, described by the author as "immobile air trapping" – non-evolving air artifact, unchangeable with position); late postoperative scar appearance of the parenchyma with linear echogenic elements (fibrosis) or oval with comet tail artifacts (remaining air bubbles – "immobile air trapping").

In the patients included in the evaluation the ultrasonographic changes on images stored at 7 days, 3, 6, 9 months were observed.

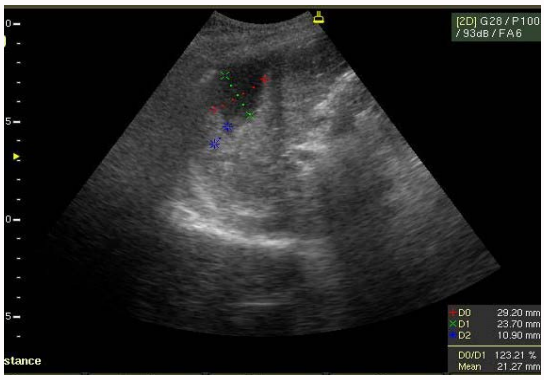

Figure 5: Post resection cavity (7 days postoperative) "immobile air trapping" peri-cavity (personal US images library).

Figure 6: Post-resection cavity with detritus (1 month postoperative) (personal US images library).

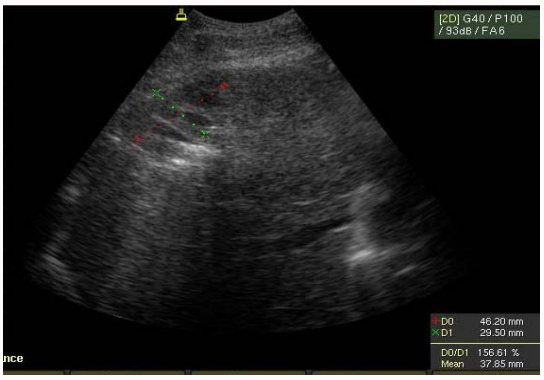

Figure 7: Cavity reduction, with recovery through fibrosis and the persistence of the "immobile air trapping" artifact (personal US images library).

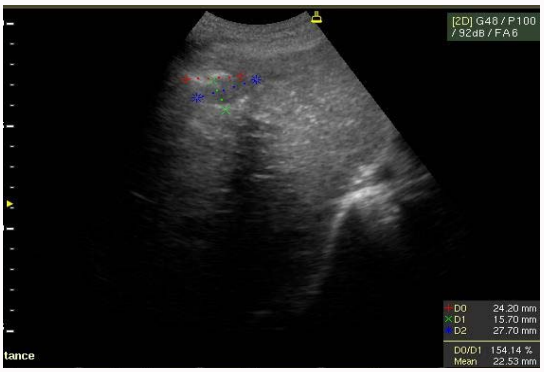

Figure 8: Scarring of the parenchyma (the residual cavity disappears) and the maintenance of the "immobile air trapping" artifact (personal US images library).

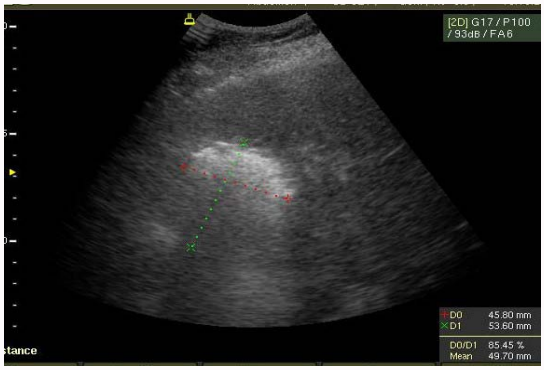

Figure 9: The aspect of the "immobile air trapping" artifact in there section cavity 7 days after surgery (personal US images library).

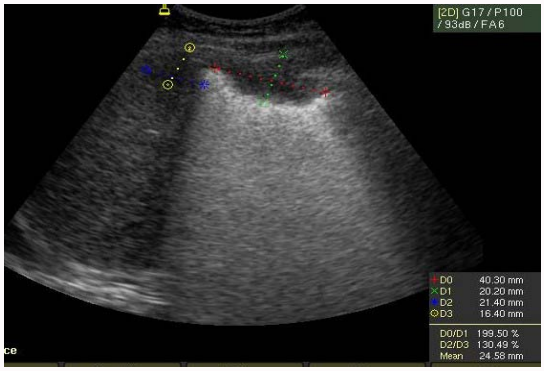

Figure 10: The reduction of the remaining cavity and of the "immobile air trapping" artifact 1 month after surgery (personal US images library).

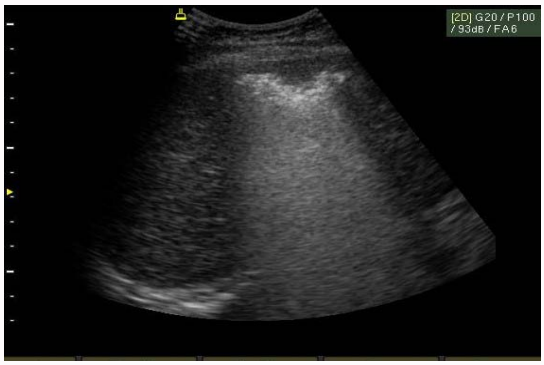

Figure 11: The reduction of the remaining cavity and of the "immobile air trapping" artifact 2 months after (personal US images library).

The graded changes of the aspect of the post-resection cavity, the parenchymal area around the resection area (coagulation tissue necrosis area), and the appearance of the remaining parenchyma were observed. The resection cavity normally becomes a residual cavity which decreases in size; the intracavitary air is resorbed and disappears (Figures 5-8).

The successions of ultrasonographic aspects in the absence of hemorrhagic or infectious – inflammatory complications are: 1) Transonic/hypoechoic with echogenic elements; 2) Reduction of dimensions, sometimes with "air trapping" in the residual cavity (Figure 9); 3) Disappearance of the residual cavity, with parenchymal regeneration; 4) The appearance of the fibrosis types car (hyperechoic or hyperechoic bands with the appearance of "immobile air trapping"). The resection margins approach resulting in a hyperechoic scar appearance in which the images of "immobile air trapping" caused by microbubbles produced during tissue liquefaction and sudden cooling may persist (Figures 10-12). Peri-cavity the liver tissue regenerates with a normal aspect.

The descriptive statistical analysis was performed using Microsoft Office Excel 2010 – data analysis: Logical functions (AND, IF etc.), data functions, statistical functions.

Results

There were selected, in this 2 month retrospective study (June to July 2021), 82 patients examined in the Ultrasonography Department

Figure 12: The disappearance of the cavity and the maintenance of the "immobile air trapping" artifact 3 months after (personal US images library).

Figure 13: Hepatic abscess – in homogenous area with hypo/hyperechoic areas, with a tendancy to delimitate, with transonic areas (posterior acoustic enhancement) and mobile echoic elements arranged antidecliv (air artifacts most likely secondary to anaerobic infection).

of the Emergency Clinical Hospital from Cluj Napoca, between October 2006 and July 2007 (period with ultrasound protocol for liver tumor) with the ultrasonographic diagnosis of liver tumor. Data on the characteristics of the identified formations, the presence of comorbidities, the operating technique used, were analyzed selecting a number of 49 patients who opted for the coagulation necrosis technique only, with intraoperative ultrasound guidance and CT confirmation of the postoperative ultrasonographic aspects (Table 1).

After analyzing the image gallery for the existing images of the remaining patients in the study, the 9 patients who developed postoperative tumor recurrences and septic complications up to 9 months were excluded (Table 2). For the 40 patients left for the analysis of ultrasonographic images, it was observed that, in the case of formations less than 4 cm (32 patients remaining in the evaluation, 65.31% of those selected), 100% of them presented, at 3 months, only scarring and "immobile air trapping" images.

Non-detection in emergency settings, at ultrasonography, of other poorly delimited hypoechoic areas or with nodular aspect [5], with echogenic elements of septic or air antideclivity type, in febrile context (aspect of septic complication) (Figure 13), thus excludes an acute hepatic pathology of septic type and implicitly the exposure to a CT imaging investigation of this category of patients.

In those with formations over 4 cm, in number of 8 (16.32%) patients remaining in the study, there was observed, in 50% of them (8.16% of the selected group), the persistence of the postoperative cavity at 6 months associated with the appearance of "immobile air trapping", and in those with formations over 5 cm (in number of 3 remaining in the study) it was observed the maintenance of a minimum cavity and at 9 months at 100% (6.12% of the selected group).

The result of the analysis allowed the description of the following algorithm (Table 3) for the selection of patients who do not require high – resolution CT investigations, in the context of COVID-19 epidemic if presented in the emergency department with febrile syndrome and postoperative status of radioablation liver resection:

Discussion

Transabdominal ultrasonographic examination of the liver parenchyma is influenced by the resolution of the examination apparatus and the experience of the examiner. Structures with

Table 1: The distribution of patient's admited in the study according to the peculiarities of ultrasonographically identified tumors, the presence of comorbidities and the surgical technique used.

Total number of examinated patients (%)	The distribution of patients according to the number of tumor formations identified			
	Single tumor	2 tumor formations	More than 2 formations	Dissemination (over 5 formations)
82 (100%)	36 (43.90%)	17 (20.73%)	14 (17.07%)	15 (16.29%)
	The distribution of patients according to the size of the tumor formations identified			
<3 cm	9	10	8	5
3–4 cm	6	5	3	4
>4 cm	21	11	3	6
	The distribution of the identified tumors in the hepatic lobes			
right lobe	30	15	13	6
left lobe	5	1	1	-
right and left lobe	-	1	-	8
caudate lobe	1	-	-	1
	The association of comorbidities			
33 (40.24%)	4	8	9	12
	Echo – guided coagulation necrosis surgery technique – used singularly			
49 (59.75%)	36 (43.9%)	11 (13.41%)	2 (2.44%)	0 (0%)

Table 2: Aspects of postoperative US monitoring in selected patients.

The size of the formation	No. of patients out of a total of 49 (100%)	US appearance 7 days PO	US appearance 3 months PO	US appearance 6 months PO	US appearance 9 months PO	PO Complications	PO Tumor recurrences	No. of patients remaining in thestudy 40 (81.63%)
=<2 cm	9 (18.36%)	minimum C, IAT pericavity	SA., IAT	Reduction of SA, IAT aspect persistence	SA., IAT.	absent	no	9 (18.36%)
2–3 cm	14 (28.57%)	minimum C, IAT pericavity	SA., IAT	Reduction of SA, IAT aspect persistence	SA., IAT.	absent	1 at 9 months	13 (26.53)
3-4 cm	10 (20.41%)	C with echoic elements; IAT pericavity	SA., IAT	Reduction of SA, IAT aspect persistence.	SA., IAT.	absent	no	10 (20.41)
>4 cm	10 (20.41%)	Medium C with echoic elements or multiple cavities; IAT pericavity	SA., IAT; 1 patient with persisting C, IAT	Reduction of SA, IAT aspect persistence, 1 patient with persisting C	SA., IAT.	absent	3 at 6 months, 2 at 9 months	5 (10.20%)
>5 cm	6 (12.24%)	Large C with residue and echoic elements; IAT pericavity	persisting C, IAT.	SA., IAT aspect persistence.	Reduction of SA, IAT aspect persistence.	3 patients with abscess, which require dreintervention between 7 days – 1 month	no	3 (6.12%)

Abbreviations: PO: Postoperative; US: Ultrasonographic; C: Cavity; SA: Scarappearance; IAT: "Imobile Airtrapping" appearance

Table 3: Selection algorithm for high-Resolution examinations in the emergency department of febrile patients who had liver tumor pathology surgery.

Liver tumor lesions PreO =< 4 cm (65.33%)			Liver tumor lesions PreO >4 cm (16.32%)	
PO US signs of sequelae type	Suspicious US signs requiring CT		PO US signs of sequelae type	Suspicious US signs requiring CT
The 7 days – 3 months PO interval				
Residual C with size reduction	C that increases in size		Residual C with size reduction	C that increases in size
Pericavitary inhomogeneity with IAT, SA	C with debris		Pericavitary inhomogeneity with IAT, SA	C with debris
Intracavitary IAT	Inhomogeneity with mobile air artifact		Intracavitary IAT	Inhomogeneity with mobile air artifact
The 3–6 months PO interval				
SA with sizereduction, with IAT	Inhomogeneity with mobile air artifact		Residual C with size reduction	C that increases in size
	Persistence of the C, with detritus		Pericavitary inhomogeneity with IAT, SA	C with debris, mobile air artifact
			Intracavitary IAT	Inhomogeneity with mobile air artifact
The 6–9 months PO interval				
SA with IAT	Inhomogeneity with mobile air artifact		Residual C with size reduction	Inhomogeneity with mobile air artifact
			Inomogenitate pericavitar cu IAT, AC	
Over 9 months PO				
SA with IAT	Inhomogeneity with mobile air artifact		SA with IAT	Inhomogeneity with mobile air artifact

Abbreviations: PreO: Preoperative; PO: Postoperative; US: Ultrasonographic; C: Cavity; SA: Scarring Aspect; IAT: "Imobile Airtrapping" aspect

normal liver structure-like impedance can frequently be the source of a diagnostic error in the 2D examination mode.

The gastroenterology guidelines [6] recommend the ultrasonography for the monitoring of liver pathology, in particular for the detection of tumor diseases, and high – resolution examination in case of uncertain ultrasonographic examination.

The practice of intraoperative ultrasonography becomes a safety element for the surgeon, reducing the risk of recurrences, highlighting the postoperative post resection aspect that favors the postoperative dynamic monitoring [7]. It is also important to delimit by intraoperative ultrasound the area of peri-resection edema that needs to be followed, because the evolving postoperative aspect can create problems of differential diagnosis [8]. In the group of examined patients, a progressive reduction of perilesional edema and cavity size was observed.

Postoperatively, the presence of the cavitary area and the "immobile air trapping" artifact described in the study, but also in the literature [1], associated with the comparative dynamic analysis of the resection area reduces the incidence of false diagnosis of postoperative septic complication. The incidence of postoperative abscess is low (1.9%) according to the studies [1], this was also observed in the retrospective analysis performed (6.12%). The difference in incidence is most likely due to the small group of patients in our study (49 *vs.* 385 patients).

The sensitivity and specificity of 2D ultrasonographic monitoring is influenced by the pre – existing liver echo structure to neoplasic nodules and its changes. The definite diagnosis in these cases requires contrast – enhanced ultrasound or contrast computer tomography/ magnetic resonance imaging to elucidate the tumor nature [1,9].

In patients with abdominal pain (50% to 75%) and febrile syndrome (70% to 90%), ultrasonography is the most useful and rapid method of diagnosing a liver abscess, allowing rapid therapeutic intervention and reducing mortality [7]. Thus, the experience in ultrasonographic examination and the image library become support tools, in a pandemic period, for the creation of an emergency decision – making algorithm for the selection of patients with operated liver tumor pathology, with uncertain US aspects for CT examination.

Conclusion

In conclusion, ultrasonographic evaluation by zero radiation

character and good cost – benefit ratio, for current health systems in Romania, is the first line examination in the diagnosis of exclusion of a liver infectious process in febrile patients with liver tumor pathology operated using coagulation necrosis technique.

Ultrasonographic examination performed by experienced physicians who know and integrate dynamic ultrasonographic aspects with structural changes in the liver parenchyma caused by the introduction of intraoperative coagulation necrosis devices may reduce the number of high – resolution (CT/MRI) indications of examinations, with impact in reducing radiation exposure but also contamination in pandemic conditions.

Acknowledgment

Emergency nurses who work in Imagist Department – Ultrasonography and help us to select patients and images from gallery. Our colleagues Raluca Finta, MD who put together medical information.

Authors Contribution

Conceptualization of the research study was carried out by AG. Methodology was achieved by AG, RB. Formal analysis was conducted by AG, RT, EML and NH; investigation by AG, RT, SM, EML. Resources were accrued by AG, RT, RB and NH; writing - original draft preparation was carried out by AG. Writing - review and editing was performed by AG, RT, RB, NH, EML, SM; supervision by RB and AG. All authors have read and agreed to the final version of the manuscript.

Ethics Approval and Consent to Participate

The study was conducted according to the Declaration of Helsinki and General Data Protection Regulation (Data Protection Directive 95/46/ec 2018).

References

1. Su XF, Li N, Chen XF, Zhang L, Yan M. Incidence and risk factors for liver abscess after thermal ablation of liver neoplasm. Hepat Mon. 2016;16(7):e34588.
2. Rapaccini GL. Clinical-pathological classification of liver malignancies. In: Bartolozzi C, Lencioni R, editors. Liver Malignancies: Diagnostic and Interventional Radiology: Springer. 1999;11-13.
3. Bhattacharjya S, Aggarwal R, Davidson BR. Intensive follow-up after liver resection for colorectal liver metastases: Results of combined serial tumour marker estimations and computed tomography of the chest and abdomen - a prospective study. Br J Cancer. 2006;95(1):21-6.
4. Guo-Qiang Mo, Xue-Ming Liu. Ultrasonographic findings at the resected area after hepatectomy. Hepatobiliary Pancreat Dis Int. 2006;5(3):401-5.
5. Bachler P, Baladron MJ, Menias C, Beddings I, Loch R, Vargas M, et al. Multimodality imaging of liver infections: Differential diagnosis and potential pitfalls. Radio Graphics. 2016;36(4):1001-23.
6. Marrero JA, Kulik LM, Sirlin CB, Zhu AX, Finn R, Abecassis MM, et al. Diagnosis, staging, and management of hepatocellular carcinoma: 2018 practice guidance by the American Association for the Study of Liver Diseases. Hepatology. 2018;68(2):723-50.
7. Grondona P, Meola C, Floris F, Masini R, Brignole E, Quidaciolu F. Ultrasound-guided liver resection: Early experience in a district general hospital. J Ultrasound. 2008;11(4):162-7.
8. Kruskal JB, Kane RA. Intraoperative US of the liver: Techniques and clinical applications. Radio Graphics. 2006;26(4):1067-84.
9. Dupuy DE, Goldberg SN, Image-guided radiofrequency tumor ablation: Challenges and opportunities—part II. J Vasc Interv Radiol. 2001;12(10):1135-48.