Clinics in Surgery

Case Report
Published: 21 May, 2016

Surgical Management of Peroneal Nerve Injury in Complex Sports Knee Injuries

Nath RK and Somasundaram C*

Department Brachial Plexus and Peripheral Nerve Surgery, Texas Nerve and Paralysis Institute, USA

Abstract

Objective: Our study analyzes 6 operative knee-level peroneal nerve lesions and foot drop patients treated at our clinic.

Introduction: The most frequent lower extremity injuries resulting from sports and related recreational activities is peroneal nerve entrapment. This can be acute or can arise due to chronic overuse. Numerous etiologies have been identified. However, compression remains the main cause, which generally results in acute complete or partial foot drop.

Method and Patients: This is a retrospective study of a series of 6 consecutive patients with foot drop resulting from sports and related injuries. For all patients, the preoperative clinical examination and electromyographic evaluation were performed. Nerve conduction and clinical function results showed injury to the peroneal nerve. Peroneal nerve decompression was performed in these patients in our study between 2007 and 2014.

Results: Overall statistically significant clinical and functional improvement from pre-operative MRC grade 2.5 ± 0.8 to post-operative MRC grade 4.0 ± 0.9 (P value 0.007) was achieved.

Conclusion: Results of peroneal nerve decompression in sports injury foot drop patients in our study produced remarkable clinical and functional recovery in foot anti-gravity (MRC grade 4.0) and walking gait.

Keywords: Sports injuries; Peroneal nerve; Decompression; Knee injury; Foot drop

Introduction

Sports injuries to the lower limbs can be acute or can occur due to chronic overuse. The most common cause of sports injuries are gymnastics, soccer, baseball, volleyball, football and running. Peroneal nerve lesion is the most frequent and common in the lower extremities and has a worse prognosis than those in the upper extremities [1,2]. This is the third most common entrapment in the body [3] and causes antigravity weakness to the tibialis anterior muscle, resulting in foot drop. This has devastating effects on patient activities, especially their profession in athletes. Typically, such lesions are difficult to manage successfully. The method of treatment is dependent on the mechanism and degree of the nerve injury.

Predicting and achieving spontaneous recovery of peroneal nerve function can be difficult. Usually, it appears as an entrapment neuropathy and the symptoms can be improved by traditional treatments. Some of these knee and foot drop injuries are complicated and surgical exploration is necessary [4]. These may not be as easily dealt with if surgery is delayed beyond 3-4 weeks [5]. We report here the results of a retrospective analysis of surgically managed 6 patients, who had knee injuries and foot drop resulting from sports and related recreational activities.

Method and Patients

This is a retrospective study of a series of 6 consecutive patients with knee injuries and foot drop. These patients in our present study had sports-related traumatic injuries associated with football, volleyball, soccer and running. All 6 patients underwent peroneal nerve decompression, micro-neurolysis, neuroplasty with us between 2007 and 2014. For all patients, the preoperative clinical examination and electromyographic evaluation were performed. Nerve conduction and clinical function results showed injury to the peroneal nerve in all 6 patients. Preoperative duration of injury and foot drop reported by the patients was recorded (between 2 weeks and 4 months). Further patient demographics, including age, sex, mechanism and extent of the injury are provided

OPEN ACCESS

Correspondence:
Rahul Kumar Nath, Department Brachial Plexus and Peripheral Nerve Surgery, Texas Nerve and Paralysis Institute, 6400. Fannin st. Houston, TX-77030, USA,
E-mail: drnath@drnathmedical.com

Received Date: *15 Apr 2016*
Accepted Date*: 16 May 2016*
Published Date*: 21 May 2016*

Citation:
Nath RK, Somasundaram C. Surgical Management of Peroneal Nerve Injury in Complex Sports Knee Injuries. Clin Surg. 2016; 1: 1008.

Table 1: Grading of foot drop in patients resulting from sports injuries, who underwent peroneal nerve decompression.

Patient gender/ age	Cause of injury	Pre-op –Indication	Pre/ post-op	Toe Extension	Toe Flexion	Ankle Dorsi-flexion	Ankle Eversion	Plantar Flexion	Ankle Inversion	Post-op – Outcome
M/22	volleyball	Hyperextension injury of knee with partial ligament tears. Complete right peroneal nerve injury, clinically and electrically 2 x EMG's showed no recovery.	pre- op post- op	0 3	4+ 4+	0 3	0 3	4+ 4+	4+ 4+	Excellent improvement in peroneal nerve function, right foot eversion and dorsiflexin
M/29	Running	Weakness in left peroneal nerve distribution as well as EMG evidence of peroneal nerve injury at level of knee.	pre- op post- op	4 5	5 5	4 5	4 4+	4+ 5	4+ 5	Ongoing excellent strength in left foot.
F/28	Motorcyle Ride	External compression	pre- op post- op	1 4+	5 4+	0 4+	3+ 4+	5 5	5 4+	Outstanding normal looking result
M/21	Football	Rght knee injury, dislocation. EMG- common peroneal nerve traction	pre- op post- op	0 4	4+ 5	0 4+	0 5	4+ 4	5 5	Remarkable recovery
M/22	Football	Complete right peroneal nerve injury	pre- op post- op	0 3	4+ 4+	0 3	0 3	4+ 4+	4+ 4+	New eversion
M/20	Football	Right peroneal nerve injury	pre- op post- op	0 3	3 3	0 3	0 3	3+ 3+	4 4	Stable, excellent return of ankle function. New AG dorsiflexion

Duration 1 day – 4 months; Follow-up 6 – 18 months: pre-op MRC grade 2.5 ± 0.8; post-op MRC grade 4.0 ± 0.9 (P value 0.007).

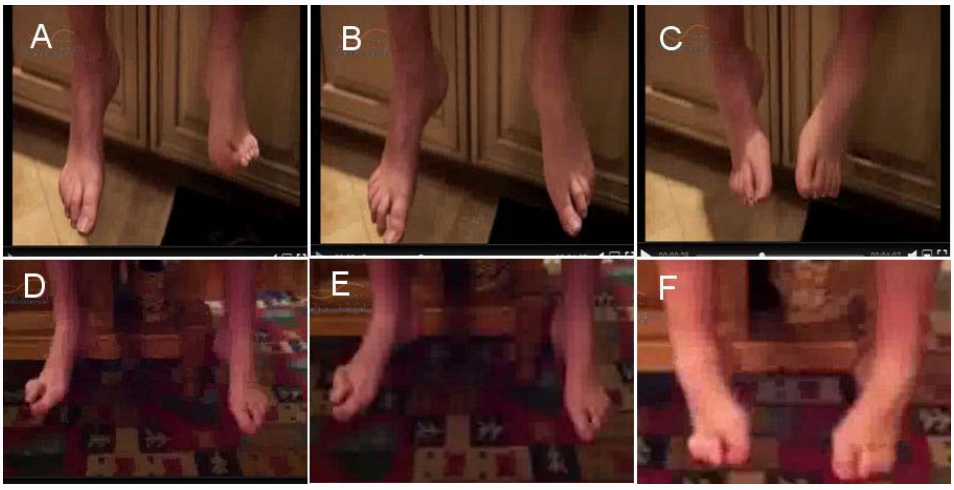

Figure 1: 21-year-old male patient with right peroneal nerve injury and foot drop.
Fell on sand while playing beach volleyball.
Upper panel, ABC: before surgery.
Lower panel, DEF: after surgery (peroneal nerve decompression, microneurolysis, neuroplasty).

in (Table 1).

Ankle eversion, inversion and dorsiflexion, toe extension, flexion and plantar flexion were clinically evaluated by the lead author (RKN) [6] using MRC scale for muscle strength pre- operatively and at least 6 months after surgery.

Statistical analysis

Statistical analysis was performed using Analyse-It plugin (Leeds, United Kingdom) for Microsoft Excel 2003 software. A P- value of < 0.05 was considered as statistically significant.

Results

Overall statistically significant clinical and functional improvement from pre-operative MRC grade 2.5 ± 0.8 to post-operative MRC grade 4.0 ± 0.9 (P value 0.007) was achieved. The improvement of the injured foot movement for each of these 6 patients is shown separately in Table 1 and Figure 1, and walking Gait in Figure 2 (from videos).

Patient 1, a 21-year old male volleyball player had an acute injury and had "0" muscle strength in MRC grade for toe extension, ankle eversion and dorsiflexion before surgery. "0" indicates no movement. EMG also indicated a complete right peroneal nerve injury. This patient achieved ant-gravity, about 3 in MRC grade after the surgery.

Patient 2, a 29-year old male runner had reported weakness and pain in his left knee and numbness in the lower leg. This might be the



Figure 2: 21-year-old male patient with right peroneal nerve injury and foot drop.
Fell on sand while playing beach volleyball.
Upper panel, walking Gait before surgery.
Lower panel, walking Gait after surgery (peroneal nerve decompression, microneurolysis, neuroplasty).

Table 2: Peroneal and tibial nerve innervating muscles and their functions.

Nerve	Muscles	Functions
Tibial nerve	the gastrocnemius, soleus, tibialis posterior, fibularisbrevis and longus, flexor hallucislongus, flexor digitorumlongus and plantar.	toe flexion, plantar flexion and ankle inversion
Peroneal nerve	tibialis anterior, extensor digitorumlongus, and extensor hallucislongus.	toe extension, ankle eversion and dorsiflexion

impact of the continuous physical activity (running) and there was no accident involved. EMG data confirmed the left peroneal nerve injury. Patient 3, a 28-year old female patient had external compression of left peroneal nerve resulting from a motorcycle ride. Patients 4, 5 and 6 are all male football players, had foot drop due to acute injury.

Overall, in all 5 acute injury patients (except patient # 2, chronic use), toe extension, ankle eversion and dorsiflexion (foot movement category 1) were severely damaged (mean MRC 2/5) due to peroneal nerve involvement (Table 1 and 2) when compared to the other foot movements, toe and plantar flexion and ankle inversion (tibial nerve functions, category 2), mean MRC 4/5 (Table 1 and 2). The recovery after peroneal nerve decompression was 3.5/5 and 4+/5 muscle strength in foot movements in category 1 and 2 respectively.

All 5 acute injury patients in our study had MRC grade of 4 to 5 pre-operatively, in performing ankle inversion, toe and plantar flexion in spite of their poor performance in toe extension, ankle eversion and dorsiflexion (mean MRC 2/5). This pre-operative clinical evaluation indicates that these patients did not have tibial nerve injury. Therefore, in addition to EMG data, this confirms that foot drop in these patients was caused by peroneal nerve injury.

The improvement after peroneal nerve decompression was MRC 3.5/5 from MRC 2/5 in terms of toe extension, ankle eversion and dorsiflexion in these 5 patients with acute injury, whereas tibial nerve muscle movements such as ankle inversion, toe and plantar flexion remained the same (MRC 4+/5) after the surgery as there was no tibial nerve involvement.

Discussion

Continuous physical activities such as walking, cycling or running and the high impact sports activities involving lower limbs can damage a normal joint. We [6] have previously reported the successful outcome of nerve transfer to the deep peroneal nerve in 14-foot drop patients. Among all knee injury and foot drop patients treated at our clinic between 2008 and 2014, we present here only injuries resulted from sports and related recreational activities, and who were candidates for peroneal nerve decompression. Peroneal nerve injury is a well-identified complication in and around the knee region in sports activities. Some acute and severe sports injuries have the same pattern of injury as motor vehicle accidents [5], for example, the female motorcycle rider in our present study.

Though, patients benefit from nonsurgical treatments, surgical decompression has been considered for stubborn patients and those with compressive masses, acute lacerations, or severe nerve conduction changes [7]. Results of the surgical decompression and neurolysis [8,9] have been reported typically with favorable outcomes. Gosk et al. [9] demonstrated efficacy of 68.5% (61 of 89 patients) by neurolysis in lesions to lower extremities. Thoma et al. [10] described significant improvement of ankle dorsiflexion in 19 of 20 patients with common peroneal nerve palsies treated exclusively with peroneal nerve decompression. A strong correlation between ultimate therapeutic results and timing of the operation was reported [8,9]. Further, encouraging results were reported when the delay was not more than 8 months [8,9]. Preoperative duration of injury and foot drop reported by our patients was recorded (between 2 weeks and 4 months). Tendon and nerve transfers are used only in the setting of failed decompression or for patients with a poor prognosis for nerve recovery [6,7].

Conclusion

Overall statistically significant clinical improvement to MRC grade 4.0 ± 0.9 (P value 0.007) was achieved after peroneal nerve decompression, micro-neurolysis and neuroplasty. Functional recovery was remarkable in foot anti-gravity and walking gait in these patients.

References

1. Sedel L. The surgical management of nerve lesions in the lower limbs. Clinical evaluation, surgical technique and results. Int Orthop. 1985; 9: 159-170.
2. umble TE, Vanderhooft E, Khan U. Sural nerve grafting for lower extremity nerve injuries. J Orthop Trauma. 1995; 9: 158-163.
3. MB, Wilbourn AJ. Common peroneal mononeuropathy: a clinical and electrophysiologic study of 116 lesions. Neurology. 1988; 38: 1723-1728.
4. Y, Sakakida K. Sports and peripheral nerve injury. Am J Sports Med. 1983; 11: 420-426.
5. ddle BC, Bidwell TA, Chapman JR. Knee dislocations: where are the lesions? A prospective evaluation of surgical findings in 63 cases. J Orthop Trauma. 2003; 17: 198-202.
6. RK, Lyons AB, Paizi M. Successful management of foot drop by nerve transfers to the deep peroneal nerve. J Reconstr Microsurg. 2008; 24: 419-427.

7. C, Roth C, Scott B. Peroneal Nerve Palsy. Evaluation and Management. J Am Acad Orthop Surg. 2016; 24: 1-10.

8. J, Rutowski R. Penetrating injuries to the nerves of the lower extremity: principles of diagnosis and treatment. Ortop Traumatol Rehabil. 2005; 7: 651-655.

9. J, Rutowski R, Rabczynski J. The lower extremity nerve injuries - own experience in surgical treatment. Folia Neuropathol. 2005; 43: 148-152.

10. A, Fawcett S, Ginty M, Veltri K. Decompression of the common peroneal nerve: experience with 20 consecutive cases. Plast Reconstr Surg 2001; 107: 1183-1189.

11. Moore KL (1992) Clinically Orientated Anatomy, Third Edition, Williams & Wilkins, Baltimore, pp.413, 464-466, 493-496.