



Severe Abdominal Dermatochalasis and Surgical Correction

Valeriano Vinci*, Andrea Lisa, Andrea Battistini, Benedetta Agnelli, Alessia Lozito, Luca Maione and Marco Klinger

Department of Medical Biotechnology and Translational Medicine, BIOMETRA, Reconstructive and Aesthetic Plastic Surgery School, Humanitas Clinical and Research Hospital, University of Milan, Italy

Clinical Image

We present the case of a 67-year-old woman who presented to our clinic complaining of a massive abdominal dermatochalasis due to her obesity (an excess of skin and adipose tissue localized in the abdominal area that limits the patients' mobility). The patient referred that her medical condition started more than 15 years prior to the presentation to the clinic and she didn't seek for medical attention since then. Her condition worsened throughout the years and during the last months she had to walk with a cart that could support her belly. A preoperative evaluation showed that there was no sign of abdominal hernia or rectus abdominis diastasis but the whole area suffered from an important abdominal lymphedema. The patient underwent abdominoplasty ("tummy tuck") to remove the excess of skin and adipose tissue and she recovered with no complications (Figure 1). Her quality of life improved tremendously after the procedure.

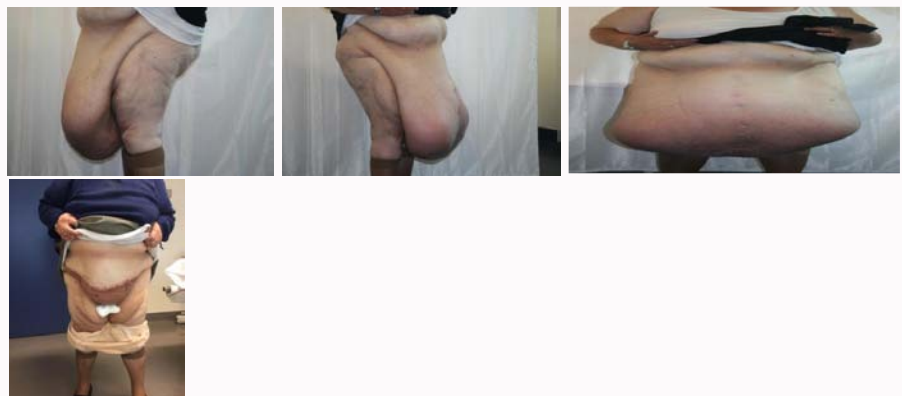


Figure 1: Underwent abdominoplasty ("tummy tuck") to remove the excess of skin and adipose tissue and she recovered with no complications.

OPEN ACCESS

*Correspondence:

Valeriano Vinci, Department of Medical Biotechnology and Translational Medicine, BIOMETRA, Reconstructive and Aesthetic Plastic Surgery School, Humanitas Clinical and Research Hospital, University of Milan, Via Manzoni 56, 20090 Rozzano, MI, Italy, E-mail: Valeriano.vinci@humanitas.it

Received Date: 22 Jul 2019

Accepted Date: 30 Jul 2019

Published Date: 02 Aug 2019

Citation:

Vinci V, Lisa A, Battistini A, Agnelli B, Lozito A, Maione L, et al. Severe Abdominal Dermatochalasis and Surgical Correction. *Clin Surg*. 2019; 4: 2530.

Copyright © 2019 Valeriano Vinci. This is an open access article distributed under the Creative Commons Attribution License, which permits unrestricted use, distribution, and reproduction in any medium, provided the original work is properly cited.