



Report a Case of Giant Thymolipoma of Mediastinum and Neck Which Initially Misdiagnosed as Liposarcoma on Core-Needle Biopsy

Manouchehr Aghajanzadeh^{1*}, Mesbah², Omidmosafai³, Arasteh Safat³ and Torabi³

¹Department of Thoracic Surgery, Guilan University of Medical Sciences, Rasht, Iran

²Department of Pathology, Guilan University of Medical Sciences, Rasht, Iran

³Inflammatory Respiratory Diseases and TB Research Center, Razi Hospital, Guilan University of Medical Sciences, Rasht, Iran

Keywords

Thymolipoma; Anterior mediastinum; Liposarcoma

Clinical Image

Thymolipomas are rare benign tumors, constituting one of the differential diagnoses of an anterior mediastinal mass. These tumors may run an indolent, asymptomatic course, often achieving massive dimensions before presentation. Once Symptomatic, respiratory symptoms predominate. We report a case of thymolipoma in a 30 years old male complaining of heaviness and constricting type of chest pain and neck swelling of 1 year duration. CT scan findings were a space occupying lesion in the anterior mediastinum and extend to right side of mediastinum, neck and left side

OPEN ACCESS

*Correspondence:

Manouchehr Aghajanzadeh,
Department of Thoracic Surgery, Guilan
University of Medical Sciences, Rasht,
Iran,
E-mail: maghajanzadeh2003@yahoo.
com

Received Date: 04 Aug 2016

Accepted Date: 04 Sep 2017

Published Date: 20 Sep 2017

Citation:

Aghajanzadeh M, Mesbah,
Omidmosafaii, Safat A, Torabi. Report
a Case of Giant Thymolipoma of
Mediastinum and Neck Which Initially
Misdiagnosed as Liposarcoma on
Core-Needle Biopsy. Clin Surg. 2017;
2: 1619.

Copyright © 2017 Aghajanzadeh

M. This is an open access article
distributed under the Creative
Commons Attribution License, which
permits unrestricted use, distribution,
and reproduction in any medium,
provided the original work is properly
cited.

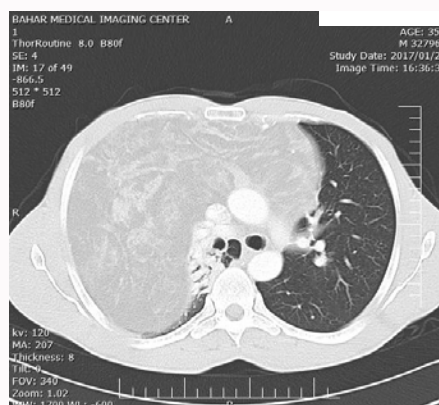


Figure 1: Showing CT scan of chest showing anterior mediastinal fatty tissue mass with strands and islands of soft tissue with extension to occupying total right hemithorax and to left hemithorax.

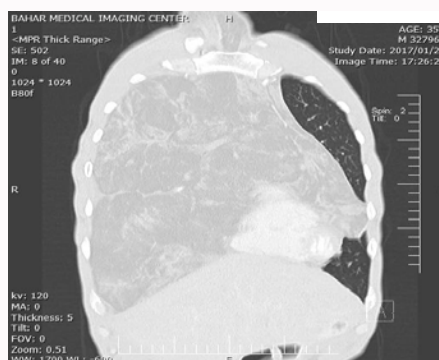

Figure 2: Showing Sagittal CT scan of chest showing a mass to occupying total right hemithorax and to left hemithorax with strands and islands of soft fatty tissue.

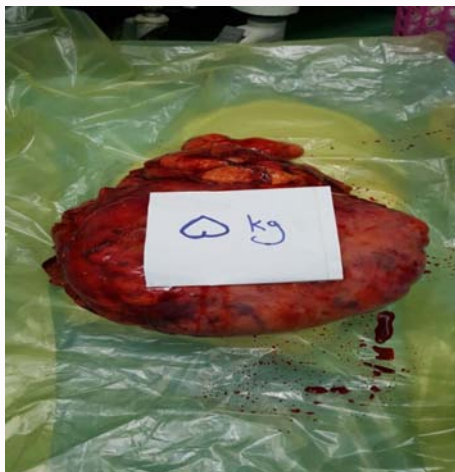


Figure 3: Showing Resected specimen: thymolipoma (macroscopic).

hemithorax. The tumor was completely excised through 'Postero lateral thoracotomy'. Histopathological examination confirms the diagnosis Thymolipoma. This is the second case we have reported from our institution (4).