Clinics in Surgery

Case Report
Published: 31 Mar, 2017

Replacement of Tendon with Allograft for the Management of a Recurrent Foot Ganglion Cyst

*Erin M Younce[1] and Jeffrey M Whitaker[2]**

[1]Department of Podiatric Surgery, Washtenaw Podiatry Group, USA

[2]Department of Podiatric Surgery, Cleveland VA Medical Center, USA

Abstract

The surgical management of dorsal foot ganglion cysts can be challenging. Recurrence of these cysts has been reported to be as high as 43%. For recurrent lesions arising from an articulation, approaches for reinforcing capsular tissue have been reported. In this report, we describe a technique for addressing a recurrent lesion arising from an extensor tendon sheath. The technique involved cyst excision and tendon replacement with a segment of sheath-less human allograft tendon. At 6 months, the patient was recurrence-free.

Keywords: Ganglion; Recurrence; Allograft

Introduction

Ganglion cysts are common mucin-containing tumors which arise from synovial tissue structures such as tendon sheaths and joints, but intraosseous origins have also been reported [1]. Despite their benign histology, ganglion cysts can be problematic. Pain associated with a mass on the dorsum of the foot can make ambulation and wearing shoes difficult [2]. Cases of nerve impingement have also been described [1].

Initial conservative management may include observation and padding for comfort, aspiration of the cyst contents, and injection of corticosteroid into the cyst. Surgical excision is reserved for persistent cysts for which conservative therapy is unsuccessful [2]. Surgical excision does not guarantee a cure with reported rates of recurrence for foot and ankle lesions ranging from 7-43% [1-5]. Furthermore, successful revisional excision can be complicated by scarring and distortion of tissue planes from previous surgeries.

Reports exist describing the use of adjacent retinacular or muscle tissue at the site of recurrent ganglion cyst excision [2,6]. These "tissue buttressing" approaches are aimed at preventing the recurrence of a cyst arising from a joint. The authors were unable to find similar approaches for recurrent ganglion cysts which arise from synovial tendon sheaths. In this case report, we describe the resection of involved tendon and sheath followed by tendon allograft replacement for a recurrent ganglion cyst associated with the extensor digitorum longus tendon.

Case Presentation

A 43-year old female presented to our clinic with a painful, recurrent mass on the dorsum of

Figure 1: Clinical appearance of recurrent ganglion cyst.

OPEN ACCESS

Correspondence:
Jeffrey M Whitaker, Department of Podiatric Surgery, Cleveland VA Medical Center, 10701 East Boulevard, 112 (W), Cleveland, OH 44106, USA, Tel: (216) 791-3800 x3591; E-mail: Jeffrey.Whitaker2@va.gov

Received Date: *10 Jan 2017*
Accepted Date*: 24 Mar 2017*
Published Date*: 31 Mar 2017*

Citation:
Younce EM, Whitaker JM. Replacement of Tendon with Allograft for the Management of a Recurrent Foot Ganglion Cyst. Clin Surg. 2017; 2: 1394.

Figure 2: Plain film radiographs.

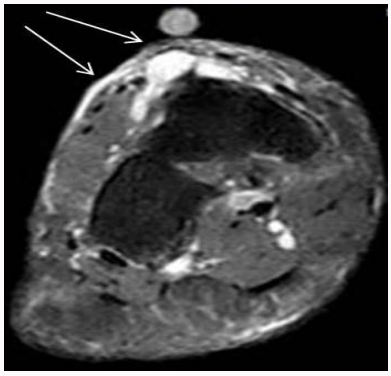

Figure 3: Coronal T2 image of recurrent ganglion cyst. Note EDL tendons slips 2-5 lateral to the cystic lesion.

Figure 4: Intraoperative appearance of ganglion cyst. Extensor digitorum longus tendon is seen lateral to the lesion.

her right foot. Two prior excisions of this mass revealed a diagnosis of ganglion cyst and resulted in recurrence of the lesion. Her past medical history was non-contributory to her foot pain/pathology.

On exam, a healed curvilinear cicatrix was present at the dorsal mid foot. A painful, non-mobile, non-pulsatile, and illuminating subcutaneous mass was found at the dorsal mid foot (Figure 1). A positive Tinel's sign was also elicited.

Standard radiographs revealed a dorsal outline of the mass (Figure 2). Non-contrast magnetic resonance imaging (MRI) was obtained. Figure 3 is a coronal T2 image through the mid foot showing a multi-loculated, fluid-filled mass associated with the individual extensor digitorum longus (EDL) tendon slips.

The patient was taken to the OR for a third attempt at surgical excision of the painful ganglion cyst. A longer curvilinear incision was made just lateral to the previous incisions and was deepened down to the subcutaneous level. Embedded in scar tissue, the cyst

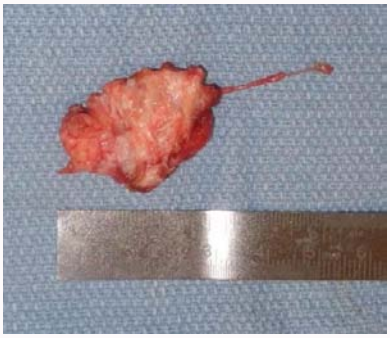

Figure 5: Excised ganglion cyst (2 × 2.5 × 1.5cm).

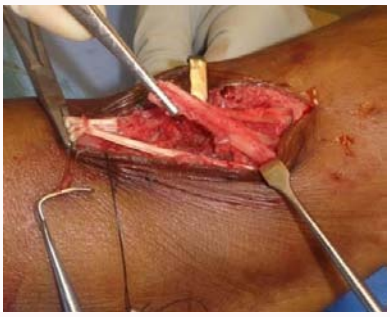

Figure 6: Resection of EDL tendon slips 2-4. Proximal tendon stumps were sutured together prior to resection.

Figure 7: Placement of Tibialis Anterior tendon allograft.

was identified and found to be emanating from EDL tendon slips 2-4 (Figure 4). Further dissection was carried out, allowing the intact neurovascular bundle to be retracted medially throughout the course of the procedure. The cyst was dissected from the tendon slips (Figure 5). EDL tendon slips 2-4 were then respected to include overlying sheath (Figure 6). Prior to tendon slip resection, the proximal and distal stumps were tagged with absorbable suture. Next, a tibia is anterior tendon allograft was cut to size and sutured to the proximal and distal stumps of the EDL tendon slips 2-4 with absorbable suture (Figure 7).

Microscopic evaluation of the specimen resulted in a diagnosis of ganglion cyst and fibrous connective tissue with degenerative changes. Postoperatively, the patient remained non-weight-bearing in a posterior splint for 3 weeks. Active range of motion exercises at 3 weeks revealed intact extension of digits 2-4. At 6 months, the patient has not had a recurrence of her cyst.

Discussion

Ganglion cysts are the most common soft tissue masses in the foot

[7]. Pathogenesis has typically been described as a result of trauma, whether acute or repetitive [8]. Most authors also believe they are the result of myxoid degeneration in connective tissues such as joint capsule or tendon sheath [4,9]. Hoon "et al." [10] reported the most common sites as those with ligament us or capsular stress.

Recurrence is common following conservative care with a rate as high as 63% [3]. However, as mentioned above, recurrence following surgical excision has been reported as high as 43% [1-5]. Meticulous surgical technique, including identifying and addressing the pedicle, is thought to be important in avoiding recurrence [6]. In addition, it is recommended that nearby degenerative/attenuated joint capsule or tendon sheath be removed [7].

Attempts to achieve complete ganglion resection and tract obliteration can result in damage to or exposure of adjacent structures as well as the structures from which the cyst arises [3-5]. Therefore, many excisions are likely under-dissected, resulting in a higher recurrence rate.

In addition, achieving adequate soft tissue coverage is a challenge as tissues become deficient and scarred from previous excisions. Advanced wound techniques including flaps have been described in recent literature for the wound complications that can result from revisional cyst surgery [2].

Conclusion

We present a case describing the use of a novel approach for addressing recurrent ganglion cysts of tendon sheath origin in the foot. Our patient underwent complete resection of the recurrent structure of origin, the extensor digitorum longus tendon and sheath, followed by reconstruction with human allograft tendon. Our patient remains free of cyst recurrence. Therefore, the authors believe this is a viable option for recurrent ganglion cysts originating from tendon sheath as well as an approach deserving of additional investigation.

References

1. Slavitt JA, Beheshti F, Lenet M, Sherman M. Ganglions of the foot: a six-year retrospective study and a review of the literature. J Am Podiatry Assoc. 1980;70(9):459-65.
2. Kiehn M, Gutowski K. A Recurrent Foot Ganglion Managed with Extensor Digitorum Brevis Muscle Flap Coverage. J Foot Ankle Surgery. 2004;43(6):423-5.
3. Pontious J, Good J, Maxian SH. Ganglions of the foot and ankle. A retrospective analysis of 63 procedures. J Am Podiatr Med Assoc. 1999;89(4):163-8.
4. Rozbruch SR, Chang V, Bohne WH, Deland JT. Ganglion cysts of the lower extremity: an analysis of 54 cases and review of the literature. Orthopedics. 1998; 21(2):141-8.
5. Kliman ME, Freiberg A. Ganglia of the foot and ankle. Foot Ankle. 1982;3(1):45-6.
6. Citron N1, Perry A, Wardle N. Fascial flap for recurrent ganglion. Chir Main. 2004;23(1):24-6.
7. Kirby EJ, Shereff MJ, Lewis MM. Soft Tissue Tumors and Tumor-like Lesions of the Foot, an analysis of 83 Cases. J Bone Joint Surgery Am. 1989;71(4):621-6.
8. King ESJ. The Pathology of Ganglion. Aust N Z J Surgery.1932;1:367-81.
9. Wu KK. Ganglions of the foot. J Foot Ankle Surg. 1993;32(3):343-7.
10. Ahn JH, Choy WS, Kim HY. Operative treatment for ganglion cysts of the foot and ankle. J Foot Ankle Surg. 2010;49(5):442-5.