Clinics in Surgery

Case Report
Published: 12 May, 2016

Postoperative Infection Caused by a Resorbable Plate used to Treat a Zygomatic Fracture

Sukegawa S[1]*, Kanno T[1,2], Kawai H[3], Shibata A[1], Sukegawa-Takahashi Y[1] and Furuki Y[1]

[1]Division of Oral and Maxillofacial Surgery, Kagawa Prefectural Central Hospital,Japan

[2]Department of Oral and Maxillofacial Surgery, Shimane University Faculty of Medicine, Shimane, Japan

[3]Department of Oral Pathology and Medicine, Okayama University, Graduate School of Medicine, Dentistry and Pharmaceutical Sciences, Japan

Abstract

A 58-year-old female patient was referred to our division of Oral and Maxillofacial Surgeryby a general dental practitioner with swelling symptoms in the left cheek. Five months earlier, she had fractured her left zygomatic bone, which was fixed using a resorbable plate. A maxillofacial computed tomographic scan taken upon the first visit showed a clear swelling of the soft tissue next to the left maxillary sinus and a maxillary sinusitis. In addition, the plate at the zygomaticomaxillary buttress showed bone resorption surrounding the plate and the screws, possibly because of an infection affecting the area around both the plate and the screws. These were removed, and their molecular weight and average molecular weight measured following extraction. These measurements showed that the plate and the screws had progressively degraded. All symptoms immediately diminished after the operation and no evidence of infection was observed after 3 months after the operation.

Keywords: Resorbable plate; Postoperative infection; Molecular weight

Introduction

Maxillofacial fractures are commonly fixed using titanium mini plates because they are strong, easy to handle, and are not prone to dimensional changes [1,2]. However, fracture fixation using titanium plates present some disadvantages, including potential difficulties associated with the subsequent removal surgery, facial growth [3,4], thermal sensitivity [5,6], and plate migration [7,8], ultimately leading to the development of resorbable bone fixation devices as a trend.

Bioresorbable plates are designed to be absorbed by the surrounding tissue through chemical interactions; therefore, negative foreign body reactions and infection throughout the resorption process are theoretically possible [5]. However, there are little complications involved and it is used by clinicians as a major device [9,10].

This report presents a case of infection, following zygomatic fracture fixation using a resorbable plate, suspected of being caused by the resorption process.

Presentation of Case

In June 2014, a 58-year-old female patient who did not present any note worthy past medical condition was referred to our division of Oral and Maxillofacial Surgery, Kagawa Prefectural Central Hospital, Takamatsu, Kagawa, Japan by a general dental practitioner because of swelling

Figure 1: (A) Slight facial asymmetry observed on the left side of the face. (B) Intraoral photographs showing the fistulae connected with the maxilla zygoma in the gingivobuccal area of the left maxilla.

OPEN ACCESS

***Correspondence:**
Shintaro Sukegawa, Division of Oral and Maxillofacial Surgery, Kagawa Prefectural Central Hospital, 1-2-1, Asahi-cho, Takamatsu, Kagawa 760-8557, Japan, Tel: +81 87 811 3333; Fax: +81 87 802 1188; E-mail: gouwan19@gmail.com

Received Date: *14 Apr 2016*
Accepted Date*: 06 May 2016*
Published Date*: 12 May 2016*

Citation:
Sukegawa S, Kanno T, Kawai H, Shibata A, Sukegawa-Takahashi Y, Furuki Y. Postoperative Infection Caused by a Resorbable Plate used to Treat a Zygomatic Fracture. Clin Surg. 2016; 1: 1002.

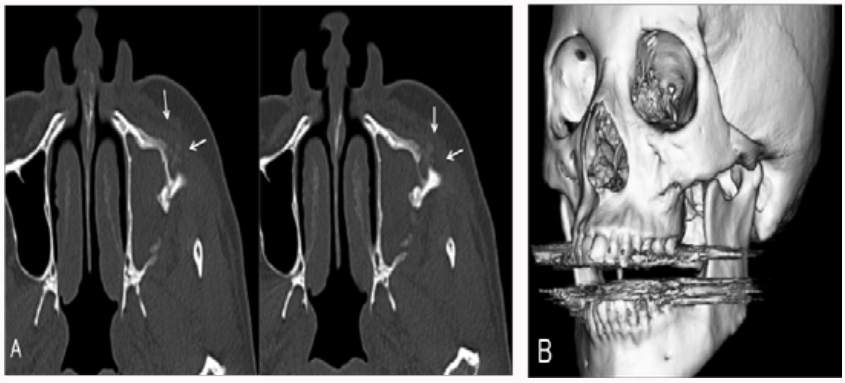

Figure 2: Computed tomography images. (A) Axial soft tissue window image showing a cystic lesion, extending from the left maxillary alveolar area to the maxillary sinus. (B) The fracture had sufficiently recovered; however, the zygomaticomaxillary bone surrounding the plate was absorbing it.

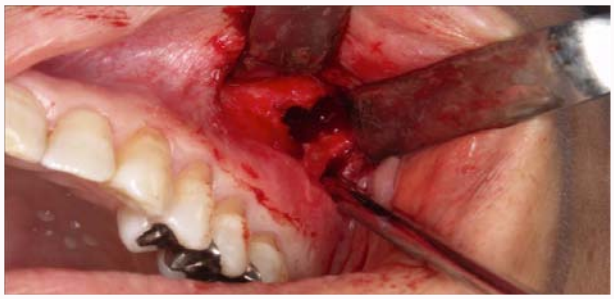

Figure 3: Bone resorbance surrounding the extracted plate continued toward the maxillary sinus.

Figure 4: (A) Postoperative findings of the patient 3 months after surgery showing no evidence of swelling. (B) Intraoral photographs showing no fistula the healing of normal mucosa.

in the left cheek. Five months earlier, the patient underwent surgery to fit a Lactosorb® 1.5 resorbable fixation system (Lorenz Surgical, Jacksonville, FL, USA) to fix a zygomatic bone fracture at another general hospital. The patient never suffered any discomfort or presented any problems in the operative site before the fracture. Osteosynthesis was achieved by a fixation technique using three points along to the orbital rim, the frontozygomatic suture, and the zygomaticomaxillary buttress. During her first visit to the general dental practitioner, an intraoral examination revealed the presence of pus, discharged from the gingivobuccal area (Figure 1). Furthermore, a probe showed that the bone could be easily reached. A maxillofacial computed tomographic scan taken during the first visit showed as welling of the soft tissue next to the left maxillary sinus and a maxillary sinusitis. In addition, the plate at the zygomaticomaxillary buttress showed bone resorption surrounding the plate and the screws (Figure 2).

These clinical symptoms did not improve after initial treatment with Clarithromycin for 2 weeks, followed by Cefcapenepivoxil hydrochloride hydrate for 2 weeks together with continuous local irrigation. Based on these symptoms the patient was diagnosed with an infection caused by the fitted resorbable plate and screw, and the full removal of biomaterials was recommended. The patient was operated to remove the plate and the screws under local anesthesia. The operation involved a vestibular incision on the left side of the mandible to locate and remove the free resorbed plate and the screws on the buttress. In addition, the operative team cleaned the area of bone resorption surrounding the bioresorbable plate and the maxillary sinus front wall for abscess formation of the maxillary sinus (Figure 3). During the operation, we took samples from the affected area; *Streptococcus milits* and anaerobic bacteria were cultured from these samples. The patient reported an immediate relief of the symptoms after the operation, and no evidence of infection was detected after 3months of follow-up.

Measurement of the Molecular Weight

To measure the molecular weight (Mw) of the extracted plate and screws, they were dissolved in tetrahydrofuran. Gel permeation chromatography using a TOSOH Build-up GPC system 8020 and a TOSOH Co, Japan) and a TSK-GELGMHHR-H (TOSOH Co, Japan) was used to estimate the molecular weight. This technique is able to separate polymers based on their size. Polystyrene (SM-105 by Showa Denko Co, Japan) was used for Mw calibration. For comparative purposes, the molecular weight of an intact Lactosorb® plate and screws were also measured following the same protocol.

The average molecular weight (Mn) was calculated using the following equation:

$$Mn=\Sigma (Mi \cdot Ni)/\Sigma Ni$$

Table 1: Average molecular weight and weighted average molecular weight of the removal plate and the screws, and an intact plate and screws.

No.	Specimen name	Number average molecular weight	Mn pace of decrease	Weight average molecular weight	Mw pace of decrease
		Mn	(%)	Mw	(%)
1	Intact screw	4.74×10^4		1.21×10^5	
2	Intact plate	4.81×10^4		1.16×10^5	
3	Removal screw	2.01×10^4	58	5.27×10^4	56
		2.19×10^4	52	5.59×10^4	54
4	Removal plate	2.28×10^4	53	5.36×10^4	54

Where Mi represents the molecular weight and Ni the number of numerators of the polymer.

The weighted average molecular weight (Mw) was calculated using the following equation.

$Mw=\Sigma (Mi2\cdot Ni)/\Sigma(Mi\cdot Ni)$

The plate removed 5 months after the initial surgery showed an average molecular weight and a weighted average molecular weight of 2.28×10^4 and 5.36×10^4, respectively. This represents a 53% decrease in Mn and a 54% decrease in Mw compared with an intact plate. Mn and Mw of the two screws removed were 2.01×10^4, and 2.19×10^4, and 5.27×10^4, and 5.59×10^4, respectively. These values indicated that Mn decreased by 58% and 54% for the first and second screw, respectively, and Mw had decreased by 56% and 54% compared with intact screws (Table 1).

Discussion

Resorbable Osteosynthes is systems were well developed to replace titanium fixation systems in craniofacial, oral, maxillofacial, plastic, and reconstructive surgery [1,2]. The resorbable materials used are ideally able to meet the biomechanical demands and to provide enough initial strength; however, these materials are able to degrade in a predictable manner throughout the healing process, providing sufficient strength and biomechanical stability to ensure the full healing of the fractured section. This resorption process has the added advantage of eliminating the need to remove the plate or the screws because no deleterious bodily response is associated with the presence of these materials or the resorption process [11].

The resorbable materials are designed to undergo a biphasic degradation process, including an early degradation step via hydrolysis of ester bonds [9,12]. The resulting degradation products subsequently crystallize and undergo a secondary hydrolysis, which strongly determines the rate of degradation of the material [12]. Throughout this process, the molecular weight of the material progressively decreases to eventually disappear. This degradation process is associated with a decrease in polymer strength [11], a reduction in molecular weight, and strength and mass loss. The implants lose the clinical biomechanical properties long before the loss of a significant amount of mass. The final end products of this degradation process, CO_2 and H_2O, are ultimately metabolized by the liver [9]. In this case, a LactoSorb (Lorenz/Biomet Inc.) bioresorbable system was used, which was composed by a substantially amorphous linear copolymer and consisted of 82% PLLA and 18% PGA. This material is able to retain 70% of its initial strength for the first 6–8 weeks, and it has been reported to dissolve entirely within the first year [13]. In this case, the patient had healed well after 5 months, and the bioresorbable system appeared to be efficient as Osteosynthesis material. However, bone resorption was observed around the bioresorbable plate and the screws fitted to the zygomatic and the maxillary bones. Inflammation could be expected for those cases where the degradation rate is too high and debris particles are produced faster than the body can tolerate [14]. The strong inflammatory reaction in the implantation site observed in this case was possibly caused by an increase in degradation products. This degradation probably caused the disintegration of the implanted materials, leading to the infiltration of the polymer into the adjacent tissues, overwhelming local clearance mechanisms. The molecular weight of the removed plate was 53% lower (58 and 52% lower for the screws) compared with intact plates, indicating that the absorption of the Osteosynthesis material had progressed as expected. The severe inflammation reaction observed could have led to periimplant osteolysis. In addition, the mobility of the plate and the screw as a result of the bone resorption could have further exacerbated the maxillary infection. A buccal buttress requires an occlusal stress. Resorption of a plate progresses 5 months postoperatively and the plate strength decreases. Because an occlusal force is recovered 2 months postoperatively for zygomatic fractures [15], it may lead to instability of a plate by a strong occlusal stress. Therefore, during zygomatic fracture treatment, we have to consider buccal buttress of the resorptive plate in which strength temporally reduces. To prevent the plate surge by an incongruity, it is required to firmly fit a plate to a bone.

This plate system has been widely and successfully used as an Osteosynthesis material [9]. In this case, the same plate system was used for other sites, such as the orbital rim and the zygomaticofrontal suture; however, bone resorption was only observed in the zygomaticomaxillary suture, connected to the side of the oral cavity. The presence of an oral *Streptococcus sp*. infection suggests an oral origin of the infection. This bacterial infection may have promoted the resorption of the bone surrounding the plate system, worsening the situation. Although inflammation by a foreign-body reaction occurs, there is generally little bacterial infection at areas other than the oral cavity. Because the oral-cavity is always exposed to the oral origin bacteria, we should be cautious regarding infections occurring at a relatively early stage.

Conclusions

Here postoperative complications related to the biodegradation of resorbable materials are reported. This study shows that there is a need to widen our understanding on the characteristics and use of these resorbable materials based on clinical observations.

References

1. Bos RR. Treatment of pediatric facial fractures: The case for metallic fixation. J Oral Maxillofac Surg. 2005; 63: 382-384.
2. Eppley BL, Sadove AM. Effects of resorbable fixation on craniofacial skeletal growth: Modifications in plate size. J Craniofac Surg. 1994; 5: 110-114.
3. Eppley BL, Platis JM, Sadove AM. Experimental effects of bone plating in infancy on cranio maxillofacial skeletal growth. Cleft Palate Craniofac J. 1993; 30: 164-169.
4. Yaremchuk MJ, Fiala TGS, Barker F, Ragland R. The effects of rigid fixation on craniofacial growth of rhesus monkeys. Plast Reconstr Surg. 1994; 93: 1-10.
5. Eppley BL, Sparks C, Herman E, Edwards M, McCarty M, Sadove AM. Effects of skeletal fixation on craniofacial imaging. J Craniofac Surg. 1993; 4: 67-73.
6. Manson PN, Hoopes JE, Su CT. Structural pillars of the facial skeleton: An approach to the management of Le Fort fractures. Plast Reconstr Surg. 1980; 66: 54-62.
7. Fearon JA, Munro IR, Bruce DA. Observations on the use of rigid fixation for craniofacial deformities in infants and young children. Plast Reconstr Surg. 1995; 95: 634-637.
8. Yu JC, Bartlett SP, Goldberg DS, Gannon F, Hunter J, Habecker P, et al. An experimental study of the effects of craniofacial growth on the long-term positional stability of microfixation. J Craniofac Surg. 1996; 7: 64-68.
9. Bell RB, Kindsfater CS. The use of biodegradable plates and screws to stabilize facial fractures. J Oral Maxillofac Surg. 2006; 64: 31-39.

10. Sukegawa S , Kanno T, Katase N, Shibata A, Takahashi Y, Furuki Y. Clinical evaluation of an unsintered hydroxyapatite/poly-L-lactide osteoconductive composite device for the internal fixation of maxillofacial fractures. J Craniofac Surg. 2016 in press

11. Pietrzak WS, Sarver DR, Verstynen ML. Biosorbable polymer science for the practicing surgeon. J Craniofac Surg. 1997; 8: 87-91.

12. van der Elst M, Klein CP, de Blieck-Hogervorst JM, Patka P, Haarman HJ. Bone tissue response to biodegradable polymers used for intra medullary fracture fixation: a long-term *in vivo* study in sheep femora. Biomaterials. 1999; 20: 121-128.

13. Eppley B, Sadove A. A comparison of resorbable and metallic fixation in healing of calvarial bone grafts. Plast Reconstr Surg. 1995; 96: 316-322.

14. Wittwer G, Adeyemo WL, Yerit K, Voracek M, Turhani D, Watzinger F, et al. Complications after zygoma fracture fixation: is there a difference between biodegradable materials and how do they compare with titanium Osteosynthesis?. Oral Surg Oral Med Oral Pathol Oral Radiol Endod. 2006; 101: 419-425.

15. Ribeiro MC, Regalo SC, Pepato AO, Siéssere S, de Souza LG, Sverzut CE, et al. Bite force, electromyography, and mandible mobility during the 6-month period after surgical treatment for isolated fractures of the zygomatico-orbital complex. Oral Surg Oral Med Oral Pathol Oral Radiol Endod. 2011; 111: 1-7.