Clinics in Surgery

Case Report
Published: 05 May, 2016

Periorbital Emphysema due to Coughing after a Sports-related Facial Injury: A Case Report

Shigemori Y[1,2], Matsumoto J[2], Oshiro S[1,2] and Inoue T[2]*

[1]Department of Neurological Surgery, National Fukuoka-Higashi Medical Center, Japan

[2]Department of Neurological Surgery, Fukuoka University, Faculty of Medicine, Japan

Abstract

Bone fractures of the face often occur due to sports injuries. However, there is no literature describing asymptomatic facial injuries. Here we report an asymptomatic facial bone fracture following a sports-related facial injury, in which periorbital emphysema was caused by coughing. This is the case of an 18 year-old man who experienced orbital swelling of the face after coughing. He had no significant medical history, but he did have a history of a sport-related injury. He had been playing baseball when a ball had hit him in the face. Computed tomography (CT) of the head revealed a fracture of the left orbital floor. We put him on a course of prophylactic antibiotics for 5 days. On the day following the injury, the orbital emphysema decreased and the swelling disappeared. We presumed that the increased intramaxillary pressure permitted subsequent air flow under the periosteum of the left orbit. Therefore, the left orbit was inflicted with a sudden and marked appearance of emphysema after coughing. This case clearly demonstrates that patients must be carefully evaluated in asymptomatic sports-related facial injuries.

Keywords: Prophylactic antibiotics; Periorbital emphysema; Computed tomography (CT)

Introduction

Recently, guidelines on head injury prevention have been suggested for various sports [1]. The characteristics of head injuries sustained in sports are as follows: 1) repetitive concussions and 2) acute subdural hematoma caused by concussions, which can be potentially fatal [2]. In addition, fractures of the facial and maxillary bones due to head injuries that occur during sports account for nearly 7%–38% of all injuries [3-6]. However, there is little published literature regarding asymptomatic facial injuries. Here we report a case of an asymptomatic facial bone fracture after a sports-related facial injury,in which periorbital emphysema was caused by coughing.

Case Presentation

In June, 2011, an 18-year-old man presented to our hospital with facial puffiness of his left lower periorbital area. He had been playing baseball, and the ball had hit the left side of his face several hours previously. Physical examination revealed that there was neither severe pain nor any visual disturbance, and he was directly discharged. Three hours after the injury, the patient experienced a sudden bout of coughing, his left lower periorbital area became swollen but without pain (Figure 1).

Examinations of the heart, lungs, penetrating trauma, eye movements, as well as the results of laboratory tests, were normal. The patient had no medical history of acute dacryocystitis, chalazion, and tooth extraction. Computed tomography (CT) of the head was performed to exclude ontological disease diagnoses such as an inflammation of the nasal sinuses, and it showed a fracture of the left orbital floor (Figure 2). We put him on a course of prophylactic antibiotics (Cefditoren pivoxil, 200 mg) for 5 days. On the following day, the orbital emphysema was noted to be diminishing; a few days later, the swelling had disappeared, and no neurological deficits were noted.

Discussion

Facial and maxillary bone injuries due to sports have a large influence on the quality of life, which is established by disease mechanisms such as that of head injuries [3-6]. However, there is a gap in the literature with respect to problems resulting from asymptomatic injuries to the face.

Emphysema is a well-documented condition in the chest and cervical area, which may occur secondary to tonsillectomy, dental treatment, oropharyngeal barotrauma, scaling and root planning

OPEN ACCESS

Correspondence:
Yutaka Shigemori, Department of Neurological Surgery, Fukuoka-Higashi Medical Center, 1-1-1, Chidori, Koga-city, Fukuoka 811-3195, Japan, Tel: +81-92-943-12331; Fax: +81-92-943-8775;
E-mail: yutaka@lares.dti.ne.jp

Received Date: *04 Apr 2016*
Accepted Date*: 30 Apr 2016*
Published Date*: 05 May 2016*

Citation:
Shigemori Y, Matsumoto J, Oshiro S, Inoue T. Periorbital Emphysema due to Coughing after a Sports-related Facial Injury: A Case Report. Clin Surg. 2016; 1: 1013.

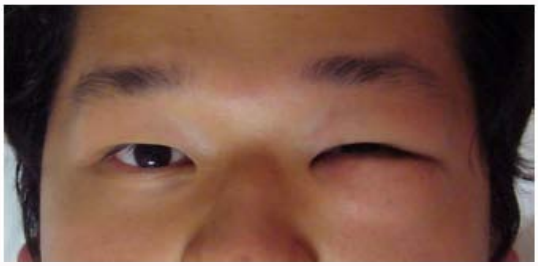

Figure 1: Photograph of the patient's face.
Photograph of the patient's face highlights the facial puffiness of the lower left periorbital area.

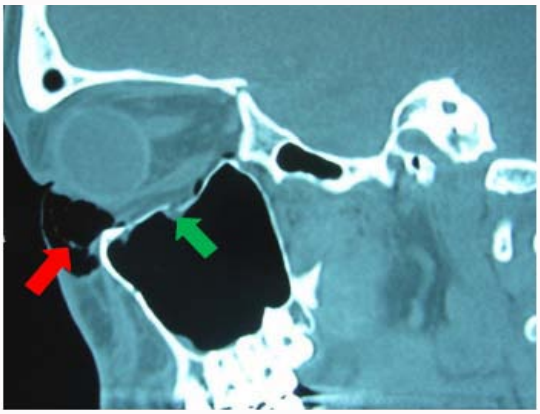

Figure 2: CT of the patient's face.
CT revealed a fracture of the left orbital floor (Green arrow) and the oribital septal wall, as well as periorbital emphysema (Red arrow).

therapy, punch biopsy, endotracheal intubation, orthognathic surgery, extraction of impacted teeth, and/or after maxillofacial injury. There are also unusual cases of focal orbital emphysema that develops when a fracture or perforation occurs in the lamina papyracea due to direct [7] or indirect trauma [8,9], resulting in elevated intraorbital pressure [10]. In general, an orbital fracture can occur in patients who have suffered blunt trauma due to traffic accidents, falls, violence, or sports. Diplopia and ocular motility restriction are the most common symptoms, with notable signs appearing at the time of the injury. These symptoms can be promptly relieved with surgery, and asymptomatic cases show good recovery with conservative medical management and antimicrobial therapy. In this case, the patient had no neurological symptoms. We presumed that the increased intramaxillary pressure was permitting the subsequent air flow under the periosteum of the left orbit, resulting in the marked appearance of emphysema after coughing. Orbital emphysema is generally a benign disease. However, emphysema should be closely monitored in case of potentially serious complications. Most reports have indicated the use of antimicrobial therapy similar to that in our case, as well as the use of nasal decongestants, air drainage, and direct decongestants, for treatment. Careful observation and a recommendation to avoid blowing the nose are the only treatments needed for orbital emphysema, and the condition typically resolves within 2 weeks. However, some reports have found that severe complications such as an intraorbital air mass may cause visual impairment due to central retinal artery occlusion [11]. Majority of outpatients are notdiagnosed with orbital fractures because of the lack of clinical signs; diplopia and ocular motility disorders are treated based on clinical follow-up, and patients are discharged. Even in patients with less severe symptoms, the doctorneeds to explain and ensure that the patient understands the potential symptoms of orbital fractures, such as facial emphysema, as described in this case. Additionally, the doctor should evaluate the patient's history of facial trauma and facial bone fractures.

Conclusion

This case demonstrates that we must carefully observe patients who present with asymptomatic orbital fractures following sports-related facial injuries. Moreover, the rapid diagnosis and management of this condition are essential to avoiding potentially serious complications.

Contributors

YS, JM, and SO treated the patient and wrote this report; TI performed the investigation.

References

1. McCrory P, Meeuwisse WH, Aubry M, Cantu B, Dvorák J, Echemendia RJ, et al. Consensus statement on concussion in sport: the 4th International Conference on Concussion in Sport held in Zurich, November 2012. Br J Sports Med. 2013; 47: 250-258.
2. The Quality Standards Subcommittee of the American Academy of Neurology. Practice parameter: the management of concussion in sports (summary statement). Report of the Quality Standards Subcommittee. Neurology. 1997; 48: 581-585.
3. Cook HE, Rowe M. A retrospective study of 356 midfacial fractures occurring in 225 patients. J Oral Maxillofac Surg. 1990; 48: 574-578.
4. Gassner R, Tuli T, Hächl O, Rudisch A, Ulmer H. Cranio-maxillofacial trauma: a 10 year review of 9,543 cases with 21,067 injuries. J Craniomaxillofac Surg. 2003; 31: 51-61.
5. Hung YC, Montazem A, Costello MA. The correlation between mandible fractures and loss of consciousness. J Oral Maxillofac Surg. 2004; 62: 938-942.
6. Mourouzis C, Koumoura F. Sports-related maxillofacial fractures: a retrospective study of 125 patients. Int J Oral Maxillofac Surg. 2005; 34: 635-638.
7. Zachariades N, Mezitis M. Emphysema and similar situations in and around the maxillo-facial region. Rev Stomatol Chir Maxillofac. 1988; 89: 375-379.
8. Mohan B, Singh KP. Bilateral subcutaneous emphysema of the orbits following nose blowing. J Laryngol Otol. 2001; 115: 319-320.
9. Brown SM, Lissner G. Orbital emphysema following remote skull trauma. Ophthal Plast Reconstr Surg. 1995; 11: 142-143.
10. Shinohara H, Shirota Y, Fujita K. Implication of differences in the incidence of orbital emphysema in ethmoidal and maxillary sinus fractures. Ann Plast Surg. 2004; 53: 565-569.
11. Dobler AA, Nathenson AL, Cameron JD, Carpel ET, Janda AM, Pederson JE. A case of orbital emphysema as an ocular emergency. Retina. 1993; 13: 166-168.