Clinics in Surgery

Research Article
Published: 12 Jul, 2021

Pedicled Nasal Flap for Naso-Oropharyngeal Reconstruction

Tae-Bin Won[1,2#], Joon Kon Kim[1,3#], Woo-Jin Jeong[1] and Sung-Woo Cho[1]*

[1]*Department of Otorhinolaryngology, Head and Neck Surgery, Seoul National University Bundang Hospital, Korea*

[2]*Department of Otorhinolaryngology, Head and Neck Surgery, Seoul National University Hospital, Korea*

[3]*Department of Otorhinolaryngology, Head and Neck Surgery, Daejeon Eulji Medical Center, Eulji University School of Medicine, Korea*

[#]*Both authors contributed equally to the contents of this article*

Abstract

Purpose: This study aimed to analyze the usefulness of employing pedicled nasal surgical flaps for the reconstructive surgical procedures of various naso-oropharyngeal lesions and investigate factors related to success.

Methods: A retrospective case review was conducted on patients with oropharyngeal lesions in which reconstruction was performed with pedicled nasal surgical flaps, with a follow-up of at least 1 year. Clinical features such as demographics, etiology, previous surgical history, underlying disease, surgical method, outcome, and complications were analyzed.

Results: A total of 12 patients were included. The mean age of the patients was 51.0 years. The reasons for reconstruction included palatal fistula (n=6), oroantral fistula (n=3), and naso-oropharyngeal stenosis (n=3). A multilayered reconstruction was used for oropharyngeal repair. The most commonly used nasal surgical flap was the nasoseptal flap (n=5, 41.6%), followed by the inferior turbinate flap (n=3, 25%), lateral nasal wall flap (n=2, 16.6%), middle turbinate flap (n=1, 8.3%), and nasal floor flap (n=1, 8.3%). Reconstruction was successful in all but one patient with oronasal fistula, and a patent airway was maintained in all cases of naso-oropharyngeal stenosis, with an overall success rate of 91.6%. There was no additional nasal morbidity.

Conclusion: Pedicled nasal surgical flaps can be used to successfully reconstruct selective naso-oropharyngeal lesions.

Keywords: Surgical flaps; Reconstructive surgical procedures; Stenosis; Oroantral fistula

OPEN ACCESS

Correspondence:
Tae-Bin Won, Department of Otorhinolaryngology-Head and Neck Surgery, Seoul National University Bundang Hospital, Seoul National University College of Medicine, 82 Gumi-ro 173 Beon-gil, Bundang-gu, Seoungnam, Kyungki-do, Korea, Tel: +82-031-781-7401; Fax: +82-031-787-4057;
E-mail: binent@hanmail.net

Received Date: *10 Jun 2021*
Accepted Date*: 08 Jul 2021*
Published Date*: 12 Jul 2021*

Citation:
Won T-B, Kim JK, Jeong W-J, Cho S-W. Pedicled Nasal Flap for Naso-Oropharyngeal Reconstruction. Clin Surg. 2021; 6: 3245.

Introduction

Reconstruction of naso-oropharyngeal lesions, such as oroantral fistula and naso-oropharyngeal stenosis, is challenging. Oronasal and oroantral fistulas are pathologic epithelialized communication between the oral and sinonasal cavities. Repair alternatives include a variety of local, regional, and free flaps. Local flaps such as buccal and palatal mucosa flaps are the mainstay. The success rate ranges from 50% to 70% [1,2] as reported in small case series. Naso-oropharyngeal stenosis is an uncommon but serious complication commonly occurring after oropharyngeal surgery. Surgical failure and restenosis are common even after multiple procedures and are therefore regarded as a surgical challenge.

Pedicled nasal surgical flaps utilizing feeders from different parts of the nasal cavity have recently been emphasized as an invaluable source of reconstruction material for the anterior skull base [3] which comprises the superior and posterior part of the nasal cavity. A few case reports have utilized nasal flaps for reconstruction of the floor and lateral part of the nose to repair oroantral fistulas [4]. We analyzed the usefulness of employing pedicled nasal surgical flaps for the reconstruction of oronasal lesions and investigated factors related to their success.

Methods

We retrospectively reviewed the records of patients who underwent reconstruction of naso-oropharyngeal lesions with pedicled nasal surgical flaps from 2008 to 2018 at two tertiary care centers. The Institutional Review Board (IRB) of our hospital approved the present study (IRB

No. L-2020-1382).The study was performed in accordance with the mandate of the WMA Helsinki declaration on ethical principles for medical research involving human subjects. The patients were followed up for at least 1 year. Clinical features such as demographics, etiology, previous surgery, underlying disease, surgical technique, and outcome were analyzed.

Results

The study included seven men and five women with ages ranging from 5 to 72 years (mean age, 51.0 years). The reasons for reconstruction included palatal fistula (n=6), oroantral fistula (n=3), and naso-oropharyngeal stenosis (n=3). A multilayered reconstruction, which included oral side repair, interposition graft, and nasal side repair, was used for oroantral and palatal fistulas (Table 1). Local rotational flap was the most commonly used oral side repair technique. The interposition graft varied from the septal bone (n=3), inferior turbinate bone (n=1), ear cartilage (n=1), temporalis muscle fascia (n=1), and fat (n=1). The most commonly used nasal flap was the nasoseptal flap (n=5, 41.6%), followed by the inferior turbinate flap (n=3, 25%), lateral nasal wall flap (n=2, 16.6%), middle turbinate flap (n=1, 8.3%), and nasal floor flap (n=1, 8.3%). Reconstruction was successful in all but one patient for the management of oronasal fistula (8/9, 88.8%), and was successful for all cases of naso-oropharyngeal stenosis, yielding an overall success rate of 91.6% (Table 1). The nasal donor site was mucosalized within several weeks without additional nasal morbidity such as septal perforation.

Case Series

Case 1: Palatal fistula

A 16-year-old male patient presented with a large palatal fistula measuring 3 cm × 2 cm in diameter. He had previously received chemoradiotherapy for the treatment of extranodal natural killer T-cell lymphoma, located in the nasal cavity. He also had a large septal perforation and consequently a saddle nose deformity (Figure 1). A multilayered reconstruction was performed. The whole palatal mucosa was raised after a circumferential incision along the inner border of the teeth and cautiously raised without injury to the greater palatine arteries. The palatal mucosa was rotated and sutured in the midline after trimming the margins of the defect (Figure 2). A piece of autologous temporalis muscle fascia was inserted as an interposition graft. Finally, an anterior pedicled left side inferior turbinate flap was used to cover the nasal side. The anterior end of the inferior turbinate was cut, and the intervening turbinate bone carefully dissected. The turbinate mucosa was unfolded and sutured to the nasal floor (Figure 3). The pedicle was divided 1 year after the surgery along with a rhinoplasty with autologous rib cartilage. The 2-yearpostoperative findings demonstrated excellent healing of the palatal fistula together with an improved nasal appearance (Figure 4, 5).

Table 1: Description of oropharyngeal reconstruction patients.

Case	Disease	Age/ Sex	Etiology	Previous surgery	Site	Defect Size (cm × cm)	Type of flap		Interposition graft	Underlying disease	RTx	Revision	Outcome
							Nasal side Repair type	Oral side Repair type					
1	Oroantral Fistula	67/F	Malignancy	Wide resection	Hard palate	1.3 × 0.8	Lateral nasal flap	Palatal Rotation flap	Septal bone	DM	Yes	No	Success
2	Oroantral Fistula	58/M	Malignancy		Buccal	0.5 × 0.7	Nasal floor flap	Buccal flap	fat		Yes	No	Failure
3	Oronasal Fistula	36/M	Trauma	Oronasal fistula reconstruction operation 2 times	Hard palate	3.0 × 4.0	Inferior turbinate flap	Palatal Rotation flap	Inferior turbinate bone		No	No	Success
4	Oronasal Fistula	16/M	Malignancy		Hard palate	3.0 × 2.0	Inferior turbinate flap	Palatal Rotation flap	Temporalis m. fascia		No	No	Success
5	Oroantral Fistula	56/M	Malignancy	Maxillectomy	Buccal	0.2 × 0.2	Middle turbinate flap	Buccal flap	Ear cartilage		Yes	No	Success
6	Oronasal Fistula	59/F	Benign tumor	Wide resection	Hard palate	1.5 ×1.0	Nasoseptal flap	Palatal Rotation flap	Septal bone		Yes	No	Success
7	Oronasal Fistula	63/M	Malignancy	Maxillectomy	Alveolus	2.0 × 2.0	Inferior turbinate flap	Palatal Rotation flap	none		Yes	No	Success
8	Oronasal Fistula	54/M	Malignancy	Wide resection	Hard palate	1.0 × 1.0	Nasoseptal flap	Palatal Rotation flap	Septal bone		Yes	No	Success
9	Oronasal Fistula	72/F	Malignancy	Partial palatectomy	Hard palate	2.0 × 4.0	Nasoseptal flap	Palatal Rotation flap	none	DM, HTN	Yes	No	Success
10	Oropharyngeal Stenosis	67/M	Congenital	Pharyngoplasty 4 times	Nasopharynx	NA	Nasoseptal flap	NA	NA		No	No	Success
11	Oropharyngeal Stenosis	5/M	Latrogenic	Tonsillectomy and adenoidectomy, Pharyngoplasty	Oropharynx	NA	Nasoseptal flap	NA	NA		No	No	Success
12	Oropharyngeal Stenosis	53/F	Iatrogenic	Pharyngoplasty 17 times	Naso-oropharynx	NA	1st op: Nasoseptal flap, 2nd op: Lateral nasal wall flap	NA	NA		No	Yes	Success

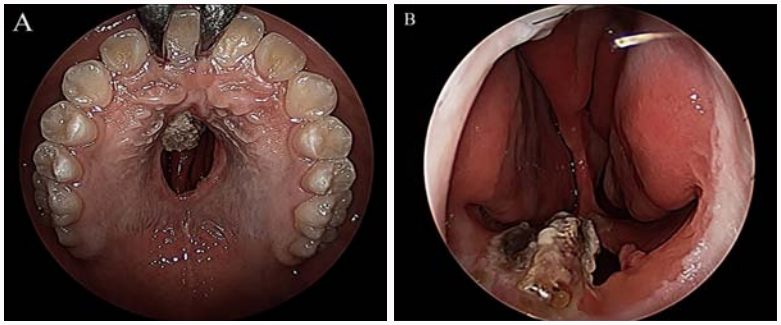

Figure 1: Physical examination reveals a large palatal fistula (A) and near total septal perforation (B).

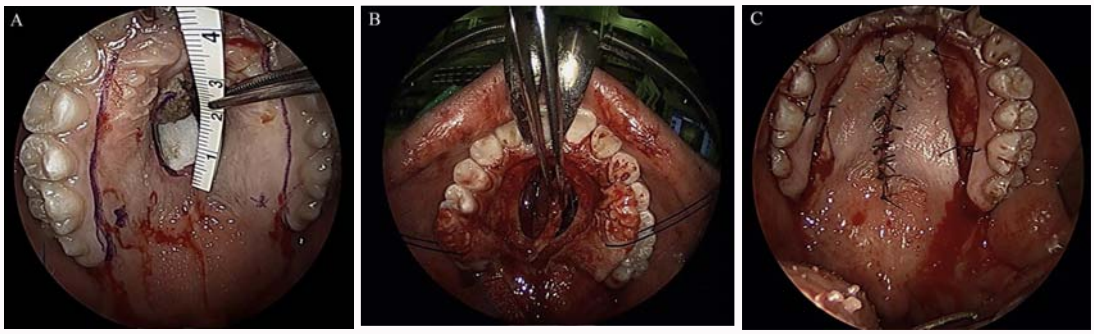

Figure 2: Intraoperative pictures of the oral side palatal fistula reconstruction. A. Incision along the inner border of the gingiva and trimming of the margins of the palatal fistula defect. B. The palatal mucosa is elevated preserving the greater palatine artery. C. Palatal flap is mobilized to the midline and the defect closed using vicryl 4-0.

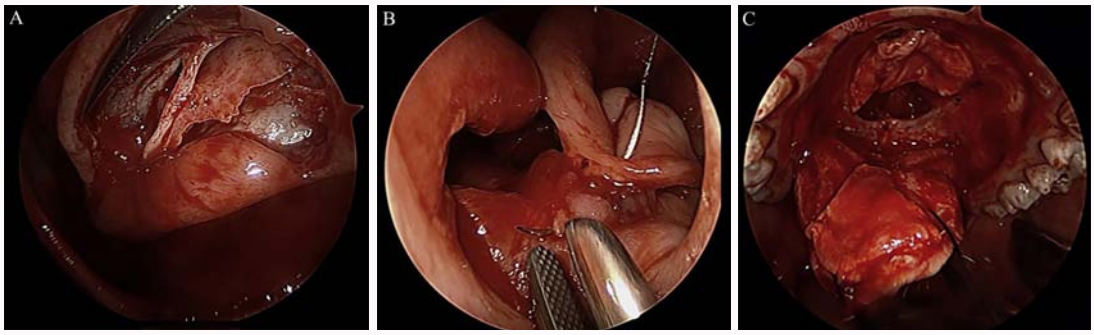

Figure 3: Intraoperative picture of the nasal side palatal fistula reconstruction with inferior turbinate flap. The posterior based inferior turbinate flap is raised (A) on the left side and sutured to the nasal floor (B) after removing the turbinate bone. C. Homologous temporalis muscle fascia was inserted as an interposition graft.

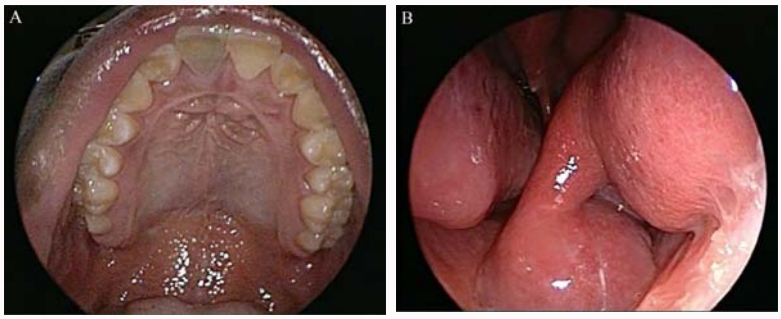

Figure 4: Postoperative photos 1year after the operation shows a well healed palate. A. Oral side; B. Nasal side.

Case 2: nasopharyngeal stenosis

A 53-year-old male patient presented with nasal stuffiness and dyspnea on exertion. On physical examination, the cause was determined to be naso-oropharyngeal stenosis (Figure 6). He had a history of oropharyngeal surgery to treat his snoring, which resulted in stenosis. Before presentation, he had undergone 17 surgeries without

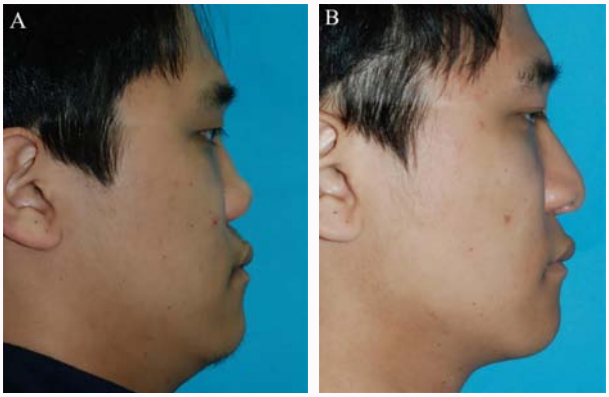

Figure 5: Pre and postoperative facial photographs of the patient after reconstructive rhinoplasty with rib cartilage graft. A. Preoperative lateral view; B. Postoperative lateral view.

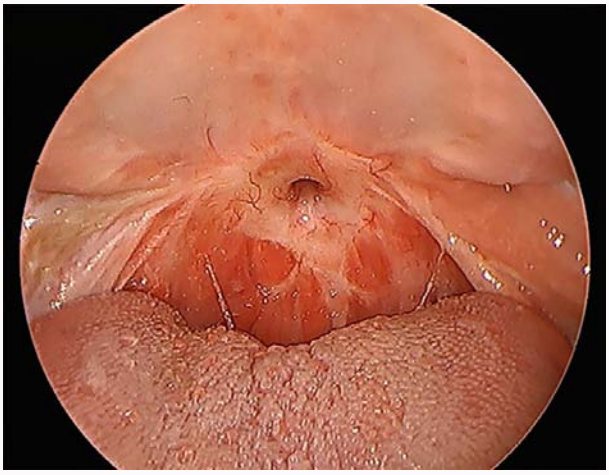

Figure 6: Preoperative endoscopic finding showing severe naso-oropharyngeal stenosis.

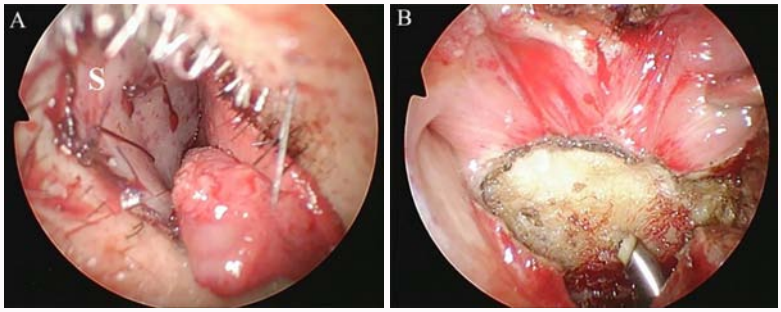

Figure 7: Intra-operative pictures of the first surgery. A: Left nasoseptal flap was elevated. B: Scar tissue in the naso-oropharynx was excised. C: Left nasoseptal flap was transposed through the nasopharynx and sutured with vicryl 4-0 to the oropharyngeal mucosa and a nasal airway (inner diameter = 6 mm) was inserted. S: nasal septum.

success. The naso-oropharyngeal tissue was replaced with hard scar tissue, which was excised to obtain a patent airway. A left side nasoseptal flap was raised and rotated into the nasopharynx to cover the excised scar and sutured to the oropharyngeal mucosa (Figure 7). However, 3 months postoperatively, the reconstruction site was re-closed (Figure 8). Another surgery was performed this time utilizing the right lateral nasal wall flap incorporating the inferior turbinate (Figure 9). The wound healed well with a patent naso-oropharyngeal airway (Figure 10) with improved nasal obstruction.

Discussion

Reconstruction of oropharyngeal lesions such as palatal and oroantral fistulas and naso-oropharyngeal stenosis is challenging. Common techniques include various local and regional flaps to repair the oral side defect, such as palatal, buccal, and temporalis fascia flaps [5,6]. Previously reported success rate varied from 60% to 70% for oroantral and palatal fistula [1,2] and 50% to 60% for naso-oropharyngeal stenosis [7]. Success usually depends on size, location, etiology, and patient factors such as smoking, diabetes mellitus, and

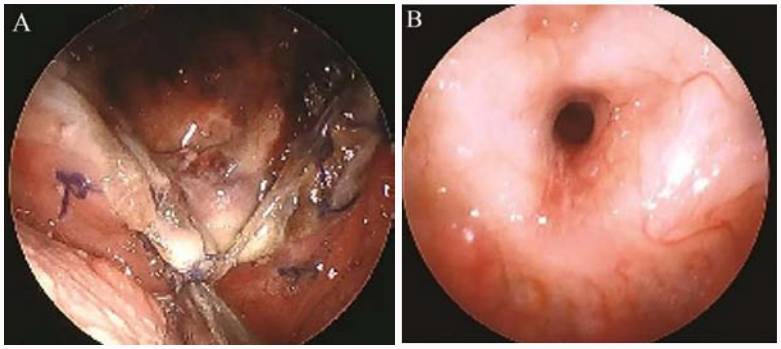

Figure 8: Postoperative endoscopic finding after 1 week showing poor circulation of in the edge of nasoseptal flap (A) which ultimately resulted in restenosis after 3 months (B).

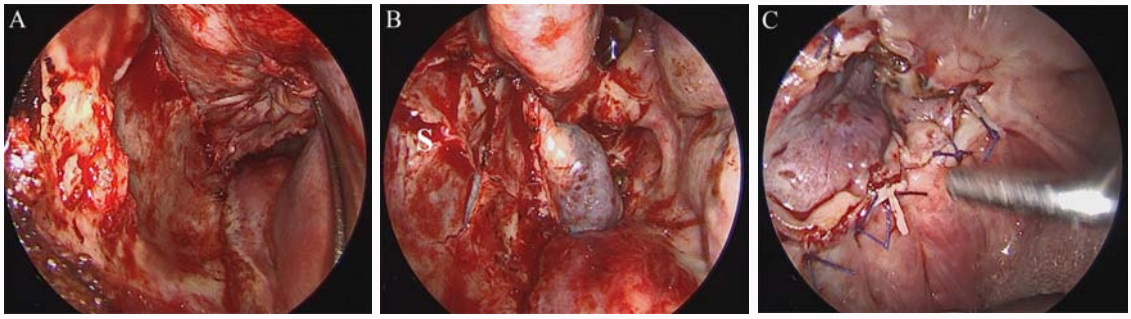

Figure 9: Revision reconstruction using the pedicled right lateral nasal wall flap. A: Right lateral wall flap is elevated. The arrow exhibits right lateral wall. B: The flap is transposed to cover the naso-oropharynx. C. The flap is sutured to the oropharyngeal mucosa.

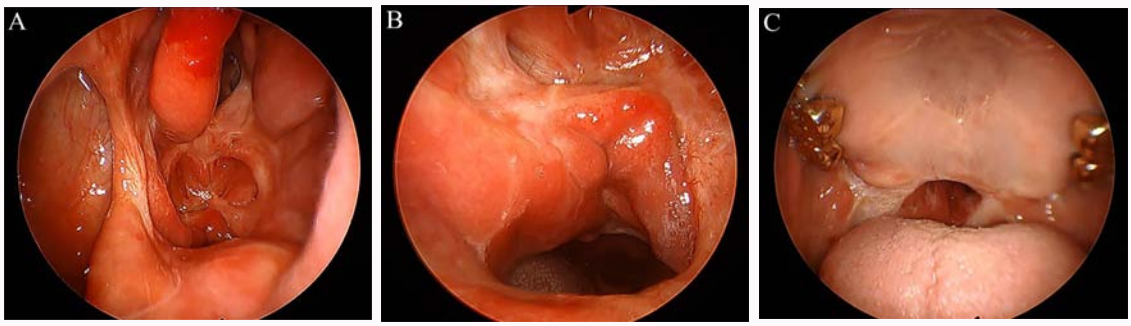

Figure 10: Endoscopic findings 6 months after volume reduction of the posterior end of the inferior turbinate show a well patent naso-oropharynx. A, B: view from the nasal side and C: view from the oral side.

previous radiotherapy [8].

After closure of the oral side defect, the nasal side is usually left to heal by secondary intention. Secondary healing of the nasal side defect follows a protracted course that usually requires 6 to 12 weeks for complete remucosalization [9]. This may cause prolonged crusting increasing the chance of secondary infection and ultimately failure. Simultaneous reconstruction of the nasal side, as part of a multilayered strategy, has been recently reported with faster recovery and good outcomes [10]. However, these were usually case reports or case series that included only a small number of patients [11]. To the best of our knowledge, our study provides the largest patient series in this regard. An array of nasal tissue can be used for this purpose from free grafts to pedicled nasal flaps. Numerous studies have shown the superiority of vascularized nasal flaps compared to free grafts for various reconstructive purposes [12-14]. Our study used vascularized pedicled mucosal flaps from various parts of the nasal cavity including the nasal septum, inferior turbinate, and lateral nasal wall which offered rapid re-mucosalization of the nasal side defect in 1 to 2 postoperative weeks.

The nasoseptal flap, with its pedicle based on the posterior nasal artery, a terminal branch of the sphenopalatine artery, is readily accessible, easy to harvest, and pliable and has minimal donor site morbidity [15,16]. In addition, it has a large surface area and good length and reach. This flap can reach from the nasopharynx to the anterior skull base and cover a ≥ 6 cm defect. Owing to these advantages, the nasoseptal flap is currently being used as a workhorse to repair various skull base defects and cerebrospinal fluid leaks. In cases where the septal flap is not available, there are alternative nasal flaps, such as the inferior and middle turbinate flaps and the lateral nasal wall flap. The inferior turbinate flap has a dual blood supply [17] and therefore can be pedicled anteriorly or posteriorly depending on the location of the defect. The main supply enters the

turbinate from above, 1 cm to 1.5 cm from its posterior border, and is the descending branch of the sphenopalatine artery. The artery then passes forward, providing a rich anastomotic network of vessels; as the vessel courses anteriorly, it increases in diameter, which suggests a significant anterior-based component to its blood supply. The anterior blood supply originates from the angular artery and allows for the anteriorly pedicled inferior turbinate flap which can be used when the sphenopalatine artery is sacrificed [18]. It is simple and quick to harvest and is readily available during endonasal surgery in the absence of a nasoseptal flap. Lateral nasal wall flaps have a rich vascular supply based on the branch of the posterolateral nasal artery that, in turn, is a branch of the sphenopalatine artery. Branches of the facial and ethmoidal arteries supply the anterior lateral nasal wall [19]. A lateral nasal wall flap can be used for large oropharyngeal defects because the flap has a wide acquisition range.

The nasoseptal flap was usually the flap of choice followed by other nasal flaps when the septum was not available or for salvage. Therefore, the nasoseptal flap was used most commonly in our series (n=5), followed by the inferior turbinate flap (n=3), lateral nasal wall flap (n=2) and middle turbinate flap (n=1).

Our case series demonstrated excellent results for the reconstruction of various oropharyngeal lesions. The overall success rate of 91.6% (for 89% fistulas and 100% for stenosis) was noticeably better than that previously reported. The oral side repair was not different from the others, which used local rotational flaps such as palatal and buccal flaps. Therefore, we believe that the high success rate is in part related to the additional nasal side repair with pedicled nasal surgical flaps. One oroantral fistula repair failed. This patient had undergone maxillectomy and postoperative radiotherapy for the treatment of maxillary cancer. He also had poorly controlled diabetes mellitus and was further diagnosed with ongoing osteoradionecrosis of the remaining maxilla. In the patient with naso-oropharyngeal stenosis who underwent revision surgery, initial reconstruction with the nasoseptal flap failed. We believe that the decreased circulation and eventual necrosis of the flap was related to the previous septoplasty. Although the main pedicle which is the posterior septal artery was preserved, the septal mucosa was very thin, with frequent areas of void septal bone. Therefore, in the final revision surgery, the lateral nasal wall flap was chosen instead of the contralateral nasoseptal flap [20].

Although we have confirmed its usefulness, the use of nasal pedicled surgical flaps has limitations related to the size and location of the oropharyngeal defect. Nasoseptal flaps incorporating the membranous septum anteriorly and the nasal floor inferiorly can provide maximal reach and size [21]. The inferior turbinate, middle turbinate and whole lateral nasal wall flap can be used when the septum is not available. The choice will depend on the size and location of the defect. Therefore, a discreet preoperative evaluation should be performed before surgery. In addition, there were no additional nasal morbidities such as septal perforation. However, the limited number of cases precluded further elucidation of factors related to success, such as size, location, and superiority according to the choice of nasal flap and interposition graft. Further studies with larger sample sizes are warranted.

Conclusion

Pedicled nasal surgical flaps can be used to increase to successfully reconstruct selective naso-oropharyngeal lesions.

Author Contributions

Conceptualization: TBW, JKK; Data curation: TBW, JKK; Formal analysis: JKK; Methodology: TBW, JKK, WJJ and SWC; Writing-original draft: JKK; Writing-review & editing: TBW, JKK.

References

1. Yalçın S, Öncü B, Emes Y, Atalay B, Aktaş İ. Surgical treatment of oroantral fistulas: A clinical study of 23 cases. J Oral Maxillofac Surg. 2011;69:333-9.
2. Giannoni C, Sulek M, Friedman EM, Duncan NO. Acquired nasopharyngeal stenosis: A warning and review. Arch Otolaryngol Head Neck Surg. 1998;124:163-7.
3. Shah RN, Surowitz JB, Patel MR, Huang BY, Snyderman CH, Carrau RL, et al. Endoscopic pedicled nasoseptal flap reconstruction for pediatric skull base defects. Laryngoscope. 2009;119(6):1067-75.
4. Spielman DB, Kim M, Overdevest J, Gudis DA. The Nasoseptal chondromucosal flap: A rigid reconstructive technique for skull base and orbital defects. ORL J Otorhinolaryngol Relat Spec. 2020;82(5):268-73.
5. Candamourty R, Jain MK, Sankar K, Babu MR. Double-layered closure of oroantral fistula using buccal fat pad and buccal advancement flap. J Nat Sci Biol Med. 2012;3(2):203-5.
6. Kraut RA, Smith RV. Team approach for closure of oroantral and oronasal fistulae. Atlas Oral Maxillofac Surg Clin North Am. 2000;8(1):55-75.
7. Black RJ, Pracy R, Evans JN. Congenital posterior choanal atresia. Clin Otolaryngol Allied Sci. 1983;8:251-5.
8. Teissier N, Kaguelidou F, Couloigner V, François M, Van Den Abbeele T. Predictive factors for success after transnasal endoscopic treatment of choanal atresia. Arch Otolaryngol Head Neck Surg. 2008;134(1):57-61.
9. Kasemsiri P, Carrau RL, Otto BA, Tang IP, Prevedello DM, Muto J, et al. Reconstruction of the pedicled nasoseptal flap donor site with a contralateral reverse rotation flap: Technical modifications and outcomes. Laryngoscope. 2013;123(11):2601-4.
10. George E. Triple-layered closure of an oroantral fistula: A case report. Int J Oral Maxillofac Implants. 2018;33(2):e33-6.
11. Nishimori M, Matsumoto M, Nakagawa H, Ichiishi N. Unanticipated difficult airway due to undiagnosed oropharyngeal stenosis: A case report. JA Clin Rep. 2016;2(1):10.
12. Rahpeyma A, Khajehahmadi S. Inferior turbinate flap for nasal-side closure of palatal fistula in cleft patients: Technical Note. Plast Reconstr Surg Glob Open. 2015;2(12):e265.
13. Noel JE, Teo NW, Divi V, Nayak JV. Use of pedicled nasoseptal flap for pathologic oroantral fistula closure. J Oral Maxillofac Surg. 2016;74(4):704.e1-6.
14. Tochigi K, Omura K, Miyashita K, Aoki S, Otori N, Tanaka Y. Pathological features of free graft and pedicled flap in the nasal cavity: An animal study. Laryngoscope. 2021;131(2):E428-33.
15. Hadad G, Bassagasteguy L, Carrau RL, Mataza JC, Kassam A, Snyderman CH, et al. A novel reconstructive technique after endoscopic expanded endonasal approaches: Vascular pedicle nasoseptal flap. Laryngoscope. 2006;116(10):1882-6.
16. Fujii M, Goto N, Shimada K, Moriyama H, Kikuchi K, Kida A. Demonstration of the nasal septal branches of the sphenopalatine artery by use of a new intravascular injection method. Ann Otol Rhinol Laryngol.1996;105(4):309-11.
17. Padgham N, Vaughan-Jones R. Cadaver studies of the anatomy of arterial supply to the inferior turbinates. J R Soc Med. 1991;84(12):728-30.
18. Murakami CS, Kriet JD, Ierokomos AP. Nasal reconstruction using the inferior turbinate mucosal flap. Arch Facial Plast Surg.1999;1(2):97-100.

19. Alobid I, Mason E, Solares CA, Prevedello D, Enseñat J, De MN, et al. Pedicled lateral nasal wall flap for the reconstruction of the nasal septum perforation. A radio-anatomical study. Rhinology. 2015;53(3):235-41.

20. Shin JM, Lee CH, Kim YH, Paek SH, Won TB. Feasibility of the nasoseptal flap for reconstruction of large anterior skull base defects in Asians. Acta Otolaryngol. 2012;132(Suppl 1):S69-76.

21. Park SJ, Kim HJ, Kim DY, Rhee CS, Lee CH, Paek SH, et al. Radioanatomic study of the skull base and septum in Asians: Implications for using the nasoseptal flap for anterior skull-base reconstruction. Int Forum Allergy Rhinol. 2017;7(10):999-1005.