Clinics in Surgery

Research Article
Published: 21 Sep, 2016

Paravertebral Continuous Infusion Analgesia in Vats Patients. Single Center Prospective Randomized Study

Federico Raveglia[1], Matilde De Simone[3], Alessandro Rizzi[1], Piero Di Mauro[2], Alessandro Baisi[1] and Ugo Cioffi[3]*

[1]Department of Thoracic Surgery, University of Milan, Italy

[2]Department of Anesthesiology, University of Milan, Italy

[3]Department of Surgery, University of Milan, Italy

Abstract

Objective: We have previously presented the successful results of paravertebral local analgesia in thoracotomy patients. Therefore, we have developed and described an intraoperative technique for paravertebral catheter (PC) placement and continuous local analgesic infusion in video assisted thoracic surgery (VATS). This innovative technique is different from the "lots of resistance"/blind or the ultrasound-guided placement procedures, besides continuous infusion work differently from paravertebral blocks. We present a randomized study comparing this procedure with opioid intravenous patient controlled analgesia (OIVPCA).

Methods: From October to December 2015, 40 patients submitted to VATS lung resection have been randomized into two homogenous groups for the administration of analgesic drugs, through PC + OIVPCA (morphine 1 mg/1ml bolus, lock out 10 minutes) in "group A" or OIVPCA alone in "group B". In "group A", Tuhoy needle was percutaneously introduced below parietal pleura in the same intercostal space as the camera port. Insertion point was detected on the skin, 3 cm by the vertebral column. PC was pushed through the needle until paravertebral space was reached. Postoperative analgesia was performed by continuous infusion of local analgesic (naropine 3,75%, 7 ml/h). The following parameters have been recorded on scheduled postoperative days: a) pain control using visual analogue scale b) respiratory function using FEV1 and ambient air saturation c) morphine-equivalent demanded/administered. Records have been analyzed with Mann-Withney or Student's tests for independent variables.

Results: No complications in PC placement were recorded. Moreover, due to thoracoscopic approach posterior parietal pleura remained intact, unlike thoracotomy, avoiding any drug runoff in the pleural cavity. Significant differences have been found in favor of group A concerning both rest and cough pain control ($p< 0.01$ and 0.035) and respiratory function in terms of FEV1 ($p=0.017$). No difference was recorded concerning ambient air saturation ($p >0.05$). Group A had significant lower mean morphine-equivalent demanded (5.47 mg vs. 9 mg) and consumption (4.76 mg vs. 8.38 mg).

Conclusion: Intra-operative PC placement was safe and easy to perform. Local analgesic paravertebral continuous infusion was effective and allowed lower morphine consumption. We strongly recommend this procedure in VATS to further improve thoracoscopy advantages in pain management.

Introduction

Postoperative pain in thoracic surgery is often present and associated with severe complications, such as atelectasis which can develop into pneumonia because of secretions retention. Moreover, pain prevents effective coughing, deep breathing and patient's mobility. At present, various techniques have been proposed and adopted to prevent postoperative pain and epidural anesthesia (EA) has been considered the gold standard. In a recent study [1] we have compared the efficacy of EA with continues paravertebral block analgesia in thoracotomy patients.

The aim of the study was to find if paravertebral analgesia could avoid some typical EA difficulties. Among these, EA catheter is usually placed by an anesthesiologist immediately before surgery when the patient is awake and is contraindicated for patients taking anticoagulant or anti-platelet drugs that cannot be suspended for the preoperative period or for those who have coagulopathies.

OPEN ACCESS

Correspondence:
Federico Raveglia, Department of Thoracic Surgery, University of Milan, A.O. St. Paul Via di Rudini '8, 20142, Milan, Italy, Tel: +393381336071; Fax: 0250323075;
E-mail: federico.raveglia@asst-santipaolocarlo.it

Received Date: *07 Jul 2016*
Accepted Date*: 07 Sep 2016*
Published Date*: 21 Sep 2016*

Citation:
Raveglia F, De Simone M, Rizzi A, Di Mauro P, Baisi A, Cioffi U. Paravertebral Continuous Infusion Analgesia in Vats Patients. Single Center Prospective Randomized Study. Clin Surg. 2016; 1: 1135.

Table 1: Inclusion and exclusion criteria.

Inclusion criteria	Exclusion criteria
Age>18 or <80 y	Age<18 or >80 y
Karnofsky performance scale 70%	Coagulopathies
American Society of Anesthesiology Classification <IV	Analgesic therapies
Forced expiratory volume in 1 second 50% predicted	Allergies
Wegener's granulomatosis (white blood cell count >4000/mm3)	Neurologic diseases
Primary systemic chemotherapy (platelet count >100,000/mm3)	Psychiatric diseases
Hemoglobin >8.5 g/dL Psychiatric diseases	Past thoracic surgery
Bilirubin <3.0 mg/dL	Pre-op thoracic drainage
Aspartate transaminase <2 times limits	Past acute myocardial infarction
Creatinine <3.0 mg/dL	Abuse of alcohol or drugs
Carbon dioxide tensión <50 mm Hg	Body mass index >30
	Pregnancy

Moreover, this technique may result in dangerous risks during placement, including dural perforation, spinal cord hematoma, spinal infection or abscess. During treatment some adverse events may occur, including hypotension, urinary retention, nausea, vomiting or itching. Our data showed that paravertebral block analgesia, administered by a paravertebral catheter (PC) placed thorough thoracotomy at the end of surgery, was more effective than EA in terms of pain management and was not affected by any side effects.

Since results were significantly in favor of PC, we decided to adopt this technique also in VATS, since thoracoscopy covers more than 50% of thoracic surgery procedures but gold standard analgesia has not been determined.

Some Authors have already described the effects of paravertebral [2] or intercostals blocks [3] in thoracoscopy patients. Different techniques (eg., the loss of resistance technique also known as the anesthetic/blind approach, the ultrasound-guided or the neuronal stimulator-guided technique) to pre-operatively place the PC and administer postoperative single or multiple injections of drugs in the paravertebral space, have been described. However, these procedures have been commonly considered demanding, time-consuming and especially unsafe, because of many difficulties to correctly identify and reach the paravertebral space.

Based on this evidences, we decided to develop a new technique for intraoperative PC placement that should have been simple and moreover feasible in VATS [4].

It's our belief that this new placement technique combined with the continuous infusion model could be successful. Moreover, unlike thoracotomy, the posterior parietal pleura is always kept intact avoiding any drug runoff in the pleural cavity. This could make paravertebral analgesia in VATS even more effective than in thoracotomy patients.

Therefore, we have proposed a prospective randomized study to compare paravertebral analgesia with opioid intravenous patient controlled analgesia (OIVPCA), in thoracoscopic patients. OIVPCA is widely considered the gold standard in the management of postoperative pain.

The first end point of our study was to show if paravertebral analgesia is effective. The secondary endpoint was to find out if this technique guarantees a smaller use of morphine.

Materials and Methods

The study was approved by local ethic committee at San Paolo Hospital, University of Milan (n° 16490). All recruited patients provided informed and written consent to the study. We considered patients who underwent VATS (2 ports and a 4 centimeters mini-thoracotomy) for pulmonary anatomic or sub-anatomic resections. The inclusion and exclusion criteria are reported in Table 1. SAS® software was used to perform power analysis in order to estimate the sample size needed (for a power of 80%). The study was prospective, randomized and double-blind.

Patients enrolled have been randomized into two homogenous groups (by SAS® software) for the administration of analgesic drugs, through PC (continuous infusion of naropine 3,75%, 7 ml/h) + OIVPCA (morphine 1 mg/1ml bolus, lock out 10 minutes) in "group A" or OIVPCA alone in "group B".

Each patient in the two groups had simultaneous infusion of paracetamol 4 times a day. Any other request by patients to be administered more pain medication were recorded and satisfied.

Our model is based on a new technique of catheter placement and on the continuous local anesthetic infusion. Catheter (Contiplex® Tuhoy Set, B-Braun) is placed in the same intercostal space as the camera port, since some reports [5] and our experience showed that post-operative pain after VATS, without rib spreading, primarily originates from the area used for the camera and chest tube. Contrary to paravertebral block or intercostal nerve block [3,4], continuous infusion allows to obtain a high and steady concentration of analgesic at the spinal branches corresponding to the camera intercostal space. Moreover, drug diffusion through paravertebral space guarantees also a good anesthetization of the surrounding chest wall.

Catheter is placed 3 cm by the vertebral column. Insertion point is detected on the skin thanks to the camera light positioned by the assistant in contact with the parietal pleura of the selected paravertebral space. A Tuhoy needle is percutaneously introduced by the surgeon below the parietal pleura, carefully avoiding its damage. We underline that these maneuvers can be easily performed just because of the thoracoscope guide. Then a 7 cc bolus of analgesic is injected through the needle in order to tunnelize the parietal pleural. The catheter is insert thorough the needle and pushed until the paravertebral space is reached. If pleural hydro-dissection has been correctly performed, the catheter easily runs below the parietal pleura

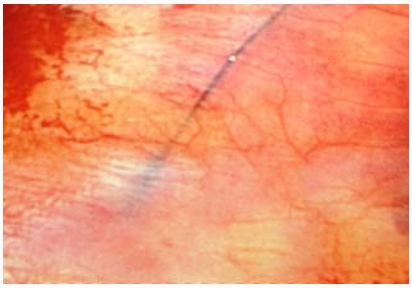

Figure 1: The catheter easily runs below the parietal pleura and its blue marked tip allows to immediately verify the correct placement.

due to its closed tip. A blue marking of the catheter tip, allows to immediately verifying its correct placement (Figure 1). This method is quicker and safer than the blind or ultrasound-guided approach.

We named the technique "hybrid" since comprises a percutaneous time coming from the anesthetic approach but at the same time it is surgically performed by VATS. Local analgesic administration through the catheter was continues, contrary to standard paravertebral blocks.

We always placed 1 chest tube at the end of any VATS procedure. All surgeries were performed by the same equip. In each group the catheter was removed on the same day that the chest tube was removed, between the third and fifth day after surgery.

Pain level was measured using a VAS both at rest and while coughing (where 0 indicates no pain and 10 indicates severe pain) at 6, 12, 24, 48 and 72 hours after surgery. Moreover, in each group morphine-equivalent demanded and administered were daily recorded.

To evaluate pulmonary function at 6, 12, 24, 48 and 72 hours forced expiratory volume in 1 second (FEV1) and ambient air saturation were recorded. All data was recorded by the research fellow (i.e., A.R.). Normally distributed results were compared by Student *t* test analysis and non-normally distributed results were compared by Mann-Whitney analysis.

Results

From October to December 2015, 40 patients were enrolled and randomized. The two groups were composed of 20 patients each, 50% and 54% man in the A and B group respectively. The mean patient age was 79 in both groups. No statistical significance was found in the demographic traits (i.e., weight, height and body mass index) of the 2 groups ($p > 0.47$). No patients in either group had a previous history of thoracic surgery or had known allergies. All patients had surgery for lung cancer, except for 2 who underwent lung resection for benign tumor. No complications in PC placement were recorded. No mortality was reported. FEV1 measurements were taken preoperatively and at 6, 12, 24, 48 and 72 hours after surgery with statistical significance ($p=0.017$) in favor of group A. VAS was recorded at 6, 12, 24, 48 and 72 hours after operation both at rest and while coughing with statistical significance in favor of group A ($p< 0.01$ and 0.035). Ambient air saturation was taken at 6, 12, 24, 48 and 72 hours after the operation with no statistical significance between two groups ($p > 0.05$). Group A had lower daily mean morphine-equivalent demanded (5.47 mg vs. 9 mg) and consumption (4.76 mg vs. 8.38 mg). None of the patients in either groups required additional pain medication.

Discussion

Pain is the most important factor responsible for disorders in patient's respiratory mechanism and pulmonary function in the postoperative period after thoracic surgery [6-11]. It has different origins, making its etiology very complex. Surgical techniques influence the nature and intensity of postoperative pain. Standard thoracotomy is more painful than VATS. In particular, during thoracotomy, ribs spreading and retraction of the posterior spinal muscles determine stimuli transmitted by the posterior primary branches of the spine. The incision pain is mediated by the anterior branches. On the contrary, during VATS, any ribs spreading is avoided but the trocar cannulas, when inserted in the intercostal space (port), make a pressure on surrounding tissue resulting in an injury of the intercostal nerve. This may determine postoperative neuritis and increase acute and chronic pain incidence. In particular, camera port has been described as the port more associated with postoperative neuritis because of continues camera movements during surgery and because it is usually used also for chest tube placement.

All these pathways establish stimuli for the origin of pain and must be blocked.

Following thoracic surgery, a restrictive pathway develops, which decreases to approximately 40% the baseline values of FEV1 and functional residual capacity. The relationship between functional residual lung capacity and closing capacity predicts if atelectasis will develop; a decreasing functional residual lung capacity to a value less than closing capacity leads to airway narrowing or closure, which produces an area with a low ventilation perfusion relationship. Simultaneously, postoperative pain highly limits voluntary deep breathing, coughing and patient mobility, and all necessary to break down atelectasis. All these conditions can be associated with respiratory infections [12]. Many modalities for the management of postoperative pain are known. Intravenous opioids may work adequately but are related to cough suppression, as well as central nervous system and respiratory depression, leading once again to retention of secretion and atelectasis. However, intravenous narcotic analgesia is still considered the most effective treatment in pain management after surgery and in VATS also.

Our results show that there was always a significant difference in favor of group A (paravertebral block analgesia) as far as pain management is concerned, both at rest and while coughing, in the 72 hours after surgery. Data also proves that paravertebral analgesia group was more successful concerning respiratory outcomes for pulmonary function in terms of FEV1. However, the most relevant result is that morphine consumption was lower in group A, avoiding all the fearsome opioids collateral effects. This allows us to conclude that the use of paravertebral block analgesia in VATS is effective in reducing morphine consumption and guaranteeing even more success in pain management. Concerning PC placement during thoracoscopy, it is an intraoperative maneuver performed by surgeons in about 5 minutes, safe and without contraindications.

The strength of our study lies in the prospective randomization nature and the collection of objective data, such as FEV1, saturation and morphine consumption. The most important limitations are represented by the small number of patient's enrolled, even though sufficient to reach statistical significance, and the influence of patient's personal evaluation of pain. Moreover, the paper shows that paravertebral analgesia could reduce consumption of opioid, but

does not consider other similar techniques, for example intercostals continuous analgesia.

References

1. Raveglia F, Rizzi A, Leporati A, Di Mauro P, Cioffi U, Baisi A. Analgesia in patients undergoing thoracotomy: epidural versus paravertebral technique. A randomized, double-blind, prospective study. J Thorac Cardiovasc Surg. 2014; 147: 469-473.
2. Fibla JJ, Molins L, Mier JM, Sierra A, Carranza D, Vidal G. The efficacy of paravertebral block using a catheter technique for postoperative analgesia in thoracoscopic surgery: a randomized trial. Eur J Cardio-thoracic Surg. 2011; 40: 907-911.
3. Forcella D, Pompeo M, Coniglione F, Gatti A, Mineo TC. A new technique for continuous intercostal-intrapleural analgesia in video thoracoscopic surgery. J Thorac Cardiovasc Surg. 2009; 137: e48-e49.
4. Cioffi U, Raveglia F, Rizzi A, Di Mauro P, De Simone M, Baisi A. Paravertebral Analgesia in Video-Assisted Thoracic Surgery: A New Hybrid Technique of Catheter Placement for Continuous Anesthetic Infusion. Thorac Cardiovasc Surg. 2015; 63: 533-534.
5. Wildgaarda K, Petersenb RH, Hansenb HJ, Møller-Sørensenc H, Ringsteda K, Kehleta H. Multimodal analgesic treatment in video-assisted thoracic surgery lobectomy using an intraoperative intercostal catheter. Eur J Cardio-Thoracic Surg. 2012; 41: 1072–1077.
6. Ochroch EA, Gottschalk A, Augostides J, Carson KA, Kent L, Malayaman N, et al. Long-term pain and activity during recovery from major thoracotomy using thoracic epidural analgesia. Anesthesiology. 2002; 97: 1234-1244.
7. Senturk M, Ozcan PE, Talu GK, Klyan E, Camci E, Ozyalcin S, et al. The effects of three different analgesia techniques on long-term post thoracotomy pain. Anesth Analg. 2002; 94: 11-15.
8. Muehling BM, Halter GL, Schelzig H, Meierhenrich R, Steffen P, Sunder-Plassmann L, et al. Reduction of post-operative pulmonary complications after lung surgery using a fast track clinical pathway. Eur J Cardiothoracic Surg. 2008; 34: 174-180.
9. Dowling R, Thielmeier K, Ghaly A, Barber D, Boice T, Dine A. Improved pain control after cardiac surgery: results of a randomized, double-blind, clinical trial. J Thorac Cardiovasc Surg. 2003; 126: 1271-1278.
10. Wildgaard K, Ravn J, Kehlet H. Chronic post-thoracotomy pain: a critical review of pathogenic mechanism and strategies for prevention. Eur J Cardiothorac Surg. 2009; 36: 170-180.
11. Kehlet H, Dahl JB. Anesthesia, surgery, and challenges in postoperative recovery. Lancet. 2003; 362: 1921-1928.
12. Nosotti M, Baisi A, Mendogni P, Palleschi A, Tosi D, Rosso L. Muscle sparing versus posterolateral thoracotomy for pulmonary lobectomy: randomized controlled trial. Interact Cardiovasc Thorac Surg. 2010; 11: 415-419.