Clinics in Surgery

Case Report
Published: 22 Jun, 2021

Open, Vacuum Assisted Closure (VAC) Therapy of Empyema Thoracis with Bronchial Fistula after Thoraco-Myoplasty, Following Irradiation and Pneumonectomy

Gábor Balogh Sen[1], Gábor Balogh JN[1], István Garbera[2] and Zsolt Székely Pápai[3]*

[1]Surgical Department, Kaposi Mór Teaching Hospital, Hungary

[2]Department of Radiology, Kaposi Mór Teaching Hospital, Hungary

[3]Department of Pulmonology, Szent György Hospital, Hungary

Abstract

Pulmonary fibrosis with threatening pulmonary gangrene occurred as a complication of chemoradiation treatment of a patient undergoing right upper lung lobe resection for lung cancer. We were forced to perform right side pneumonectomy, after which late bronchial stump opening and empyema developed.

With a demonstration of our case, we intend to show how oncological treatment with severe iatrogenic damage caused a chain of complications and what were the therapeutic tools that led to the recovery of the patient after 3 years.

Keywords: Postpneumonectomic bronchial fistula; Thoracomyoplasty; Vacuum assisted closure (VAC)

Thoracic myoplasty is perhaps the most important and successful solution to advanced, severe surgical purulence in severe cases of chronic thoracic purulence. Surgery involves significant tissue sacrifice, functional damage, and permanent deformity, including soft tissue and bone structure.

The surgical management of bronchial empyema as a complication of pneumonectomy after irradiation is particularly challenging. With final closure rates as low as 60% to 70% [9-11] and a high risk of permanent thoracostomy and mortality, all options must be considered. These include the use of vacuum-assisted wound closure treatment, which has become a common practice in abdominal and cardiac surgery (post-operative sternal osteomyelitis)

Case Presentation

In May 2006, T. T., a 66-year-old male patient underwent resection of the right upper lung lobe for adenocarcinoma papillare pulmonis (Figure 1/a-b), followed by chemoirradiation. After complex oncoradiological treatment, progressive pulmonary fibrosis, pneumonia, and finally threatening pulmonary gangrene occurred (Figure 2), which forced us to perform a right-sided pneumonectomy in May 2007.

During the operation, anatomical preparation was not possible due to the scarring caused by irradiation, therefore the lung-hylus was treated "en masse" with a lung suturing machine.

In December 2007, 7 months after the pneumonectomy, bronchial empyema developed in the right thoracic cavity, which was diagnosed by bronchoscopic examination as a 22 mm diameter fistula opening localized to the right main bronchus (Figure 3).

On January 10th 2008, a right fenestration was performed (Figure 4) in the axillary midline. We removed 5 cm of rib III, 7 cm of rib IV and 8 cm of rib VI. Subsequently, regular swab changes were performed partly in outpatient care and partly in hospital care. The open treatment of bronchiectatic post-pneumonectomy empyema was extremely stressful for the patient and the tight tampon could cover the actively permeable bronchial fistula only for some time.

During the tampon changes, the patient had a coughing fit that was barely suppressible and very difficult to prevent. In the past, good results were obtained with Epigard 12[1], but this time, despite repeated attempts, it was unsuccessful. We considered the implantation of a covered

OPEN ACCESS

Correspondence:
Gábor Balogh Sen, Surgical Department, Kaposi Mór Teaching Hospital, Hungary,
E-mail: gabbal@freemail.hu

Received Date: *25 May 2021*
Accepted Date*: 15 Jun 2021*
Published Date*: 22 Jun 2021*

Citation:
Sen GB, Gábor Balogh JN, Garbera I, Pápai ZS. Open, Vacuum Assisted Closure (VAC) Therapy of Empyema Thoracis with Bronchial Fistula after Thoraco-Myoplasty, Following Irradiation and Pneumonectomy. Clin Surg. 2021; 6: 3223.

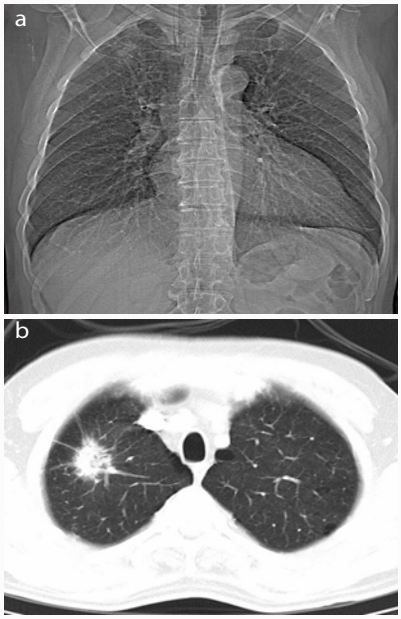

Figure 1/a-b:

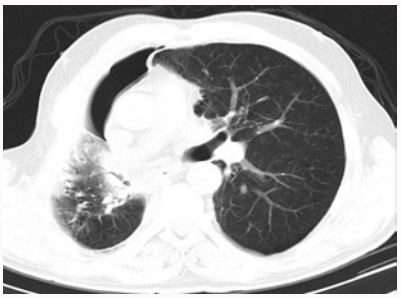

Figure 2:

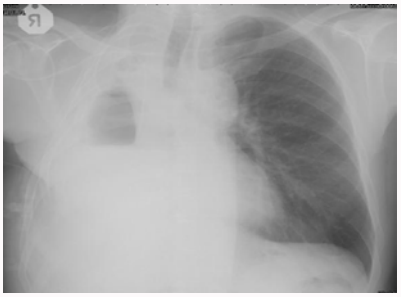

Figure 3:

tracheobronchial stent to close the fistula, which ensures unobstructed breathing of the intact lung and prevents the leakage of purulent secretions to the intact side (Figure 4).

A few weeks after implantation, the stent loosened, the purulent bronchial secretions started to leak outside the stent, and acted as another focal area because clearance between the stent, and the tracheal wall could not be resolved. It caused a continuous cough stimulus in the patient, maintained persistent subacute inflammation in the bronchial system on the left side, confirmed by bronchoscopy performed several times, which forced us to remove the stent.

Thereafter, the patient's condition improved, and the coughing

Figure 4:

attacks subsided but did not completely disappear. In the right thoracic cavity, multidrug-resistant Ps. *Aeruginosa* and *Acinetobacter* infection persisted despite continuous swab changes and antibiogram-based local, sometimes systemic, antibiotic treatment. Despite nearly 10 months of open treatment, these two pathogens were not successfully eliminated from the purulent right thoracic cavity. We opted for a combined treatment strategy.

In our patient's case, the treatment methods that have been successful on several occasions (bronchial stump covering with Epigard, open treatment, tracheobronchial stent) did not produce the necessary results to perform a thoraco-myoplasty. Therefore, the possibility arose to try to adapt the VAC (Vacuum Assisted Closure) [1,2,3,4,5,6,7-11] wound treatment method for the treatment of post-pneumonectomy bronchial fistula empyema.

We found no evidence in the literature that this method has been used in this disease, but there have been examples in empyema without bronchial fistula [6,9,11]. Although we could not be sure of its efficacy, our experience so far has shown that this method has been able to provide healing previously considered unattainable for large deep septic wounds, such as sternal separation and suppuration after cardiac surgery, deep sacral decubitus in severe large burns.

The following treatment steps-were performed:

The open bronchial stump was covered with Epigard [12], the cavity was filled with polyurethane sponge of the VAC system and vacuum-assisted wound treatment was performed (Figure 5), while systemic imipenem treatment was used against *Acinetobacter* [4].

In our case, *Pseudomonas aeruginosa* was also sensitive to imipenem. If the cavity is suitable for closure surgery, i.e., sufficiently chick-free or no longer containing bacteria and oncological re-staging tests are negative, after computer-assisted surgical planning we perform thoraco-myoplasty with a m. latissimus dorsi flap containing a dorsal skin island rotated on a neurovascular handle.

Figure 5:

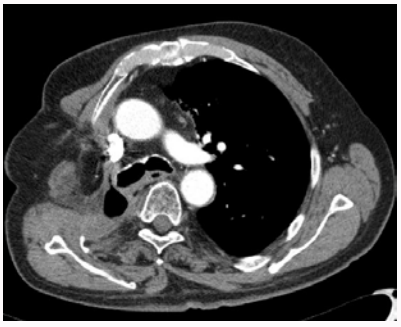

Figure 6:

After these events, however, we could not be absolutely sure of the complete eradication of *Ps. aeruginosa* and *Acinetobacter* after the closure surgery, so we again applied VAC treatment after the thoraco-myoplasty was performed, leaving a window through which vacuum-assisted wound treatment was applied until the myocutaneous seal on the bronchial stump was securely attached.

The treatment was hoped that the vacuum would help the seal to adhere to the bronchial stump, while sucking the wound fluid from the chest cavity. Once skin-muscle adhesion has been achieved and the secretions have stopped, as demonstrated by CT scans and sepsis marker results, the chest opening and skin are closed. However, this was no necessary in the present case because after the sell propagating effect of VAC treatment, the chest wall wound healed rapidly and the secondary wound healing resulted in the closure of the right chest cavity.

During subsequent follow-up examinations, we noted that a small residual or "rest" cavity had formed in the right main bronchial stump, which was found to be 35 cm^3 to 38 cm^3 by volumetric examination (Figure 6). Bacteriological clearance taken during the last bronchoscopic examination was negative, and occasionally the bronchial fluid accumulating in the cavity causes coughing fits in the mornings, but this is tolerated relatively well by the patient.

Discussion

Bronchiectasis following pneumonectomy is one of the most serious complications of lung surgery. Because of the severe septic condition that develops following bronchial stump fistula, the surgical criteria for immediate bronchial stump closure are usually not met, because these patients go into septic shock.

In the majority of cases, prolonged open treatment after fenestration is required, followed by stabilization and detoxification of the patients, after which the conditions for thoraco-myoplasty can be created after a longer or shorter period [13-16]. The risk of bronchial empyema after pneumonectomy is increased by neo-adjuvant and adjuvant oncological treatments and right laterality [17,18].

In our case, pulmonary fibrosis as a complication of irradiation and the threatening pulmonary gangrene made healing extremely difficult, open treatment was prolonged, and resistant pathogens settled in the right thoracic cavity open in both directions.

In our opinion, the use of VAC treatment significantly accelerated recovery, which is confirmed by the experience of Palmen et al. [15]. The conditions for thoraco-myoplasty are almost fully established. After the surgery was performed, VAC increased the chance of deepithelialized myocutaneous seal adhesion and led to bronchial flap closure and secondary tissue-growth based closure of the chest wall wound.

By describing the medical history of our patient, we wanted to draw attention to the difficult complications caused by an iatrogenic injury, severe fibrosis and inflammation caused by irradiation treatment. The recovery of the patient required several methods (fenestration, open treatment, bronchial stenting with Epigard, tracheobronchial stent, thoraco-myoplasty, VAC) used in chronic thoracic purulence. In this complex case with severe complications, we believe that only multidisciplinary harmonious collaboration can bring healing and acceptable quality of life to the patient.

References

1. Argenta LC, Morykwas MJ. Vacuum-assisted closure: A new method for wound control and treatment: Clinical experience. Ann Plast Surg. 1997;38(6):563-76.
2. Catarino PA, Chamberlain MH, Wright NC. High-pressure suction drainage *via* a polyurethane foam in the management of poststernotomy mediastinitis. Ann Thorac Surg. 2000;70(6):1891-5.
3. Debrecen T, Seraphin T, Galajda Z, Miskolczi Sz, Péterffy Á. Results of vacuum-assisted wound treatment in sternotomy wound infections after heart surgery. Magy Seb. 2008;61:29-35.
4. Bán É, Prinz Gy. Microbiological activity, pharmacokinetics and clinical application of carbapenems LAM. 2000;10:196-205.
5. Frytak S, Lee RE, Pairolero PC, Arnold PG, Shaw JN. Necrotic lung and bronchopleural fistula as complications of therapy in lung cancer. Cancer Invest. 1988;6(2):139-43.
6. Matzi V, Lindemann J, Porubsky N, Neuboeck N, Maier A, Smolle-Juetter FM. Intrathoracic insertion of the VAC device in a case plaural empyema 20 years after pneomenctomy. Ann Thorac. 2007;84(5):1762-4.
7. Morykwas MJ, Argenta LC, Shelton-Brown EI, McGuirt W. Vacuum-assisted closure: A new method for wound control and treatment: Animal studies and basic foundation. Ann Plastic Surg. 1997;38(6):553-62.
8. O'Connor J, Kells A, Henry S, Scalea T. Vacuum-assisted closure for the treatment of complex chest wounds. Ann Thorac Surg. 2005;79(4):1196-200.
9. Palmen M, van Breugel HN, Geskes GG, van Belle A, Swennen JM, Drijkoningen AH, et al. Open window thoracostomy treatment of empyema is accelerated by vacuum-assisted. Ann Thorac Surg. 2009:88(4):1131-6.
10. Tamhankar AP, Ravi K, Everitt NJ. Vacuum assisted closure therapy in the treatment of mesh infection after hernia repair. Surgeon. 2009;7(5):316-8.
11. Varker KA, Ng T. Management of emphysema cavity with the vacuum-assisted closure device. Ann Thorac Surg. 2006;81:723-5.
12. Balogh G, Ferenczy J. The role of Epigard in the surgical treatment of postpneumonectomic bronchial empyema with thoracic fistula. 1997;50:231-34.
13. Bán É, Prinz Gy. Microbiological activity, pharmacokinetics and clinical use of carbapenems. LAM. 2000;10:196-205.
14. Balogh G, Mendly J, Horváth Gy, Repa I. The role of CT examination in diagnostic and surgery of chronic empyema thoracis. Acta Chir Hung. 1999;38:9-12.
15. Molnar TF. Current surgical treatment of thoracic empyeman adults. Eur J Cardiothorac Surg. 2007;32:422-30.
16. Doddoli C, Barlesi F, Trousse D, Robitail S, Yena S, Astoul P, et al. One hundred consecutive pneumonectomies after induction therapy for non-small cell lung cancer: An uncertain balance between risks and benefits. Thorac Cardiovasc Surg. 2003;51:162-66.

17. Hampel M, Dally I, Walles T, Steger V, Veit S, Thomas K, et al. Impact of neo-adjuvant radiochemotherapy on bronchial tissue viability. Eur J Cardiothorac Surg. 2010;37(2):461-6.

18. Hollaus PH, Setinek U, Lax F, Pridun NS: Risk factors for bronchopleural fistula after pneumonectomy: Stump size does matter. Thorac Cardiovasc Surg. 2003;51(3):162-6.