Clinics in Surgery

Case Report
Published: 30 Jan, 2019

Multimodal Treatment of a Case of Synchronous Recurrent Hepatocarcinoma and Retroperitoneal Liposarcoma

Annamaria Auricchio, Francesca Cardella, Nicoletta Basile, Silvia Erario, Giovanni Del Sorbo, Paolo Castellano, Gennaro Galizia, Eva Lieto and Andrea Mabilia*

Department of Translational Medical Sciences, University of Campania 'Luigi Vanvitelli' - School of Medicine, Italy

Abstract

Background: The treatment of simultaneous oncological diseases in patients with other severe comorbidities may be challenging. Multimodality treatment including percutaneous ablation and surgical resection may represent a valid option.

Case Presentation: We report a singular case of a 71-year-old woman with diabetes, hypertensive heart disease, and HCV-related liver cirrhosis showing synchronous retroperitoneal liposarcoma and recurrent hepatocarcinoma. The patients have been treated, two years and one year before, with ablative therapy for hepatocarcinomas grown in the IV-V and IV-VIII hepatic segments, respectively. On November 2015, the patient was admitted at our Department for a large retroperitoneal liposarcoma in the left abdomen and preoperative imaging discovered a recurrent HCC at the site of the previous ablation. In order to offer a chance of cure to the patient, a multimodal approach was performed. It made up of two surgical phases, a thermoablative phase followed by a resective phase, with a combined surgical treatment: ultrasound-guided percutaneous radiofrequency ablation of recurrent hepatocarcinoma at the IV-VIII hepatic segments and removal of the retroperitoneal mass. By adopting this kind of strategy two main goals were achieved: treating two neoplastic lesions in two different organs at the same time, thus preserving the patient from multiple general anesthesia procedures.

Conclusion: Ablation is nearly 100% effective in hepatocellular carcinomas smaller than 2 cm, and survival is almost identical after resection or ablation. On the other hand, the complete resection of a retroperitoneal sarcoma remains the most important predictor of local recurrence and overall survival. Both procedures can be performed simultaneously.

Keywords: Hepatocellular carcinoma; Retroperitoneal liposarcoma; Multimodal treatment; Radiofrequency Ablation; Contrast-Enhanced ultrasound

OPEN ACCESS

Correspondence:
Francesca Cardella, Department of Translational Medical Sciences, University of Campania 'Luigi Vanvitelli' -School of Medicine, Italy, Tel: 390815665170; Fax: 390815665243; E-mail: francescacardella@gmail.com

Received Date: *04 Jan 2019*
Accepted Date*: 28 Jan 2019*
Published Date*: 30 Jan 2019*

Citation:
Auricchio A, Cardella F, Basile N, Erario S, Del Sorbo G, Castellano P, et al. Multimodal Treatment of a Case of Synchronous Recurrent Hepatocarcinoma and Retroperitoneal Liposarcoma. Clin Surg. 2019; 4: 2313.

Abbreviations

HCC: Hepatocellular Carcinoma; PRPLS: Primary Retroperitoneal Liposarcoma; MRI: Magnetic Resonance Imaging; MELD: Model for End-stage Liver Disease; CT: Computed Tomography; CEUS: Contrast-Enhanced Ultrasound; RFA: Radiofrequency Ablation; FISH: Fluorescence in Situ Hybridization; WDLS: Well-Differentiated Liposarcoma; QALY: Quality-Adjusted Life-expectancy; US: Ultrasound

Introduction

Hepato Cellular Carcinoma (HCC), the fifth most common cancer worldwide and the third cause of cancer mortality, accounts for almost 90% of primary liver cancers and, in the 70% to 80% of all cases, it is associated with liver cirrhosis [1]. Therapeutic strategies for HCC include surgical resection, transplantation and ablation. Hepatic resection is the treatment of choice in subjects not affected by liver cirrhosis, as they are able to tolerate important resections with a low risk of complications. On the contrary, resection should be evaluated case by case in cirrhotic patients, due to the high risk of postoperative hepatic failure. The percentage of cirrhotic patients fit for resection generally ranges between 5% and 10% of cases. Image-guided tumor ablation is less risky, less invasive but equally effective than resection in hepatocellular carcinomas with a diameter of less than 2 centimeters and, therefore, it is the gold standard in these patients [2].

Retroperitoneal liposarcoma accounts for 19% of all sarcomas. It is usually asymptomatic until it reaches considerable dimensions, or compress or infiltrate the surrounding organs. There

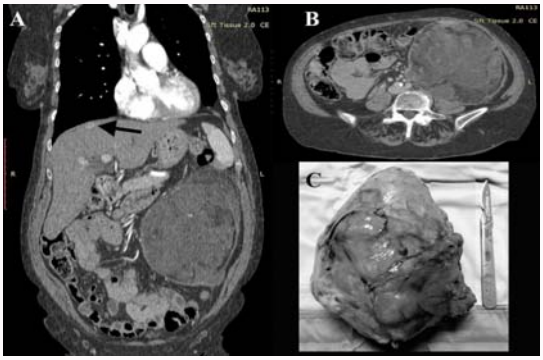

Figure 1: A) Preoperative CT scan (coronal view): Retroperitoneal liposarcoma in the left abdominal quadrants. The black arrow indicates the hypervascular recurrent HCC in the IV-VIII segments of the liver. B) Retroperitoneal liposarcoma (preoperative CT scan - axial view). C) Retroperitoneal liposarcoma (surgical specimen).

is currently no evidence that chemotherapy or radiotherapy may improve survival rates, and surgical potentially curative resection remains the cornerstone of treatment [3]. However, even with complete removal of the liposarcoma, the prognosis is related to the histological grade. The 5-year survival rate of well-differentiated retroperitoneal liposarcoma is 83%, while it is 20% for the dedifferentiated tumor subtypes [4]. We report a singular case of a female patient with simultaneous retroperitoneal liposarcoma and recurrent hepatocarcinoma successfully treated with potentially curative surgical resection and liver ablation, respectively. The choice to perform a multimodal treatment using different techniques proved to be successful and the patient is disease-free more than two years after treatment.

Case Presentation

On November 2015, a 72-year-old woman was referred to our Division of Surgical Oncology for surgical treatment of a giant left retroperitoneal liposarcoma. The patient complained of about three months of bowel movement pattern changes and palpable swelling in the left abdomen. The patient had previously undergone, in another center, two ablative therapies for small (Ø < 2 cm) HCCs grown in the IV-V segment and in the IV-VIII segment, two years and one year before, respectively. A recent abdominal ultrasound and an abdominal and pelvic Magnetic Resonance Imaging (MRI) had revealed liver calcifications to the IV and VIII segments, interpreted as outcomes of previous ablative therapies. In addition, a large mass with definite margins, and extending from the inferior pole of the left kidney to the ipsilateral iliac fossa, consistent with the diagnosis of retroperitoneal liposarcoma had been shown. The patient comorbidities were: hypertensive heart disease, diabetes mellitus type II in insulin therapy, and HCV-related liver cirrhosis. Child-Pugh score was 5 (class A), and MELD (model for end-stage liver disease) score was 7 (creatinine 0.87, bilirubin 0.59, INR 1.01, sodium 140, age 72 years). Before surgery, the patient was subjected to clinical, laboratory and instrumental evaluation. The physical examination revealed a prominent mass extending in the left abdomen, of stretched-elastic consistency, with definite margins, not painful to palpation. Presence of esophageal varices was assessed with endoscopy that revealed only a bulbar erosive duodenitis with a small Juxtapyloric hyperplastic polyp and a sliding hiatal hernia. Abdominal ultrasound showed a well-capsulated mixed mass in the left abdomen, and confirmed the presence, respectively at the IV and the IV-VIII

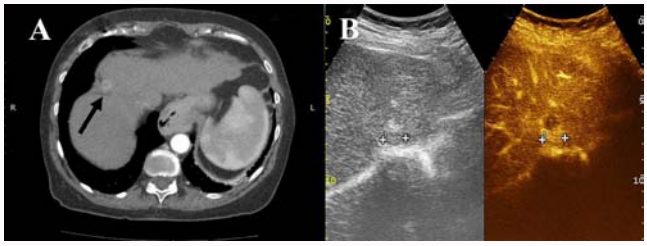

Figure 2: A) Preoperative CT scan of the liver (axial view): The black arrow indicates the hypervascular recurrent HCC in the IV-VIII segments of the liver. B) Preoperative abdominal ultrasound. At basal examination (left) a hypoechoic lesion (between the two calipers) in the IV-VIII segments was interpreted as outcome of the previous ablation. At contrast enhanced-ultrasound (right–colored) the same lesion (between the two calipers) showed a clear arterial blush suggesting a recurrent HCC.

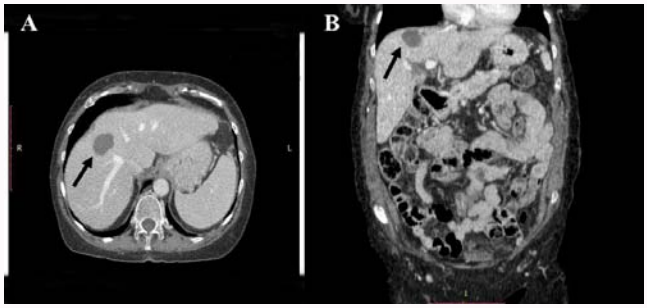

Figure 3: A) Thirty-days postoperative CT scan (axial view): the black arrow points, in the IV-VIII segments of the liver, a large area without contrast enhancement outcome of the hepatic ablation. B) Thirty-days postoperative CT scan (coronal view): the recurrent HCC in the IV-VIII segments of the liver appears completely ablated without contrast enhancement.

segments, of two areas of in homogeneity of Ø 1.5 cm, due to necrotic phenomena, interpreted as outcomes of the previous percutaneous ablative therapies. A chest and abdomen Computed Tomography (CT) scan confirmed, in the left abdominal quadrants, the presence of a voluminous solid, expanding, ovalariformneo formation bounded by a coarse capsule, containing a solid and vascularized component and a modest adipose part, surmounted by a thick extra capsular adipose capsule. Its overall dimensions were 14 cm × 13 cm on the axial plane with a longitudinal extension of 19 cm. It compressed and displaced medially the sigma and the ascending colon, from which it appeared to be dissociable, with signs of altered colonic and upstream ileal canalization. Posteriorly, it seemed to be in dissociable from the front perirenal adipose cellular tissue. The picture was suggestive for a retroperitoneal liposarcoma (Figure 1A,1B). In addition, CT scan showed, in the upper part of the already treated lesion of the IV-VIII segments, a centimetric hypervascular solid token in the arterial phase with portal wash out and hypodensity in equilibrium phase, strongly suspected for local recurrence of HCC (Figure 1A,2A). At a subsequent CEUS (contrast-enhanced ultrasound) this lesion showed, in the arterial phase, a hypervascular blush, with subsequent wash out in the portal and late phases, interpreted as a local recurrence (Figure 2B).

Although the general conditions were not optimal, it was decided to offer a chance of cure to the patient, treating simultaneously both oncological lesions. The patient signed written consent and the procedures were approved by the Ethical Committee of the Department of Surgical Sciences of our University. Therefore, on January 2016, the combined surgical treatment of percutaneous ultrasound-guided

Radiofrequency Ablation (RFA) of the residual HCC at the IV-VIII segments, and complete removal of the retroperitoneal mass was performed. The RFA treatment of the hepatic lesion was carried out using a 17G needle with an exposed tip of 3 centimeters and had a total duration of 12 minutes. The subsequent median laparotomy allowed highlighting a cirrhotic liver with outcomes of the previous ablative treatment, as well as the voluminous neoplastic tumefaction that appeared whitish, hard, strongly vascularized, multilobulated, of about 20 cm x 15 cm. The neoplasm occupied the left retroperitoneum, in front of the ipsilateral kidney and medially pushed the descending colon. It reached the left ovarian vascular bundle and the left ureter, at the top the lower pole of the spleen, and medially the mesenteric root, immediately to the left of the inferior mesenteric vein. The presence of a capsule allowed to completely removing the neoplasm (Figure 1C). The operation time was 135 minutes, and blood loss was 120 without intraoperative complications.

The patient recovered well from general anesthesia, and post-operative course was uneventful, with only slight delay in the canalization, which occurred on the fourth post-operative day, probably due to the manipulation of the large bowel. The patient was discharged twelve days after surgery. Both CEUS and CT scan, performed thirty days after surgery, allowed to verify the absence of active liver disease and the complete necrotic outcome in the area of the IV-VIII segments where RFA have been performed. In addition, the complete removal of the retroperitoneal lesion was confirmed (Figure 3A,3B). At pathological analysis, microscopy showed a neoplastic proliferation characterized by an extensive fibrillary collagenous stroma, in which some scattered multivacuolated lipoblasts and atypical stromal cells were present. Peripherally, the neoplasm was constituted by mature adipocytic tissue. In the central area of the proliferation, a focal condroid differentiation with ossification foci was evident. The neoplasm presented well circumscribed by a fibrous capsule. Necrosis was absent and 2 mitosis/10 HPF (high power fields) were detected. A FISH (fluorescence in situ hybridization) was performed and showed amplification of MDM2 gene. A final diagnosis of sclerosing well-differentiated liposarcoma (WDLS) with focal condroid differentiation was rendered.

After discharge the patient was subjected to oncological counseling that recommended exclusive clinical and instrumental follow-up, with laboratory tests and CT scan every 6 months. Currently, more than two years after surgery, the patient is in good health without radiological and/or clinical signs of recurrence of both neoplasms.

Discussion

The aim of our report is to underline the importance of have used, in this particularly complex patient, a multimodal approach, which was made up of two surgical phases: A thermoablative phase followed by a respective phase. By adopting this kind of strategy two main goals were achieved: treating two neoplastic lesions in two different organs and abdominal regions at the same time, thus preserving the patient from multiple general anesthesia procedures.

The percutaneous technique allowed to dramatically decreasing the overall time of the surgical procedure, since it was not necessary to first "prepare" and then resect the liver. More over the duration of the mere thermal ablative procedure took only 12 minutes. In addition, potentially curative RFA avoided the need for a hepatic resection in a cirrhotic liver already treated twice with ablative therapies. On the other hand, the subsequent median laparotomy allowed having full access to the abdominal cavity and visually checking both the outcome of the RFA and the absence of blood loss.

The optimal treatment for HCC born on a cirrhotic liver remains controversial. For many years liver resection and liver transplantation have been considered the only two potentially curative treatments [5,6]. Recently, tumor ablation has gained very wide consent and diffusion so much so, in selected patient, it has become the preferred approach [2,7,8]. Particularly, in very early Barcelona Clinic Liver Cancer stage [BCLC (single HCC < 2 cm, Child-Pugh A)]; in patients no fit for liver transplantation, tumor ablation is selected as the gold standard [2].

It has been shown that in patients affected by very early HCC, life-expectancy and quality adjusted life expectancy are similar between surgery and tumor ablation but with clear advantages in terms of cost-effectiveness for the latter [9]. In more advanced stages (i.e. stage A of BCLC classification), surgical treatments are preferred. However, just a small percentage of patients can undergo surgery because of liver reserve or poor performance status; for them and for patients waiting for transplantation as a bridge therapy, tumor ablation can be a valid alternative [2,8].

Treatment response depends on HCC dimensions: for lesions smaller than 2 cm the response is 100% , of about the 93% with lesions between 2 cm to 5 cm and drastically lower for dimensions >5 cm [10]. Tumor ablation can be associated to liver resection in patients having multisegmental liver diffusion, and offers particular advantages in resected patients showing intrahepatic recurrence [11,12]. In addition, its repeatability, with contained risks, makes it the most suitable approach in patients already treated with tumor ablation, as shown in our case.

It has to be emphasized the role of CEUS in the diagnosis of primary and recurrent HCC. With the introduction of second generation microbubble US contrast agents; CEUS has become an essential mean in the management and in the diagnosis of HCC, replacing the conventional B-mode ultrasound which was not always able to detect the target tumor and the recurrent or residual disease [13-15]. CEUS is a real time and low cost imaging technique with lots of advantages over CT and MRI, such as repeatability, pulmonary excretory route and mostly the detection of arterial-phase hyper vascularity and washout. Despite CT/MRI are standard methods for the diagnosis and post ablation monitoring of HCC, CEUS is fundamental in cases of doubt reports or when the CT/MRI imaging is not indicated. [16].

Retroperitoneal liposarcoma is the most frequently observed subtype of retroperitoneal tumor. PRPLS originate mainly from perirenal adipose tissue and can reach considerable size, without giving any clinical symptoms. The diagnosis is usually late and occurs only when the neoplasm cause infiltration or compression of the adjacent organs [3]. Macroscopically this type of tumor usually appears as a lobulated mass of round or oval shape, large (>10 cm), sometimes surrounded by satellite lesions, and tends to contract relations of close proximity with the surrounding vascular structures. Furthermore, due to the high degree of differentiation of adipocytes, it is often difficult to distinguish from normal retroperitoneal fat. All of these factors greatly limit the possibility of obtaining negative surgical margins and local recurrence is the most frequent cause of mortality for these patients [17]. On the other hand, large size and localization make treatment with tumoricidal doses of adjuvant

radiation difficult and are often associated with substantial morbidity. For well-differentiated PRPLS, even adjuvant chemotherapy is not very effective, given the low mitotic index of these lesions and the low tendency to metastasis; indeed the complete response rates to chemotherapy are less than 10% [18,19]. Therefore, complete surgical resection, although difficult to obtain representing a very challenge for the surgeon, is the optimal treatment and the most important predictor of local recurrence and overall survival [20].

The liposarcomas have been subdivided into a high-grade group (dedifferentiated, round cell, and pleomorphic) and a low-grade group (well-differentiated and myxoid) [21]. However, the extent of differentiation, expressed by histologic grade, represents the most important prognostic factor to determine both the clinical course and the final prognosis for patients with retroperitoneal liposarcoma after radical resection [22]. For low-grade neoplasms (WDLS), three main morphological subtypes are actually defined, including lipoma-like WDLS, sclerosing WDLS and inflammatory WDLS [23]. Sclerosing WDLS is particularly frequent in retroperitoneum and is characterized by an extensive fibrillary collagenous background, which may obscure the adipocytic cellular component, making the diagnosis particularly difficult. The diagnosis may be challenging also due to the morphological overlap between sclerosing WDLS, reactive inflammatory and fibroblastic proliferations and other low-grade soft tissue neoplasms with extensive collagenous background. The observation of typical multivacuolated lipoblasts is the morphological key for the diagnosis. However, because WDLS is characterized by the amplification of MDM2 gene on 12q14-15 region, the FISH (fluorescence in situ hybridization), as described in our case, may be very helpful in this setting. [24].

Conclusion

HCC developing on cirrhotic liver and retroperitoneal liposarcoma are two terrible and life-threatening diseases. Cirrhotic patients have a high risk of postoperative hepatic failure and a higher risk of complications due to the impairment of coagulation mechanisms. PRPLS patients need sometime surgery extended to neighboring structures in order to achieve tumor-free margins. In these very complex patients showing advanced oncological diseases, the possibility of using a multimodal approach reduces the duration and the invasiveness of surgical interventions and the risk of intra- and postoperative complications, allowing a shorter hospital stay.

In particular, in our case, using a percutaneous ablative technique combined with a laparotomic removal, we could effectively treat two malignant neoplasms in a cirrhotic patient with a single surgical procedure.

Declaration

Ethics approval and consent to participate: The patient signed written consent to both treatments. The procedure was approved by the Ethical Committee of the Department of Surgical Sciences of the University of Campania 'Luigi Vanvitelli' – School of Medicine – Naples – Italy (n° of approval 2016/125).

Consent for publication: The patient furnished the consent for publication of her person's data including images.

Availability of data and material: All data and material are available at the Department of Surgical Sciences of the University of Campania 'Luigi Vanvitelli' – School of Medicine – Naples – Italy.

References

1. El-Serag HB, Rudolph KL. Hepatocellular carcinoma: epidemiology and molecular carcinogenesis. Gastroenterology. 2007;132(7):2557-76.
2. Forner A, Llovet JM, Bruix J. Hepatocellular carcinoma. Lancet. 2012;379(9822):1245-55.
3. Zhang WD, Liu DR, Que RS, Zhou CB, Zhan CN, Zhao JG, et al. Management of retroperitoneal liposarcoma: A case report and review of the literature. Oncol Lett. 2015;10(1):405-409.
4. Fabre-Guillevin E, Coindre JM, Somerhausen NS, Bonichon F, Stoeckle E, Bui NB. Retroperitoneal liposarcomas: follow-up analysis of dedifferentiation after clinicopathologic reexamination of 86 liposarcomas and malignant fibrous histiocytomas. Cancer. 2006;106(12):2725-33.
5. Grandhi MS, Kim AK, Ronnekleiv-Kelly SM, Kamel IR, Ghasebeh MA, Pawlik TM. Hepatocellular carcinoma: From diagnosis to treatment. Surg Oncol. 2016;25(2):74-85.
6. Yegin EG, Oymaci E, Karatay E, Coker A. Progress in surgical and nonsurgical approaches for hepatocellular carcinoma treatment. Hepatobiliary Pancreat Dis Int. 2016;15(3):234-56.
7. Viganò L, Laurenzi A, Solbiati L, Procopio F, Cherqui D, Torzilli G. Open liver resection, laparoscopic liver resection, and percutaneous thermal ablation for patients with solitary small hepatocellular carcinoma (≤ 30 mm): review of the literature and proposal for a therapeutic strategy. Dig Surg. 2018;35(4):359-71.
8. Facciorusso A, Serviddio G, Muscatiello N. Local ablative treatments for hepatocellular carcinoma: An updated review. World J Gastrointest Pharmacol Tcher. 2016;7(4):477-89.
9. Cucchetti A, Piscaglia F, Cescon M, Colecchia A, Ercolani G, Bolondi L, et al. Cost-effectiveness of hepatic resection versus percutaneous radiofrequency ablation for early hepatocellular carcinoma. J Hepatol. 2013;59(2):300-07.
10. Gosalia AJ, Martin P, Jones PD. Advances and future directions in the treatment of hepatocellular carcinoma. Gastroenterol Hepatol. 2017;13(7):398-410.
11. Díaz-González Á, Reig M, Bruix J. Treatment of Hepatocellular Carcinoma. Dig Dis. 2016;34(5):597-602.
12. Shiina S, Tateishi R, Arano T, Uchino K, Enooku K, Nakagawa H, et al. Radiofrequency Ablation for Hepatocellular Carcinoma: 10-Year Outcome and Prognostic Factors. Am J Gastroenterol. 2012;107(4):569-77.
13. Maruyama H, Takahashi M, Ishibashi H, Okugawa H, Okabe S, Yoshikawa M, et al. Ultrasound-guided treatments under low acoustic power contrast harmonic imaging for hepatocellular carcinomas undetected by B-mode ultrasonography. Liver Int. 2009;29(5):708-14.
14. Miyamoto N, Hiramatsu K, Tsuchiya K, Sato Y. Contrast-enhanced sonography-guided radiofrequency ablation for the local recurrence of previously treated hepatocellular carcinoma undetected by B-mode sonography. J Clin Ultrasound. 2010;38(7):339-45.
15. Minami Y, Kudo M, Hatanaka K, Kitai S, Inoue T, Hagiwara S, et al. Radiofrequency ablation guided by contrast harmonic sonography using perfluorocarbon microbubbles (Sonazoid) for hepatic malignancies: an initial experience. Liver Int. 2010;30(5):759-64.
16. Kim TK, Khalili K, Jang HJ. Local ablation therapy with contrast-enhanced ultrasonography for hepatocellular carcinoma: a practical review. Ultrasonography. 2015;34(4):235-45.
17. Lee SY, Goh BK, Teo MC, Chew MH, Chow PK, Wong WK, et al. Retroperitoneal liposarcomas: the experience of a tertiary Asian center. World J Surg Oncol. 2011;9:12.
18. Fuks D, Verhaeghe JL, Marchal F, Guillemin F, Beckendorf V, Peiffert D, et al. Surgery and postoperative radiation therapy in primary retroperitoneal

sarcomas: Experience of the cancer centre Alexis-Vautrin. Cancer Radiother. 2012;16(3):194-200.

19. EI-Bared N, Taussky D, Mehiri S, Patocskai E, Roberge D, Donath D. Preoperative intensity modulated radiation therapy for retroperitoneal sarcoma. Technol Cancer Res Treat. 2014;13(3):211-16.

20. Wu YX, Liu JY, Liu JJ, Yan P, Tang B, Cui YH, et al. A retrospective, single-center cohort study on 65 patients with primary retroperitoneal liposarcoma. Oncol Lett. 2018;15(2):1799-1810.

21. Tan MC, Brennan MF, Kuk D, Agaram NP, Antonescu CR, Qin LX, et al. Histology based classification predicts pattern of recurrence and improves risk stratification in primary retroperitoneal sarcoma. Ann Surg. 2016;263(3):593-600.

22. Singer S, Antonescu CR, Riedel E, Brennan MF. Histologic subtype and margin of resection predict pattern of recurrence and survival for retroperitoneal liposarcoma. Ann Surg. 2003;238(3):358-71.

23. Jo VY, Fletcher CD. WHO classification of soft tissue tumours: an update based on the 2013. 4th edn. Pathology. 2014;46(2):95-104.

24. Fletcher CDM, Bridge JA, Hogendoorn P, Mertens F. WHO Classification of Tumours of Soft Tissue and Bone. 4th edn. Lyon: IARC;2013.