Clinics in Surgery

Research Article
Published: 23 Dec, 2016

Moon Bridge Bar Stabilization: The Way Forward for Bar Stabilization in Minimally Invasive Repair of Pectus Excavatum and Pectus Carinatum

Laleng M Darlong[1], Ashwani K Sharma[2], Dharma Poonia[2], Himanshu Shukla[2] and Deepak Sharma[2]*

[1]Head of Thoracic Oncosurgery, Rajiv Gandhi Cancer Institute & Research Centre, India

[2]Division of Thoracic Surgery, Rajiv Gandhi Cancer Institute & Research Centre, India

Abstract

Objective: The minimally invasive repair of pectus deformity is associated with risk of bar displacement due to sutures around the bar giving way. This may result in recurrence with revision surgery, internal organ injury requiring immediate care, undesirable adhesion along displaced bar complicating bar removal. In order to overcome the immediate or late complications of bar displacement we developed a technique for bar stabilization in the minimally invasive repair of pectus deformity.

Methods: In September 2012 a T plate system for reverse NUSS procedure was developed to obtain a stable sternal compression for pectus carinatum. This was later applied to all cases of minimally invasive repair of pectus deformity following the use of 1/3 tubular plate.

Results: The moon bridge bar stabilization provided a mechanically stable fixation technique with no bar displacement reported on morphological evaluation or chest X-ray examination in all the 14 cases over a follow up of 25 months to 38 months.

Conclusion: In the minimally invasive repair of pectus deformity the Moon Bridge bar stabilization technique provided a rigid and stable bar framework avoiding complications of displacement and is the way forward in chest wall deformity correction.

Keywords: Moon bridge bar; NUSS procedure; Reverse NUSS; Pectus excavatum (PE); Pectus carinatum (PC)

OPEN ACCESS

Correspondence:
**Corresponding author: Laleng M Darlong, Head of Thoracic Oncosurgery, Rajiv Gandhi Cancer Institute & Research Centre, Room no 2062, Rohini Sector 5, Delhi, India, Tel: 919958919595; Fax: 911147022222; E-mail: lmdarlong@gmail.com*

Received Date: *01 Sep 2016*
Accepted Date*: 16 Dec 2016*
Published Date*: 23 Dec 2016*

Citation:
Darlong LM, Sharma AK, Poonia D, Shukla H, Sharma D. Moon Bridge Bar Stabilization: The Way Forward for Bar Stabilization in Minimally Invasive Repair of Pectus Excavatum and Pectus Carinatum. Clin Surg. 2016; 1: 1256.

Introduction

The minimally invasive repair of pectus excavatum (PE) and pectus carinatum (PC) using the NUSS procedure and reverse NUSS involve placing bars in a stable position to lift or compress the bony rib cage and sternum. It is very important that the desired bar position is maintained till bar removal which usually occurs after 2 to 3 years to achieve morphologic correction and avoid complications. To achieve bar stability for chest wall deformity correction a number of techniques have been described. The bar stabilizer [Biomet Micro fixation, Jacksonville, FL], multiple suture, wire and fibre wire fixation of bar with ribs, claw fixators [The Prime Med. Co.,Seoul, Korea] hooked to the ribs are amongst the many described in the literature [1-5]. However all of these fixation techniques have the risk of the suture loosening up or breaking away because of the tension on the bar and has been reported to be as high as 27.8% [6]. The suture breakdown when it occurs early in the repair can cause an unstable bar with displacement and recurrence and also potential internal organ compression and injury [6,7]. The incidence of bar displacement using the original NUSS was 15% and with stabilizers 5% which is further reduced to about 1% when the bars are fixed with multiple sutures to the ribs [7-9]. In minimally invasive repair of PE the ends of the bar are the weakest spot for suture fixation to give way and also the point for application of compressive force on the chest wall in PC. In order to overcome this problem of bar displacement we devised a technique of stabilizing the ends of bar to a plate system using a mechanically stable clip and nut system which can be tightened. This originally started in reverse NUSS for pectus excavatum-recurvatum complex to provide traction force on the bar for chest wall compression which was later applied to cases of NUSS procedure for PE. The configuration of the bar which forms an arch resting on the plate on both ends resembles the Chinese moon bridge which was either lifting or

Figure 1: Stainless steel bar with rectangular hollow at the ends forming the arch of the moon bridge.

Figure 2: 3.5 mm 1/3 tubular plates with holes for foundation of the moon bridge.

Figure 3: Clip and nut system to stabilize bar and plate together.

compressing the chest wall and thus named it as Moon Bridge bar stabilization technique [10]. These stable positioning of the bar avoids bar displacement causing compression of vital structures or adhesion formation with vital structure which could lead to major injuries during treatment or bar removal. The moon bridge bar stabilization technique provides a stable plate foundation for the bars to be fixed in single or double bar repair and is the way forward for bar stability in minimally invasive repair of pectus deformity.

Material and Methods

All the procedure was performed by the author for PE and PC undergoing minimally invasive repair. The Moon Bridge stabilization technique has three components:-

1) Stainless steel bar with rectangular hollow at the ends (Primemed, Seoul S.korea) forming the arch of Moon Bridge (Figure 1). The rectangular hollow is originally designed by Dr Park for the placement of claw fixators [3].

2) 3.5 mm 1/3 tubular plate (aesculap orthopedics) with multiple holes for the foundation of the Moon Bridge (Figure 2).

3) Clip and nut system (Primemed, Seoul S.korea) for mechanical stabilization of the bars and plates (Figure 3).

The idea of moon bridge bar stabilization started in a case of pectus excavatum- carinatum complex in September 2012 for a reverse NUSS procedure where a T plate was fixed to the bar with the clip and nut system to provide compressive force on the sternum by suture fixation to ribs. Following this from October 2013 we modified our technique for bar stabilization using the 3.5 mm 1/3 tubular plate for minimally invasive repair of pectus deformity. The following are the features of the 3.5 mm 1/3 tubular plate.

1) Routinely used in orthopedics for fracture stabilization.

2) Cheap and easily available.

3) The holes in the plate fit the clip allowing bar to be fixed to the plate with nut over it.

4) A desired length of plate can be cut on table.

Technique

The procedure was performed under general anesthesia in the supine position with the right arms placed overhead and the left arm abducted. A bilateral mid-axillary 2-3 cm skin incision was used for placing the bars across the chest at the level of the anterior axillary line.

Moon bridge stabilization for reverse NUSS

In this procedure the middle of the 1/3 tubular plate was fixed to the presternal bar with clip and nut system across the rectangular hollow of the bar. The tubular plate was then fixed with non-absorbable suture or wire to the underlying ribs above and below the level of the bar at 2 points. The procedure is duplicated on the other side of the chest. The clip and nut system holding the bar to the fixed tubular plates when loosened allowed sliding movement of the bar across the rectangular hollow when external compressive force was applied on the sternum. Following these clips and nut system was

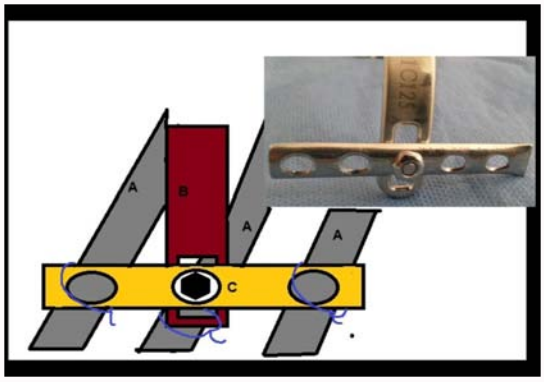

Figure 4: Illustration of the 3 point suture fixation of plate to three adjacent ribs and bar stabilized to the plate with clip and nut system. A) Obliquely placed ribs. B) Bar fixed to the plate with clip and nut system across the rectangular hollow. C) 3.5 mm 1/3 tubular plate fixed to 3 underlying ribs with sutures.

Figure 5: Single and double bar Moon Bridge bar stabilization.

tightened for stabilization on both sides to a desired morphological correction of the PC. The ends of the bar is then fixed with sutures passing through the hollow end of the bar and plate to the underlying ribs thus providing 3 point stabilization of plate to chest wall (Figure 4).

Moon bridge stabilization for NUSS procedure

The Moon Bridge stabilization in NUSS procedure for single and double bars is as follows.

Single bar moon bridge stabilization: After placing the retrosternal bar and achieving desired morphological correction on table the tubular plate is fixed with clip and nut system to the bar. The tubular plate is fixed to the adjacent 3 ribs as in reverse NUSS on both sides. The clip and nut system holding the bar to the fixed tubular plates when loosened allowed rotational movement of the bar across the rectangular hollow on both ends. Following these clips and nut system was tightened on both sides for stabilization of bar at the desired angle for morphology correction of PE (Figure 5).

Double bar moon bridge stabilization: In this procedure after the two retrosternal bars were placed and the desired correction achieved based on the morphology of the chest wall, the distance between the upper and lower end of the bar was measured on both

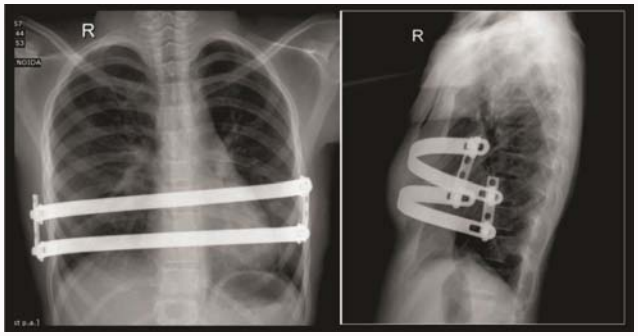

Figure 6: Chest X-ray postero-anterior & lateral view of NUSS procedure with the double bar moon bridge stabilization.

sides. The distance provides the approximate length of the 1/3 tubular plate to be used for moon bridge stabilization. The tubular plate is then fixed to the end of the 2 bar with clip and nut system. This step is facilitated by the rectangular hollow at the end of the bar allowing straight or angulated placement of the plate in the desired interbar distance on both sides. The bars are then fixed with the clip and nut system to the plates in the desired angulation. The procedure is repeated on the other side of the chest to complete the moon bridge stabilization for double bars (Figure 5).

Result

The moon bridge stabilization of two bars to the plates using the clip and nut system provided a solid framework for lifting the chest wall without the risk of bar displacement. This technique also avoids any further requirement of fixing the bars to the ribs thus avoiding strangulation of the intercostal muscle and neurovascular bundle which causes pain. However in single bar Moon Bridge stabilization at the present time till fixation devices to the ribs are designed it requires the use of sutures to stabilize the plates to the ribs. Table 1 shows the characteristics of patients who underwent minimally invasive repair of pectus deformity using the moon bridge fixation technique. The study includes the first case where a T plate was used for pectus excavatum recurvatum complex in September 2012 and cases from September 2013 till June 2014 when we introduced the

Table 1: PE-Pectus excavatum, PC-Pectus carinatum, HI-Hallers index, AI-Asymmetry index.

	Age/sex	Diagnosis	Hallers index / asymmetry index	Procedure	Follow up in months
1	19/M	Pectus excavatum carinatum complex	HI 3.3	Reverse NUSS moon bridge combined with NUSS using claw fixator stabilization.	38 months
2	16/M	PE	AI 0.89	Moon bridge double bar	32 months
3	18/M	PE	HI 04	Moon bridge double bar	34 months
4	07/M	PE	HI 5.3	Moon bridge single bar	33 months
5	20 /M	PE	HI 06	Moon bridge double bar	33 months
6	33/M	PC		Reverse NUSS moon bridge	14 months
7	14/M	PE	HI 5.6 AI 0.83	Moon bridge double bar	33 months
8	17M	PE	HI 5.01	Moon bridge double bar	33 months
9	19/M	PC		Reverse NUSS moon bridge	31 months
10	30/M	PE	HI 4.4	Moon bridge double bar	28 months
11	51/M	PE	HI 3.7 AI 0.85	Moon bridge double bar	28 months
12	34/M	PC		Reverse NUSS moon bridge	27 months
13	13/F	PE	HI 3.92 AI 0.71	Moon bridge double bar	26 months
14	22/F	PE	HI 8.2 AI 0.72	Moon bridge double bar	25 months

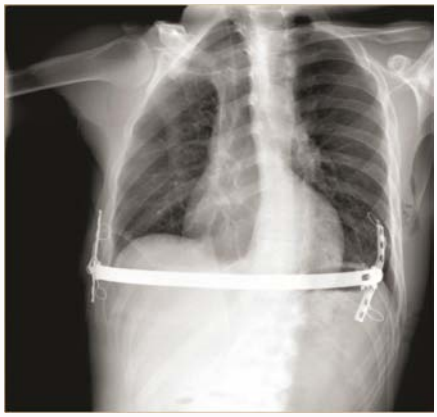

Figure 7: Chest X-ray oblique view for reverse NUSS with moon bridge stabilization.

3.5 mm 1/3 tubular plate. The initial 14 patients who underwent bar stabilization using the moon bridge stabilization technique have been described. The age group varied from 07 years to 51 years. During a follow up period ranging from 14 months to 38 months there was no reported bar displacement morphologically or on chest x ray evaluation (Figures 6-7). Bar removal has been performed for pectus carinatum at 14 month and at 38 months for pectus excavatum – carinatum complex. No comparison can be made with other stabilization technique in terms of displacement, revision surgery or bar removal complications till a larger number of cases are followed till bar removal.

Comments

The rib cage is formed of flat bones running in an oblique direction while the bars are placed in a transverse direction as a result of which the bars don't run along a single rib. For a stable suture fixation of bar it is important that the bar and rib run in the same direction so that it is fixed to the underlying rib and not adjacent ribs which tend to include muscle making the bar loose and strangulating the muscle and neurovascular bundle to produce more pain. Technically it is very difficult to achieve this ideal suture fixation of bar to ribs because the rib and the ends of the bar never lie in the same direction. The moon bridge fixation technique aims at eliminating this weak point by providing a solid stabilization of the bar ends. In the reverse NUSS procedure the 1/3 tubular plates fixed at the ends of the bar provides a traction force on the bar which is distributed to 3 adjoining ribs with wire or sutures (Figure 4). The stable fixation of the 1/3 tubular plate to 3 different ribs results in a stable bar which is tightened with clip and nut system in the desired position and compression. In case of NUSS procedure when a single bar is used the 1/3 tubular plate which is fixed at 3 different ribs provides a stable foundation on which the bar is stabilized with clip and nut system in the desired position (Figure 4). Usually those cases requiring a single bar have a less rigid bone and focal defect with lesser force of displacement on the bar. The double bar repair done for adults, teenagers or those with longer defects are the ones with a higher risk of bar displacement in view of the rigid bones exerting a greater force for displacement on the bar. The double bar bridge fixation by virtue of holding the two bars together as a single unit joined by 1/3 tubular plates stabilized with clip and nut system provides a solid structural framework for the corrected chest wall to rest upon. Double bar bridge fixation does not require any suture fixation of the bar or plates to the chest wall, which eliminates the trauma and pain of strangulating muscle and neurovascular bundle arising from the use of suture fixation to ribs. The stable positioning of the bar in NUSS and reverse NUSS is critical for a successful and safe correction of pectus deformities. Any instability in the bar can lead to recurrence of deformity, migration of bar towards the rib with abnormal ossification or compression injuries to the underlying internal organs which may be asymptomatic or not noticed but have potential for complications at a later period [6,7,11,12]. An independent survey of the initial 20 years of Nuss procedure reported an incidence of 5.7% bar displacement requiring revision surgery, Hebra and associates reported reoperation for bar displacement in 9.2% following analysis of results among members of American pediatric surgical association APSA [13,14]. Bar displacement at any point of time during treatment should not be ignored and there are reports of delayed and asymptomatic bar displacement causing dangerous internal organ injury at bar removal due to formation of undesirable dense adhesion to the lung or great vessels by the displaced bar [15-19].

To summarize it is important to emphasize on the following published literature for safe placement of stable bar with intact pericardium using the following technique.

1) Sternal elevation to increase retrosternal space for safe dissection avoiding pericardial tear [20,21].

2) Retrosternal dissection under vision to avoid pericardial tear which could lead to undesirable adhesion between pericardium and myocardium with potential implications at bar removal [22].

3) Pectus-tunneloscopy- A real time endoview inspection of the retrosternal space and underlying pericardium where bars will lie and a guided passage of the bar across the crucial space [23].

4) Maintaining a stable bar throughout the period of treatment [1-5].

The minimally invasive repair of pectus deformity using the moon bridge bar stabilization with clips and nut system hold the ends of the bars to the plate in the desired position and also avoid dangerous adhesion which can arise in a displaced bar and is the way forward to a safe and desired morphological correction of pectus deformities.

Acknowledgement

Dr. Sanchia D. Darlong for Support extended towards editing of the manuscript.

References

1. Nuss D, Kelly RE, Croitoru DP, Katz ME. A 10-year review of a minimally invasive technique for the correction of pectus excavatum. J pediatr surg. 1998; 33: 545-552.

2. Yüksel M, Bostanci K, Evman S. Minimally invasive repair of pectus carinatum using a newly designed bar and stabilizer: a single-institution experience. Eur j cardiothorac surg. 2011; 40: 339-342.

3. Park HJ. Minimally Invasive Surgery for Pectusexcavatum: Park technique. J clin analytical med. 2011; 2: 84-90.

4. Hebra A, Gauderer MW, Tagge EP, Adamson WT, Othersen HB. A simple technique for preventing bar displacement with the Nuss repair of pectus excavatum. J pediatr surg. 2001; 36: 1266-1268.

5. Park HJ, Chung WJ, Lee IS, Kim KT. Mechanism of bar displacement and corresponding bar fixation techniques in minimally invasive repair of pectus excavatum. J pediatr surg. 2008; 43: 74-78.

6. Castellani C, Schalamon J, Saxena AK, Hoellwarth ME. Early complicationsof the Nuss procedure for pectusexcavatum: a prospective

study. Pediatr surg int. 2008; 24: 659-666.

7. Nuss D. Minimally invasive surgical repair of pectusexcavatum. Semin pediatr surg. 2008; 17: 209-217.

8. Park HJ, Jeong JY, Jo WM, Shin JS, Lee IS, Kim KT, et al. Minimally invasive repair of pectus excavatum: A novel morphology-tailored, patient-specific approach. J thorac cardiovasc surg. 2010; 139: 379-386.

9. Kelly RE, Goretsky MJ, Obermeyer R, Kuhn MA, Redlinger R, Haney TS, et al. Twenty-one years of experience with minimally invasive repair of pectus excavatum by the Nuss procedure in 1215 patients. Ann surg. 2010; 252: 1072-1081.

10. Sullivan C, Boults E. Illustrated History of Landscape Design. Hoboken, NJ: J. Wiley. 118.

11. Morimoto K, Imai K, Yamada A, Fujimoto T, Matsumoto H, Niizuma K. Migration of pectus bar into the ribs. J plast reconstr aesthet surg. 2008; 61: 225-227.

12. Giacomo TD, Diso D, Francioni F, Anile M, Venuta F. Minimally invasive pectus excavatum repair: migration of bar and ossification. Asian cardiovasc thorac ann. 2013; 21: 88-89.

13. Protopapas AD, Athanasiou T. Peri-operative data on the Nuss procedure in children with pectus excavatum: independent survey of the first 20 years' data. J cardiothorac surg. 2008; 4: 40.

14. Hebra A, Swoveland B, Egbert M, Tagge EP, Georgeson K, Othersen HB, et al. Outcome analysis of minimally Invasive repair of pectus excavatum: Review of 251 cases. J pediatr surg. 2000; 35: 252- 258.

15. Carluccia M, Torrea M, Jasonnia W. An uncommon complication of Nuss bar removal: Is blind removal a safe procedure. J pediatr surg case reports. 2013; 3: 34-35.

16. Jemielity M, Pawlak K, Piwkowski C, Dyszkiewicz W. Life-threatening aortic hemorrhage during pectus bar removal. Ann thorac surg. 2011; 593-595.

17. Hoel TN, Rein KA, Svennevig JL. A life-threatening complication of the Nuss procedure for pectus excavatum. Ann thorac surg. 2006; 81: 370-372.

18. Barsness K, Bruny J, Janik JS. Delayed near-fatal hemorrhage after Nuss bar displacement. J pedatr surg. 2005; 40: E4-6.

19. Leonhardt J, Kübler JF, Feiter J, Ure BM, Petersen C. Complications of the minimally invasive repair of pectus excavatum. J pediatr surg. 2005; 40: E7-9.

20. Park HJ, Chung WJ, Jo WM, Shin JS, Lee IS, Kim KT. A novel technique for adult pectus excavatum: the extended Nuss procedure. Interactive cardiovasc thorac surg. 2006; 5: 118-121.

21. Belcher E, Arora S, Samancilar O, Goldstraw P. Reducing cardiac injury during minimally invasive repair of pectus excavatum. Eur j cardiothorac surg. 2008; 33: 931-933.

22. Bouchard S, Hong AR, Gilchrist BF, Kuenzler KA. Catastrophic cardiac injuries encountered during the minimally invasive repair of pectusexcavatum. Semin pediatr surg. 2009; 18: 66-72.

23. Darlong LM. Pectus tunneloscopy: making Nuss procedure for pectus excavatum safe. Interact cardiovasc thorac surg. 2013; 17: 233-236.