Clinics in Surgery

Case Report
Published: 29 Mar, 2017

Modified Canaloplasty in the Treatment of Neovascular Glaucoma Coexisting Angle-Closure

Cheng Hu[1], Cong Ye[1,2], Yuan Bo Liang[1,3] and Jia Qu[1]*

[1]Department of Ophthalmology and Optometry, Wenzhou Medical University, China

[2]Department of Ophthalmology and Visual Sciences, Chinese University of Hong Kong, China

[3]Department of Public Health, Queen's University, UK

Abstract

This case report presents a modified canaloplasty surgery in the treatment of neovascular glaucoma (NVG) coexisting angle-closure. We combine canaloplasty with trabeculectomy as a bleb-free surgical option for lowering intraocular pressure and call this procedure "penetrating canaloplasty".

Introduction

Non-penetrating surgery has recently emerged as a potential alternative to traditional guarded filtration surgery in the surgical treatment of open angle glaucoma [1,2]. Canaloplasty has showed the longevity of safety and efficacy. Lewis et al. [1,3,4] reported 1st, 2nd and 3rd year results in multicenter prospective clinical study of analoplasty in primary open angle glaucoma (POAG), and proved that canaloplasty yielded a significant reduction in IOP and antiglaucoma medication use with few surgical complications. However, all of recent researches of canaloplasty are only applicable for POAG, because of the obstruction of iris in the anterior chamber angle in angle-closure glaucoma, primary angle-closure glaucoma (PACG) is the contraindication of this surgery [5-8]. We report for a new approach, penetrating canaloplasty surgery which combines canaloplasty with trabeculectomy, in the treatment of neovascular glaucoma (NVG) coexisting angle-closure.

Case Presentation

A 64-year-old woman, who has been suffered diabetes for 16 years, developed neovascular glaucoma (NVG) in her right eye in 2015, treated with anti-VEGF (intravitreal conbercept) in local hospital. One month later, IOP was still very high and then was referred to our clinic. The patient was presented with headache, ocular pain, blurring vision and high IOP. Visual acuity in her right eye was FC/20 cm, with her left eye was HM/20 cm. Intraocular pressure (IOP) was 44.0 and 10.0 mmHg in the right and left eyes, respectively. The preoperative average IOP in right eye was 42.5 mmHg with 3 antiglaucoma medicines. Gonioscopy showed a 360° peripheral anterior synechia covered the angle in right eyes. Slit lamp examination for the right eye did not reveal any new vessels in iris. Axial length was 21.97 mm in her right eye, with 21.74 mm in the left. The cup–disc ratio was 1.0 in right eye; the funds of left eye could not be seen because of cataract and vitreous opacity. Humphrey visual field testing did not complete due to her bad visual acuity. Ultrasound biomicroscopy (UBM, Figure 1) and gonioscopy examination revealed a closure angle of the whole circle of the right eye. The patient was enrolled to have the penetrating canaloplasty procedure using the micro catheter. The micro catheter had a 200 mm diameter shaft with and a traumatic distal tip approximately 250 mm in diameter. The device incorporated an optical fiber to provide an illuminated beacon tip to assist in surgical guidance. The illuminated tip was seen transsclerally during catheterization of Schlemm canal to identify the location of the distal tip of the micro catheter. The micro catheter had a lumen with a proximal Luer lock connector through which an ophthalmic viscosurgical device (OVD) was delivered. The micro catheter was packaged with an OVD injector replacing the standard push syringe used to deliver OVDs to allow more precise injection of micro liter volumes. Surgery starts with a fornix-based conjunctival flap and a 4 × 4 mm superficial scleral flap, similar to that performed in deep sclerectomy. A deep scleral flap is then sculpted, and Schlemm's canal is opened and deroofed by the removal of the innerwall, which is performed after paracentes is in order to lower the IOP, thus reducing the risk of perforation of the trabeculodescemet membrane. The deep scleral flap is removed and the two ostia of the canal are dilated with high molecular weight hyaluronic acid (Healon GV), similarly to a viscocanalostomy.

OPEN ACCESS

Correspondence:
Yuan Bo Liang, Department of Ophthalmology and Optometry, Wenzhou Medical University, Wenzhou, Zhejiang, 325027, China; No.270, West College Road, Wenzhou, Zhejiang, China, Tel: +86-577-88053493; E-mail: yuanboliang@126.com

Received Date: *15 Dec 2016*
Accepted Date*: 15 Mar 2017*
Published Date*: 29 Mar 2017*

Citation:
Hu C, Ye C, Liang YB, Qu J. Modified Canaloplasty in the Treatment of Neovascular Glaucoma Coexisting Angle-Closure. Clin Surg. 2017; 2: 1369.

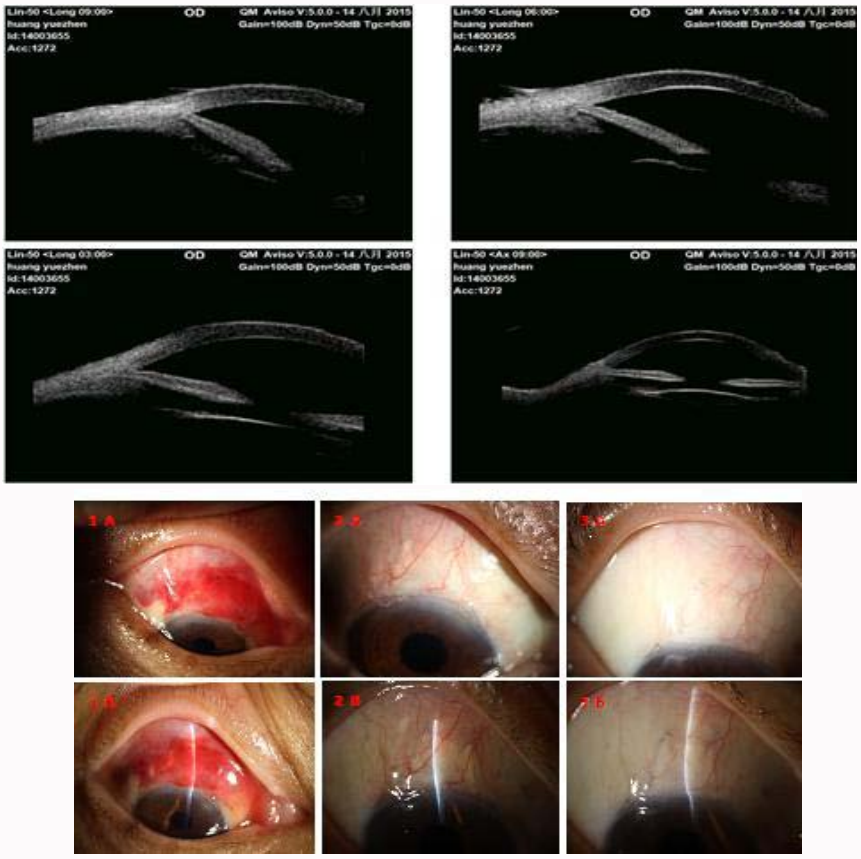

Figure 1: Ultrasound biomicroscopy (UBM) images of the right eye, with deep anterior chamber, flatten iris, but trabecular meshwork were covered with synechia.

A 200 micron micro catheter (iTrack by iScience Interventional, Menlo Park, CA, USA), which is connected to a laser flickering red light source for an easy identification of the distal tip through the sclera, is then inserted and pushed forward within Schlemm's canal for the entire 360° degrees until it comes out of the other end of the of the canal opening. A double 10-0 prolene suture is then tied to the distal tip and the micro catheter is withdrawn and pulled back through the canal in the opposite direction. A small amount of viscoelastic agent is delivered in Schlemm's canal at every two clock hours while the catheter is withdrawn with the aid of a special screw-driven syringe. The suture was then knotted under tension in order to inwardly distend the trabecular meshwork. Then cut off the deep trabecular tissue between Schlemm canal and the cornea, and the respective iris root was cut. Finally the superficial sclera flap is tightly sutured with 10-0 prolenesutures to ensure a watertight closure preventing any bleb formation. The conjunctival flap is then sutured with 10-0 prolenesutures [5]. The IOP was lowered to 23.5 mmHg at 1 month postoperative, 22.5 mmHg at 4 month postoperative with no glaucoma edications use, no conjunctival bleb and no other complications occurred. Her visual acuity sustained 0.2 stably at 1st and 4th month postoperative.

Discussion

Neovascular glaucoma (NVG) is a secondary glaucoma generally with poor visual prognosis. The new vessels over the iris and the anterior chamber angle can obstruct aqueous humor outflow pathway and lead to the high intraocular pressure. The underlying pathogenesis is posterior segment ischemia, which is most commonly secondary to proliferative diabetic retinopathy and central vein retinal occlusion. The process of neovascularization is driven by the disruption of homeostatic balance between pro-angiogenic factors and anti-angiogenic factors [9]. Although the mainstay of therapy of NVG is the treatment of retinal ischemia with panretinal photocoagulation [10], surgical interventions to reduce IOP are quite necessary since the use of glaucoma medications cannot prevent optic nerve damage, especially in the cases which angle closure have occurred. Surgical interventions for NVG include: glaucoma drainage devices, trabeculectomy, cyclophoto coagulation and so on. NVG is a refractory type of secondary glaucoma, which poses a challenge for the IOP control and is often associated with increased risk for postoperative complications such as vision loss, hyphema, and conjunctiva fibrosis. Glaucoma drainage devices are usually considered the first surgical option for refractory glaucoma. However, NVG patients are at great risk for surgical failure after Ahmed valve surgery, Yalvac reported 63.2 and 56.2 % of success rates at 1 and 2 years after Ahmed valve implantation, respectively [11]. NVG patients also have been associated with high rates of surgical failure after trabeculectomy. Sisto et al. [12] showed 55 % of success rate in a mean follow-up of 35 months with the use of 5-fluorouracil postoperatively and 54 % of success rate in a mean follow-up of 18 months with intraoperative mitomycin C. Transcleral cyclophoto coagulation has been shown to be effective in lowering IOP and relieving pain in advanced NVG [13-15], but with the risk of hypotony and low vision after transcleral cyclophoto coagulation [14-17]. In this case, we provide the new surgery for the treatment of NVG coexisting angle-closure, and the surgery shows a great efficacy of IOP reduction with no surgical complication. The IOP preoperative was 42.5 mmHg with 3 antiglaucoma medications; IOP was 23.5

mmHg 1month postoperative with no antiglauoma medication, 22.5 mmHg 4th months postoperative with no antiglaucoma medication. Her visual acuity recovered 0.2 at 4 month postoperative.

Conclusion

Penetrating canaloplasty was a promising approach in lowering the IOP of angle closure glaucoma secondary to neovascular, with an acceptable low and distinct risk profile owing to the procedure. However, more studies are needed to assess the long term efficacy of such procedure.

Financial Support

This study is funded by Wenzhou Medical University R&D Fund, No. QTJ13009.

References

1. Lewis RA, von Wolff K, Tetz M, Korber N, Kearney JR, Shingleton B, et al. Canaloplasty:circumferential viscodilation and tensioning of Schlemm's canal using a flexible microcatheter for the treatment of open-angle glaucoma in adults: interim clinical study analysis. J Cataract Refract Surg. 2007;33:1217-26.
2. Shingleton B, Tetz M, Korber N. Circumferential viscodilation and tensioning of Schlemm canal (canaloplasty) with temporal clear corneal phacoemulsification cataract surgery for open-angle glaucoma and visually significant cataract: one-year results. J Cataract Refract Surg. 2008;34: 433-40.
3. Lewis RA, von Wolff K, Tetz M, Korber N, Kearney JR, Shingleton B, et al. Canaloplasty:circumferential viscodilation and tensioning of Schlemm canal using a flexible microcatheter for the treatment of open-angle glaucoma in adults: two-year interim clinical study results. J Cataract Refract Surg. 2009;35:814-24.
4. Lewis RA, von Wolff K, Tetz M, Korber N, Kearney JR, Shingleton B, et al. Canaloplasty: Three-year results of circumferential viscodilation and tensioning of Schlemm canal using a microcatheter to treat open-angle glaucoma. J Cataract Refract Surg. 2011;37:682-90.
5. Brusini P. Canaloplasty in open-angle glaucoma surgery: a four-year follow-up. Scientific World Journal. 2014;2014:469609.
6. Tam DY, Barnebey HS, Ahmed II. Nd:YAG laser goniopuncture: indications and procedure. J Glaucoma. 2013;22:620-5.
7. Grieshaber MC. Ab externo Schlemm's canal surgery: viscocanalostomy and canaloplasty. Dev Ophthalmol. 2012;50:109-24.
8. Harvey BJ, Khaimi MA. A review of canaloplasty. Saudi J Ophthalmol. 2011;25:329-36.
9. Shazly TA, Latina MA. Neovascular glaucoma: etiology, diagnosis and prognosis. Semin Ophthalmol. 2009;24:113-21.
10. Hayreh SS. Neovascular glaucoma. Prog Retin Eye Res. 2007;26:470-85.
11. Yalvac IS, Eksioglu U, Satana B, Duman S. Long-term results of Ahmed glaucoma valve and Molteno implant in neovascular glaucoma. Eye (Lond). 2007;21:65-70.
12. Sisto D, Vetrugno M, Trabucco T, Cantatore F, Ruggeri G, Sborgia C. The role of antimetabolites in filtration surgery for neovascular glaucoma: intermediate-term follow-up. Acta Ophthalmol Scand. 2007;85:267-71.
13. Ghosh S, Singh D, Ruddle JB, Shiu M, Coote MA, Crowston JG. Combined diode laser cyclophotocoagulation and intravitreal bevacizumab (Avastin) in neovascular glaucoma. Clin Exp Ophthalmol. 2010;38:353-7.
14. Iliev ME, Gerber S. Long-term outcome of trans-scleral diode laser cyclophotocoagulation in refractory glaucoma. Br J Ophthalmol. 2007;91:1631-5.
15. Murphy CC, Burnett CA, Spry PG, Broadway DC, Diamond JP. A two centre study of the dose-response relation for transscleral diode laser cyclophotocoagulation in refractory glaucoma. Br J Ophthalmol. 2003;87:1252-7.
16. Yildirim N, Yalvac IS, Sahin A, Ozer A, Bozca T. A comparative study between diode laser cyclophotocoagulation and the Ahmed glaucoma valve implant in neovascular glaucoma: a long-term follow-up. J Glaucoma. 2009;18:192-6.
17. Ramli N, Htoon HM, Ho CL, Aung T, Perera S. Risk factors for hypotony after transscleral diode cyclophotocoagulation. J Glaucoma. 2012;21:169-73.