



Massive Preperitoneal Hematoma after Open Hernia Repair with UltraPro Hernia System

Xiaohui Yang*, Shuai Wang and Yi-xiong Zheng

Department of General Surgery, The Fourth Affiliated Hospital Zhejiang University School of Medicine, China

Abstract

Introduction: Inguinal hernia is one of the commonest surgical conditions. Operation is the only effective treatment for hernias. As with other surgical procedures, there are complications with this surgery. Hematoma is one of the well-known complications following hernia repair. But massive preperitoneal hematoma which requires surgical intervention is rare.

Case Report: A 62-year-old male was diagnosed with left inguinal hernia. He underwent an open hernia with UHS and developed a massive preperitoneal hematoma. After surgical intervention, he recovered eventually.

Conclusion: Proper anatomic knowledge and complete bleeding control may avoid post-operation hematoma. And we recommend Lichtenstein technique as the first choice of open hernia repair.

Case Presentation

A 62-year-old male was diagnosed with left inguinal hernia and admitted for left open hernia repair by UltraPro Hernia System (UHS) on March 21st, 2016. He was healthy with no medical problems except smoking history for 30 years. We accomplished an open surgery repair of a moderate-sized left inguinal hernia with UHS under epidural anesthesia on March 22nd. A urethral catheter was placed before surgery. The procedure was smooth and the patient was sent to surgical ward for recovery with a pressure of 1 kg sand bag on his left groin. After 6 h he pulled out the catheter by himself without empty the balloon. The catheter was complete with 10 ml saline in the balloon which was checked by the on-call nurse. Patient explained that he wanted to go outside the hospital for a cigarette with no tube in his body. The next morning he developed a fever about 38.6 degree. Blood test showed hemoglobin was 124 g/L while 141 g/L before surgery. After treated by physical cooling, his temperature became normal. On March 24th morning, he complained a sudden severe pain in the left lower abdomen and got a fever in the afternoon. Hemoglobin was 121 g/L. An emergent CT scan showed a massive preperitoneal hematoma (13.6 cm × 5.5 cm × 6.2 cm) (Figure 1) which originated from Retzius space. Patient's vital sign were stable. We decided conservative treatment that day. On March 25th, Hemoglobin was 98 g/L. We established a surgical exploration. In the surgery, we found bleeding was from corona mortis. We removed the UHS and sutured the artery to stop bleeding. A lichtenstein repair was finished and a tube was placed in retroperitoneal space. Patient's situation was stable after surgery; about 20 ml fluid was drained through the tube. Urethral catheter was pulled by doctor on March 27th. Hemoglobin was 104 g/L on March 28th and CT scan showed no obvious hematoma (Figure 2). He was discharged on March 29th after we removed drainage tube.

Discussion

Open hernia repair techniques could be divided into two major different types according to the placement of mesh. In Lichtenstein repair the mesh is placed anteriorly. However, with UHS, the underlay patch should be placed in preperitoneal space. These two approaches differ not only in anatomic view but also in mechanism, because the preperitoneal mesh placement closes the Fruchaud myopectineal orifice completely, whereas the Lichtenstein operation reinforces the superficial muscle shutter mechanism [1,2]. In this case, we used preperitoneal method. UltraPro Hernia System (UHS; Ethicon) with a partially resorbable layer in the preperitoneal space is a second generation of PHS, which consist of a bilayer polypropylene mesh design and a connector between the layers [3]. The UHS procedure was performed as described by Gilbert et al. [4]. We consider there were vascular injuries by blunt dissection of the preperitoneal space. But the bleeding was not so active that the patient had no symptom at all after the surgery until violent pulling out of

OPEN ACCESS

*Correspondence:

Xiaohui Yang, Department of General Surgery, The Fourth Affiliated Hospital Zhejiang University School of Medicine, Yiwu 322000, China, Tel: (0086)15372968880; Fax: 0086-0579-89935555;

E-mail: ywy2010@zju.edu.cn

Received Date: 26 Nov 2019

Accepted Date: 13 Dec 2019

Published Date: 17 Dec 2019

Citation:

Yang X, Wang S, Zheng Y-X. Massive Preperitoneal Hematoma after Open Hernia Repair with UltraPro Hernia System. *Clin Surg*. 2019; 4: 2682.

Copyright © 2019 Xiaohui Yang. This is an open access article distributed under the Creative Commons Attribution License, which permits unrestricted use, distribution, and reproduction in any medium, provided the original work is properly cited.

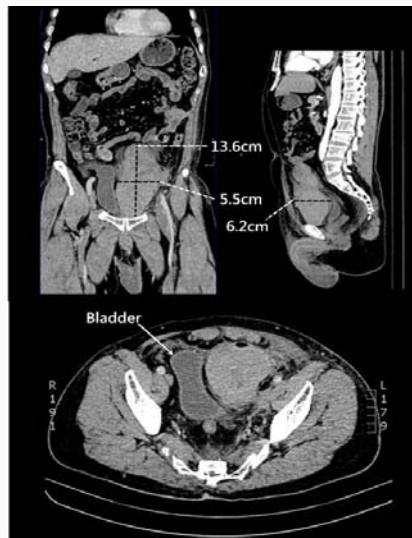


Figure 1: These images show a massive hematoma originates from Retzius space with effect on bladder and bowel loops (Coronal plane, sagittal plane and horizontal plane by CT multiplanar reformation).

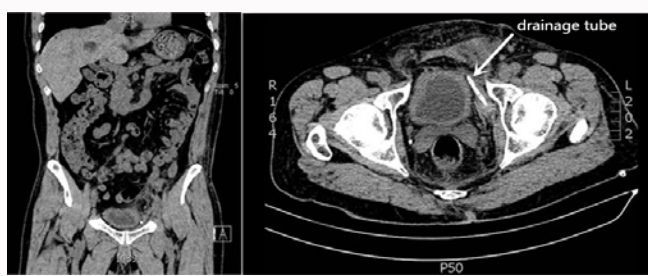

Figure 2: These images show no hematoma after surgical intervention and a tube placed in preperitoneal space (white arrow).

the urethral catheter. We believed that violent drag of bladder induced more rupture of the artery. Compared with Lichtenstein technique, UHS method is a relatively difficult technique for young hernia surgeon. Unlike laparoscopic hernia repair, the blunt dissection of the preperitoneal space in UHS technique is finished under indirect vision which may cause vascular damage. The most commonly known vascular damage are those of the epigastric vessels those of the iliac veins and corona mortis. These damages usually cause a small preperitoneal hematoma which is not required clinical intervention and would be absorbed in 3 to 4 weeks with conservative therapy. In some cases, hematoma may induce infection in long term which may need for drainage or reoperation.

Magnusson J et al. [5] compared Lichtenstein repair, PHS, and UHS in the Karolinska Institute in Sweden. They concluded that the Lichtenstein technique, PHS, and UHS provided similar outcomes regarding perioperative course, complications, recurrence rates,

development of chronic groin pain, and improvement in quality of life after 12 months. However, because of reduced costs and the lack of need for the exploration of the preperitoneal space, the authors stated that the Lichtenstein technique should be recommended as first choice. Karateke et al. [2] reported a study which compared UHS and Lichtenstein technique with 99 male patients with primary unilateral inguinal hernia. 50 patients in Lichtenstein group and 49 patients in UHS group were analyzed for 33 months. There was a prolonged operation time in the UHS group compared with the L group (UHS: 53.7 ± 5.7 min; L: 44.5 ± 5.5 min; $P < 0.001$). The purpose of the case report is to emphasize the meticulous and complete control of bleeding is very important during preperitoneal exploration and dissection. Our experience is using gauze to push out the preperitoneal space softly and electric coagulation hemostasis is also necessary. After enough dissection of the space, you can leave the gauze in the space for a few minutes to apply pressure on some possible or potential bleeding spot. Check the gauze when taken out, if there were obvious blood on the gauze, a careful check of the space should be done. At the same time, we prefer Lichtenstein technique to UHS. If a preperitoneal mesh has to be placed, we recommend TAPP and TEP approach.

Conclusion

We conclude the gentle dissection and careful hemostasis are quite important. Massive hematoma needs surgery intervention immediately. In terms of medical cost and convenience, we consider that Lichtenstein repair should be recommended as the first choice of open hernia repair.

Acknowledgement

This study was supported by Zhejiang Education Research Program (Grant No. Y201737989).

References

1. Moreno-Egea A, Paredes PG, Perello JM, Campillo-Soto A, Baena EG, Muñoz JR, et al. Vascular Injury by Tacks During Totally Extraperitoneal Endoscopic Inguinal Hernioplasty. *Surg Laparosc Endosc Percutan Tech.* 2010;20:e129-31.
2. Karateke F, Ozyazici S, Menekse E, Özdoğan H, Kunt M, Bozkurt H, et al. ULTRAPRO Hernia System Versus Lichtenstein Repair in Treatment of Primary Inguinal Hernias: A Prospective Randomized Controlled Study. *Int Surg.* 2014;99:391-7.
3. Nordin P. Swedish Hernia Register Annual Report. 2011.
4. Gilbert AI, Graham MF, Voigt WJ. A bilayer patch device for inguinal hernia repair. *Hernia.* 1993;3(3):161-6.
5. Magnusson J, Nygren J, Thorell A. Lichtenstein, prolene hernia system, and UltraPro Hernia System for primary inguinal hernia repair: one-year outcome of a prospective randomized controlled trial. *Hernia.* 2012;16(3):277-85.