Clinics in Surgery

Case Report
Published: 30 Apr, 2018

Lobular Capillary Hemangioma of Vocal Cord in an Adult

Burcu Ozturk[1], Fatma Kamile Gunduz[1] and Eren Altun[2]*

[1]Balikesir University School of Medicine, Balikesir/Turkey

[2]Department of Medical Pathology, Balikesir University School of Medicine, Balikesir/Turkey

Abstract

Lobular Capillaries Hemangiomas (LCH) are benign vascular lesions of the skin and mucosal membranes that are common in the head and neck region. Although the etiology is not completely known, factors such as trauma, smoking and abuse of voice are thought to play a role in the emergence of this disease. The localization of these lesions in the vocal cord is rare, which is common in the oral cavity. In this case report, we presented an adult patient with localized LCH in the right vocal cord and discussed the literature (Pubmed, Google Academic, Dergipark) that can be reached between 2003-2017 on LCH.

Keywords: Vocal Cord; Larynx; Lobular Capillaries Hemangioma

Introduction

Lobular Capillary Hemangiomas (LCH) are benign vascular lesions of the skin and mucosal membranes that are common in the head and neck region [1]. The etiology is not fully known but it is thought that factors such as trauma, smoking and vocal abuse play a role in the emergence of this disease [2]. Pyogenic granuloma was first described by Poncet and Dor in 1897 [3].It was previously described as pyogenic granuloma and later described as LCH because it histologically separated from the granulation tissue by the lobular arrangement of capillaries [2,4]. LCHs are benign lesions of the skin and mucous membranes characterized by pedunculated, rapid growth, hyperemia and bleeding [5]. Some etiologic factors are unknown, but some of the factors that have been implicated in the formation of this lesion depending on the region of LCH are: gingival and periodental infections due to poor oral hygiene; prolonged endotracheal intubation and related or other causes of trauma; smoking, gastric reflux, vocal abuse, pregnancy, some drugs [2,5]. The most common localization is oral cavity. Localization of the larynx and vocal cord has been shown in the literature. In this article, a 59 year old male patient with right vocal cord LCH was presented and the literature was discussed.

Case Presentation

59-year-old male patient was admitted to ear, nose and throat polyclinic of Balikesir University Hospital with the complaints of hoarseness and decrease of vocal quality for 2 months. Direct laryngoscopy revealed a 4 × 4 mm granuloma-like tissue in the posterior 1/3 of the right vocal cord. As a result of laryngoscopy, the lesion in the posterior arytenoid region was thought to be a granulation, polyp and mass and it was totally excised together with the stalk. Biopsy material sent to pathology laboratory. Pathological macroscopic examination of the biopsy revealed a smooth surface with grayish white color of 1 × 0.6 cm in size. On the microscopic examination vascular structures, subacute inflammatory cell infiltration and edema were observed under the ulcerated multilamellar epithelium on the surface (Figure 1 and 2). In light of these findings, the lesion on right vocal cord was diagnosed as LCH. After the operation, the patients with stable vitals and good general condition were discharged.

Discussion

LCH is a benign lesion with rapid growth pattern of skin and mucous membranes. These lesions, which are mostly hemorrhagic, often have ulcers on their surface. Hemangiomas are commonly encountered as childhood benign skin lesions. These lesions have spontaneous regrowth teeth period between 18 months and 3 years. Likewise, LCH in pregnancy may regress spontaneously after pregnancy. LCH is most common in infantile, especially in girls and in the subglottic region. Adults are rare but men are more frequent than females. Adult LCH is distinguished from infantile by being cavernous hemangioma and they are usually small lesions [6]. Although endoscopic excision is preferred most frequently in patients with LCH localized in

OPEN ACCESS

***Correspondence:**
Eren Altun, Department of Medical Pathology Balikesir, Balikesir University School of Medicine, Balıkesir, Turkey, E-mail: erenaltun@hotmail.com

Received Date: *10 Apr 2018*
Accepted Date*: 27 Apr 2018*
Published Date*: 30 Apr 2018*

Citation:
Ozturk B, Gunduz FK, Altun E. Lobular Capillary Hemangioma of Vocal Cord in an Adult. Clin Surg. 2018; 3: 1966.

Table 1: Lobular Capillary Hemangioma Case Reports in the Trachea and Larynx.

Author	Age	Male/Female	Location of LCH lesion	Treatment
Acharya	56	Female	2 cm below vocal cords on right tracheal wall	Endoscopic excision and electrocautery
Amy	22	male	3 cm above carina on left posterior tracheal wall	Electrocautery
Our case	59	male	In the posterior third of the right vocal cord	Endoscopic excision
Chawla	62	male	Distal right tracheal wall	Endoscopic excision and laser therapy
Chen	14	Female	Lower third of anterior tracheal wall	Cryotherapy and argon plasma coagulation
Dabó	51	Female	Lower third of left lateral tracheal wall	Endoscopic excision and laser photocoagulation
Durucu	69	male	Left vocal cord and ventricular region	Patient follow-up
Eğilmez	47	male	Left vocal cord	Endoscopic excision,postoperation antibiotic and antireflux
Hoang	11	male	Left wall of subglottic region and left vocal cord	Coblation
Irani	72	Female	3 cm below vocal cords	Endoscopic excision
Jie	35	male	Lateral wall of proximal left main bronchus	Brachytherapy
Kalanjeri	57	male	Posterior middle tracheal wall	Electrocautery
Karlıdağ	56	male	On the free edge of the epiglottis	Endoscopic excision
Madhumita	40	Female	Upper third of right anterolateral tracheal wall	Endoscopic excision
Porfyridis	17	male	Upper third of left anterolateral tracheal wall	Endoscopic excision
Prakesh	23	Female	Posterior tracheal wall	Endoscopic excision with extracorporeal membrane oxygenation
Putora	64	male	Distal tracheal wall	Spontaneous remission on cessation of erlotinib for lung cancer
Qui	39	male	Right intermedius	Endoscopic excision, cryotherapy
Udoji and Bechara	55	male	Distal left lateral tracheal wall	Cryotherapy
Walner	neonatal	Female	Right true vocal cord	Endoscopic excision
Walner	neonatal	Female	Right false vocal cord and ventricle region	Endoscopic excision
Walner	neonatal	male	Midportion of the right true vocal cord and ventricle region	Endoscopic excision
Walner	neonatal	male	Anterior and midportion of the right true vocal cord	Endoscopic excision
Xu	64	male	Left anterolateral tracheal wall	Endoscopic excision
Zambudio	66	Female	Between first and third tracheal rings	Embolization

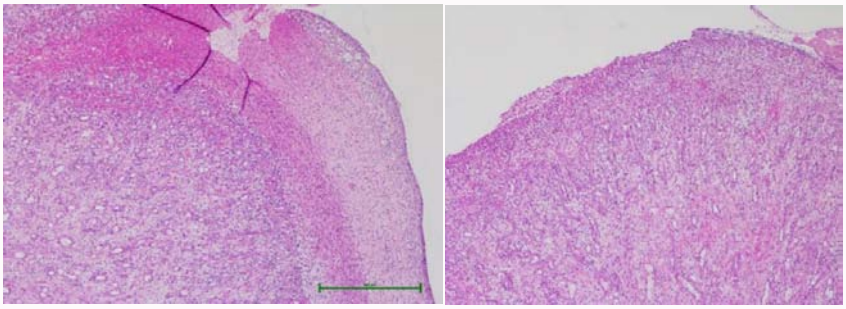

Figure (1 and 2): On the microscopic examination vascular structures, subacute inflammatory cell infiltration and edema were observed under the ulcerated multilamellar epithelium on the surface.

the vocal cord, in addition to surgical treatments such as curettage, cauterization, CO2 laser, tracheostomy; other therapies such as anti-reflux therapy, sound therapy, cryotherapy, argon plasma coagulation are also applied. Depending on the localization, size and prognosis of the lesion, clinical follow-up is recommended besides these treatments [2,3,5]. Clinical manifestations in LCH cases change depending on the location and size of the lesion. Some of these clinical manifestations are; hoarseness, aphonia, decrease of voice quality, dyspnea, wheezing, throat sensitivity, dysphagia, dry cough, stridor, hemoptysis. Adult laryngeal LCH is often caused by aphonia and dyspnea [6]. Hemangiomas, angiofibromas, histiocytoma, hemangioendothelioma, hemangiopericytoma, angiosarcoma, angiomyolipoma, Kaposi's sarcoma, granulomatous infections, hyperplasia, varicosities are considered in the differential diagnosis [2,4,5,7]. Histopathological examination plays a key role in the diagnosis of LCH. However, the region where the lesion is located may bleed in the process of biopsy [8-12]. It is a major complication. Histopathologic and clinical findings should be taking

into consideration for differentiation between hemangioma and LCHs. Histopathologically, this distinction is made by lobular growth patterned vascular proliferation, fibromyxoid stroma, ulceration-based acute inflammation. Again, the absence of histopathologic atypia is a guide for the differentiation of neoplasms [13-18]. The main complaint of the patient in the laryngeal tuberculosis which be considered differential diagnosis of LCH is hoarseness. Histopathological and microbiological examination should be done to distinguish LCH. LCH cases are rare in tracheal and laryngeal regions [19-21]. We found 25 cases in the accessible English and Turkish literature (2003-2017) (Table 1). A 9 of them are vocal cord localized cases. It is consistent with the literature that 9 of the patients are woman and 16 of them are male. Patients are widely distributed between the ages of 72 and neonatal, 4 of 25 cases are neonatal [22]. Except patients who are treated with single or multiple treatments in 1 case, only follow-up of the patient was found appropriate [23]. Endoscopic excisions in 16 of 25 cases brought to our attention.

References

1. Kumar V, Abbas AK, Aster JC, 9.baski. In:Tuzlali S, Gulluoglu M, Cevikbas U. Robbins temel patoloji Istanbul, Nobel tip kitapevleri, 2014.
2. Jafarzadeh H, Sanatkhani M, Mohtasham N. Oral pyogenic granuloma: a review. J Oral Sci. 2006;48(4):167-75.
3. Egilmez O.K, Uzun L, Ozkanli S.S, Kalcioglu M.T. Pyogenic Granuloma of the Larynx: A Case Report. Otolaryngology Online Journal. 2016;6(1):
4. Vinh Ly Pham Hoanga, Nguyen Pham Dinha, Hoang Nguyenb, Joseph P. Kitzmillerb, Linh Bui Doan Haia, et al. Infraglottic lobular capillary hemangioma: A case report. Otolaryngology Case Reports. 2018;6:27-30.
5. Karlidag T, Yalcin S, Yildiz M, Akpolat N. Pyogenic granuloma of the epiglottis: a case report. Turk Arch Otorhinolaryngol. 2007;45(1):41-4.
6. Durucu C , Karataş E , Baglam T , Çevik C , Kanlikama M . Vocal cord hemangioma in an adult. Journal of Clinical and Experimental Investigations. 2011;2(1):91-94.
7. Walner DL, Parker NP, Kim OS, Angeles RM, Stich DD. Lobular capillary hemangioma of the neonatal larynx. Arch Otolaryngol Head Neck Surg. 2008;134(3):272-7.
8. Acharya MN, Kotidis K, Loubani M. Tracheal lobular capillary haemangioma: a rare benign cause of recurrent haemoptysis. Case Rep Surg. 2016;2016:6290424.
9. Amy FT, Enrique DG. Lobular capillary hemangioma in the posterior trachea: a rare cause of hemoptysis. Case Rep. Pulmonol. 2012;2012:592524.
10. Chawla M, Stone C, Simoff M J. Lobular capillary hemangioma of the trachea: the second case. J Bronchol Intervent Pulmonol. 2010;17(3):238-40.
11. Chen E, Yu X, Zhang R, Wang P, Ying, K. A large tracheal capillary hemangioma treated with interventional bronchoscopy. Respir Med CME. 2011;4(2):60-1.
12. Dabo H, Gomes R, Teixeira N, Teixeira G, Fernandes G, Magalhaes A. Tracheal lobular capillary hemangioma treated with laser photocoagulation. J Bras Pneumol. 2016;42(1):72-3.
13. Irani S, Brack T, Pfaltz M, Russi EW. Tracheal lobular capillary hemangioma: a rare cause of recurrent hemoptysis. Chest. 2003;123:2148-49.
14. Jie S, Hong-rui L, Fu-quan Z. Brachytherapy for tracheal lobular capillary haemangioma (LCH). J Thorac Oncol. 2012;7(5):939-40.
15. Kalanjeri S, Kumar A, Mukhopadhyay S, Mehta AC. Lobular capillary hemangioma ("Pyogenic granuloma") of the trachea. Am J Respir Crit Care Med. 2016;193(12):1429-30.
16. Madhumita K, Sreekumar KP, Malini H, Indudharan R. Tracheal haemangioma: case report. J Laryngol Otol. 2004;118(8):655-8.
17. Porfyridis I, Zisis C, Glinos K, Stavrakaki K, Rontogianni D, Zakynthinos S, et al. Recurrent cough and hemoptysis associated with tracheal capillary hemangioma in an adolescent boy: a case report. J Thorac Cardiovasc Surg. 2007;134(5):1366-67.
18. Prakash S, Bihari S, Wiersema U. A rare case of rapidly enlarging tracheal lobular capillary hemangioma presenting as difficult to ventilate acute asthma during pregnancy. BMC Pulm Med. 2014;14:41.
19. Putora PM, Benz G, Rodriguez R, Brutsche M, Fruh M. Tracheal granuloma pyogenicum with erlotinib treatment for lung cancer. Eur Respir J. 2011;38(5):1228-30.
20. Qiu X, Dong Z, Zhang J, Yu J. Lobular capillary hemangioma of the tracheobronchial tree: a case report and literature review. Medicine. 2016;95(48):e5499.
21. Udoji TN, Bechara RI. Pyogenic granuloma of the distal trachea: a case report. J Bronchol Intervent Pulmonol. 2011;18(3):281-84.
22. Xu Q, Yin X, Sutedjo J, Sun J, Jiang L, Lu L. Lobular capillary hemangioma of the trachea. Arch Iran Med 2015;18(2):127-9.
23. Zambudio AR, Calvo MJ, Lanzas JT, Medina JG, Paricio PP. Massive hemoptysis caused by tracheal hemangioma treated with interventional radiology. Ann Thorac Surg. 2003;75(4):1302-4.