Clinics in Surgery

Short Communication
Published: 03 May, 2017

Is Nipple-Sparing Mastectomy without Radiotherapy an Acceptable Alternative to Mastectomy in Patients with Early Breast Cancer from Oncological Perspectives?

Teruhisa Sakurai[1,2] and Takeo Sakurai[2]*

[1]Department of Surgery, Wakayama Medical University Kihoku Hospital, Wakayama, Japan

[2]Department of Surgery, Sakurai Breast Clinic, Japan

Abstract

Nipple-Sparing Mastectomy (NSM) has evolved as an alternative surgical procedure that improves quality of life, including achieving good cosmetic outcomes, in women with breast cancer. We started to perform NSM on patients requiring mastectomy in 1978 with the aim of optimizing cosmetic outcomes. A preliminary investigation established the following early criteria for NSM: T0–T1 (≤2 cm), N0 (no clinical lymph node metastases), and shortest areola–tumor distance >3 cm. Early results were excellent. Our final inclusion criteria for NSM are macroscopic and radiographic intactness of the nipple areola complex. We retrospectively analyzed 723 patients with early stage breast cancer who had undergone NSM from 1985 to 2007, including 93 patients with and 630 without reconstructions. The cohort included 100 patients who had undergone NSM with Modified Radical Mastectomy (MRM) and 259 NSM with Breast Conserving Surgery (BCS) cases. No patients in the NSM and MRM groups received radiotherapy. We compared the Local Recurrence Rate (LRR), Disease-Free Survival (DFS) and Overall Survival (OS) between the NSM, MRM, and BCS groups. There were no significant differences in LRR, DFS, or OS between the NSM, MRM, and BCS groups. There were also no significant differences in LRR, DFS, or OS between patients who had undergone NSM with and without reconstructions. Therefore, we suggest that NSM without radiotherapy is a potential alternative to MRM and BCS in patients with early stage breast cancer from oncological perspectives.

Keywords:Nipple-sparing mastectomy; NSM;Mastectomy;Radiotherapy

OPEN ACCESS

Correspondence:
Teruhisa Sakurai, Department of Surgery, Wakayama Medical University Kihoku Hospital, 279 Myoji, Kasturagicho, Ito, Wakayama,649-7113, Japan, Tel: 81-736-22-0066; Fax: 81-736-22-8223;
E-mail: sakurait@wakayama-med.ac.jp

Received Date: *16 Feb 2017*
Accepted Date*: 27 Apr 2017*
Published Date*: 03 May 2017*

Citation:
Sakurai T, Sakurai T. Is Nipple-Sparing Mastectomy without Radiotherapy an Acceptable Alternative to Mastectomy in Patients with Early Breast Cancer from Oncological Perspectives?. Clin Surg. 2017; 2: 1457.

Introduction

A good cosmetic outcome is an important goal of surgery for breast cancer. Most patients who are ineligible for breast-conserving surgery undergo Modified Radical Mastectomy (MRM). Standard mastectomy includes removal of the Nipple-Areola Complex (NAC); however, the necessity for this when the cancer does not involve the complex has been questioned. Therefore, to optimize cosmetic outcomes in patients requiring mastectomy who have no evidence of malignancy in the NAC, we started to perform Nipple-Sparing Mastectomy (NSM) in 1978[1].

Patients and Methods

Because there were no guidelines on indications for NSM in 1978, a study to determine such indications was needed. In such a preliminary study, we investigated histological evidence of cancer involvement of the NAC in serial 5 mm thick sections of the NAC taken from operative specimens after mastectomy for breast cancer (Figure 1). To determine when it was safe to perform NSM and preserve the NAC, we also measured the shortest areola–tumor distance and tumor size in each specimen. When we correlated the shortest areola–tumor distance and histological evidence of cancer involvement of the NAC, we found that the rate of cancer involvement was low when the shortest areola–tumor distance was >2 cm (Figure 2). Further, examination of the correlation between tumor size and cancer involvement of the NAC showed that the rate of cancer involvement was low when the tumor was smaller than 2 cm in diameter (Figure 3). Initially, we performed NSM on women who wanted to preserve the NAC and met our early criteria and MRM on those who believed the risks of recurrence in the NAC outweighed the benefits of NSM. Based on our preliminary data, we established the following early criteria for NSM: T0–T1 (≤2 cm), N0 (no clinical lymph node metastases), and shortest areola–tumor distance >3 cm. We fortunately

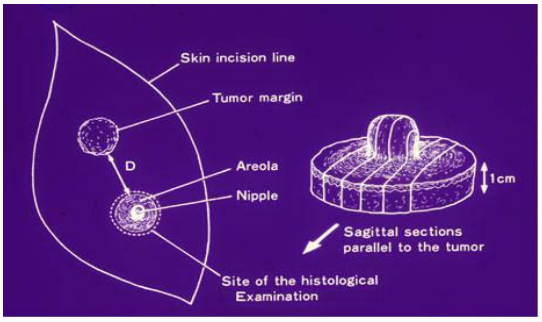

Figure 1: Preliminary histological investigation of cancer involvement to the NAC using resected standard mastectomy specimens for breast cancer.

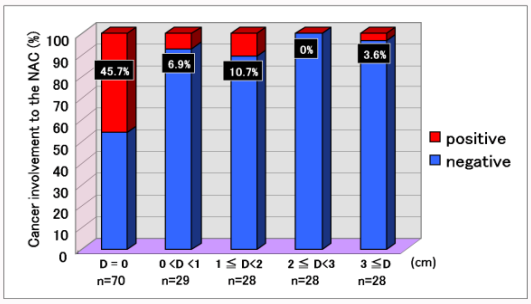

Figure 2: Correlation between areola-tumor nearest distance (D) and the cancer involvement to the nipple-areola complex (NAC) from removed mastectomy specimens.

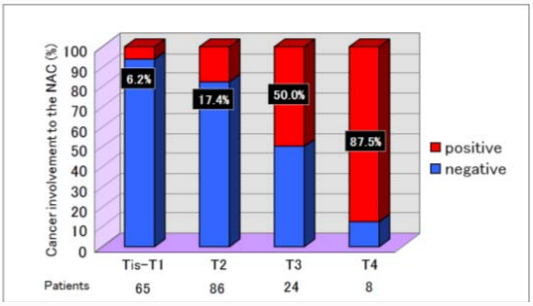

Figure 3: Correlation between tumor size and cancer involvement to the nipple-areola complex (NAC) from removed mastectomy specimens.

obtained excellent outcomes from our early surgeries (data not shown) and subsequently progressively amended and expanded the criteria. The final inclusion criteria for NSM were macroscopic and radiographic intactness of the NAC according to ultrasonography, computed tomography, and magnetic resonance imaging. Little was known about the comparative long-term outcomes of NSM, MRM and Breast Conserving Surgery (BCS) in patients with early stage breast cancer. We therefore retrospectively analyzed 723 patients with early stage breast cancer who had undergone NSM from 1985 to 2007, including 93 patients with and 630 without reconstructions. We also analyzed NSM with 100 MRM and 259 Breast Conserving Surgery (BCS) cases. The procedure of NSM was already reported[1]. None of the patients who had undergone NSM or MRM had received radiotherapy, whereas 3.4% (9/259) of patients who had undergone BCS had received radiotherapy. No patients in this cohort had received neoadjuvant chemotherapy; however, all had received postoperative chemotherapy and hormone therapy based on standard care. We compared the Local Recurrence Rate (LRR),

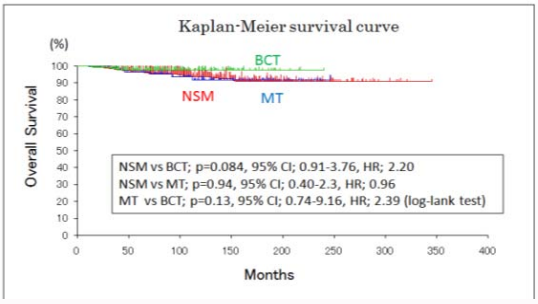

Figure 4: Overall survival.

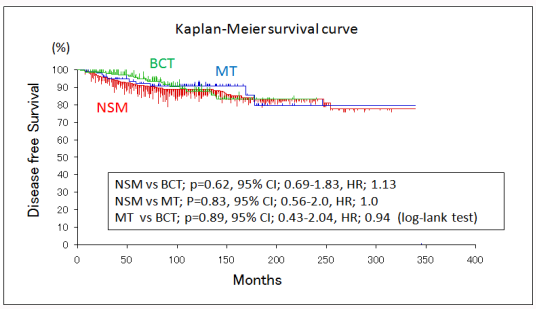

Figure 5: Disease free survival.

Table 1: NSMs had been performed on patients.

Stage	NSM(pts)	MRM(pts)	BCS(pts)
0	21	6	13
1	320	52	162
2A	253	16	64
2B	129	26	20
total	723	100	259
Radiotherapy	none	none	9 (3.4%)

Disease-Free Survival (DFS) and Overall Survival (OS) between the NSM, MRM, and BCS groups. All events and the date of last contact were calculated from the date of surgery. Data were analyzed using Statflex software, version 6.0 (Artech, Japan). Pvalues < 0.05 were considered to be denoting statistical significance.

Results

Twenty-one, 320, 253, and 129 NSMs had been performed on patients with Stage 0, 1, 2A, and 2B disease, respectively, 6, 52, 16, and 26 MRMs, respectively, and 13, 162, 64, and 20 BCS, respectively (Table 1). During 114 months of follow-up, no nipple necrosis was recorded in any patient. Of the patients who had undergone NSM, 49 (6.7%) had developed local recurrence, 24 (3.3%) at the nipple and 25 (3.4%) in the skin flap, without distant metastases. There were no significant differences in LRR between the NSM, MRM and BCS groups (6.7% vs. 4.0% vs. 4.2%, respectively, p=0.23), 10 year DFS (88% vs. 90% vs. 87%, respectively, Figure 4) and 10 year OS (92% vs. 91% vs. 87%, respectively, Figure 5). There were also no significant differences in LRR between patients with and without reconstructions (7.5% vs. 6.5%, p=0.75), 10 year DFS (91% vs. 88%, p=0.40) and 10 year OS (95% vs. 92%, p=0.36), respectively. Of the 25 patients with skin flap recurrence, 22 had a solitary site of recurrence and three diffuse recurrence. The patients with diffuse recurrence had significantly worse overall survival than those with a solitary site

of recurrence (p=0.01). Overall survival of 24 patients with nipple recurrence correlated well with that of patients with a solitary site of skin flap recurrences (p=0.5).

Discussion

Recent data have suggested that NSM is oncologically safe and the LRR and prognosis, including DFS and OS, are comparable for NSM and MRM[2-5]. The present long-term follow-up data suggest that NSM is as technically and oncologically safe as MRM and BCS and that NSM is equally oncologically safe in patients with or without reconstruction. Therefore, we consider NSM an alternative to MRM in patients with early stage breast cancer who do not undergo radiotherapy. However, a large, prospective, randomized trial is needed to confirm the technical and oncological safety of NSM in such patients.

References

1. Sakurai T, Zhang N, Suzuma T, Umemura T, Yoshimura G, Sakurai T, et al. Long-term follow-up of nipple-sparing mastectomy without radiotherapy: a single center study at a Japanese institution. Med Oncol. 2013;30(1):481.
2. De La Cruz L, Moody AM, Tappy EE, Blankenship SA, Hecht EM. Overall Survival, Disease-Free Survival, Local Recurrence, and Nipple-Areolar Recurrence in the Setting of Nipple-Sparing Mastectomy: A Meta-Analysis and Systematic Review. Ann Surg Oncol. 2015;22(10):3241-9.
3. Zhang H, Li Y, Moran MS, Haffty BG, Yang Q. Predictive factors of nipple involvement in breast cancer: a systematic review and meta-analysis. Breast Cancer Res Treat. 2015;151(2):239-49.
4. Shimo A, Tsugawa K, Tsuchiya S, Yoshie R, Tsuchiya K, Uejima T, et al. Oncologic outcomes and technical considerations of nipple-sparing mastectomies in breast cancer: experience of 425 cases from a single institution. Breast Cancer. 2016;23(6):851-860.
5. Adam H, Bygdeson M, de Boniface J. The oncological safety of nipple-sparing mastectomy - a Swedish matched cohort study. Eur J Surg Oncol. 2014;40(10):1209-15.