Clinics in Surgery

Research Article
Published: 21 Apr, 2022

Interdisciplinary Orthodontic-Surgical-Prosthetic Approach in the Treatment of Permanent Central Incisor Agenesis: A Case Report

Calabrò PPF[1], Caruso Sara[2], Caruso Silvia[2], Prata Paolo[1] and Gatto Roberto[2]*

[1]*Private Practice in Dentistry, 03100 Frosinone, Italy*

[2]*Department of Life, Health and Environmental Sciences, University of L'Aquila, Italy*

Abstract

This case report describes a combined multidisciplinary orthodontic-surgical-prosthetic treatment in a growing patient who presented the agenesis of element 1.1. Dental agenesis or hypodontia is one of the most common developmental anomalies of human dentition; its etiology remains unclear, although most cases involve an autosomal dominant genetic inheritance. Cases of agenesis of the permanent maxillary central incisor, however, are very rare, about 0.01%, and in the literature, it is called "solitary median maxillary central incisor", therefore requires correct multidisciplinary planning, and in this work, we will focus on the correct orthodontic-surgical and prosthetic approach. In this case report, our focus will be on the surgical-prosthetic aspect. The patient comes to observation at the age of 10 for problems initially of an orthodontic type and dental malposition. The patient's treatment plan initially involved rapid expansion of the palate, followed by orthodontic therapy for at least two years, planned avulsions of the deciduous teeth, and the placement of a temporary Maryland bridge. The right therapeutic timing was thus expected (to achieve somatic development) before performing the split crest to make up for the lack of bone thickness with contextual insertion of a Sweden & Martina Prama® Implant for resolution of agenesis of 1.1. Thanks to the right orthodontic approach, we were able to obtain the right space not only mesio-distal but also vestibule-oral as being a genetic it was obviously insufficient. For aesthetic reasons, the shape of the contralateral was corrected with a direct composite restoration. The therapeutic approach chosen allowed us to correct the malocclusion by respecting the correct position of the dental elements, to safeguard the spaces in the arch pending complete exchange and to keep the patient's bone intact for the placement of the implants. All this ensuring an excellent aesthetic result and facial and smile symmetry. Interdisciplinary planning combining orthodontics and esthetic dentistry was key in resolving this case.

Keywords: Tooth agenesis; Upper incisors; Orthodontic treatment

OPEN ACCESS

Correspondence:
Sara Caruso, Department of Life, Health and Environmental Sciences, University of L'Aquila, 67100 L'Aquila, Italy,
E-mail: saracaruso2704@gmail.com

Received Date: *01 Mar 2022*
Accepted Date*: 08 Apr 2022*
Published Date*: 21 Apr 2022*

Citation:
Calabrò PPF, Caruso S, Caruso S, Prata P, Gatto R. Interdisciplinary Orthodontic-Surgical-Prosthetic Approach in the Treatment of Permanent Central Incisor Agenesis: A Case Report. Clin Surg. 2022; 7: 3492.

Introduction

The patient A.F. comes to our observation at the age of 10 for orthodontic problems, and dental malposition due to the lack of the a genetic element 1.1. By agenesis we mean a dental anomaly in number, characterized by the lack of formation of one or more deciduous or permanent dental elements. Agenesis is therefore the phenotypic expression of a pathogenic Noxa that affects the early stages of dental development. Agenesis plays a role of great interest both because they are the most frequently encountered dental anomalies, and because they confront us with complex individual therapeutic problems [1]. Agenesis can be an anomaly in its own right, or be a phenotypic expression in syndromes more complex, characterized by a precise symptomatological and genetic makeup: it was, in fact, treated in 49 syndromes or systemic conditions, the best known of which are ectodermal dysplasia, Down syndrome, Ellis Van Crevald syndrome and cleft lip and palate [2]. In the specific case, agenesis of the central incisor is very rare and it is important to make a differential diagnosis with SMMCI syndrome, a potentially serious condition [3]. According to the meta-analysis of Polder et al. [4], in fact, the prevalence of agenesis of the maxillary lateral incisors is approximately 1.8% while of the maxillary central incisors is around 0.01% and considered rare by the authors. In this study we report a clinical case of a patient who was treated with an interdisciplinary approach. He was first subjected to orthodontic treatment to align and establish the right occlusal contacts both skeletal and dental and subsequently rehabilitated through the insertion of the implant and

fixed prosthesis, respecting the right therapeutic growth timing and leading to a clear improvement of the facial profile and of the aesthetics of the smile.

Materials and Methods

The patient who came to our observation is female and 10 years old. She presented in mixed dentition, second-class skeletal (ANB=4.8), in the first molar class on the right and contraction of the transverse diameter of the upper jaw. On the left, the presence of embedded elements made it difficult to determine the dental class. The treatment began in 2009 with the collection of initial records, the cephalometry and the study of the Orthopantomography (OPT) (Figures 1-16). After 12 months we started the orthodontic treatment. On 29-X-2009 a Rapid Palate Expander (REP) was cemented to correct the transverse skeletal deficit of the growing maxilla, which was activated for 15 days and then blocked the expansion screw. After 9 months from the end of the activation of the REP, the patient began fixed multibracket orthodontic therapy in the upper and lower arch for a total duration of two years until a correct occlusal molar class was achieved. The brackets used were self-ligating with the MBT prescription. During the orthodontic phase of the treatment, serial extractions of the deciduous elements programmed in the treatment plan were carried out and an opercolarization of 3.6 was performed to engage the crown and to do the element up righting. In 2018, an impression was taken for a temporary Maryland bridge which it was decided to make in lithium disilicate to ensure aesthetics for the

Figure 1: Rx/orthopantomography initial.

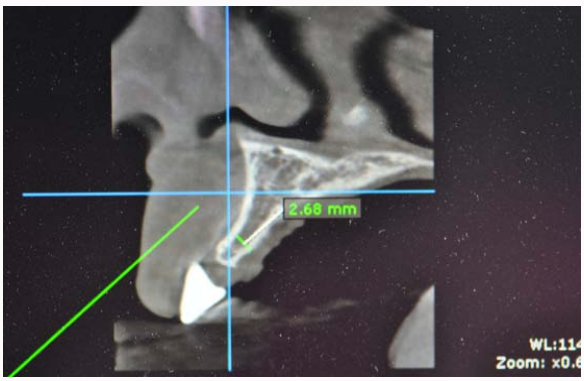

Figure 2: Initial CT scan where the lack of bone thickness is evident to make implants.

Figure 3: Pin to control the parallelism of the implant insertion axis. (09-VII-2018).

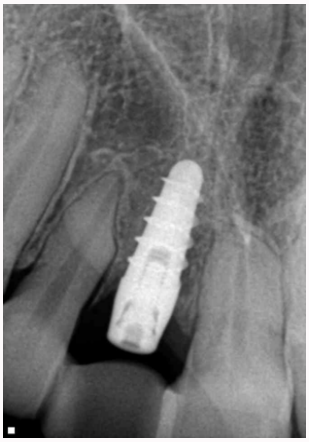

Figure 4: Postoperative radiography of the insertion of the **Sweden & Martina Prama® implant** on 9-VII-2018.

Figure 5: Photo intra-orale after insertion of the **Sweden & Martina Prama® implant** on 09-VII-2018.
The operation was performed without removing the maryland bridge which served as a guide for the positioning of the implant and without making release incisions in the vestibular part but simply by extending, always in partial thickness, the incisions up to the two contiguous teeth, both mesial than distal.

Figure 6: In January 2019, still not satisfied with the aesthetic result to remedy the lack of the vestibular gingival bombè, a connective graft was performed with removal from the palate with the trap door technique, in partial thickness (09-VII-2018).

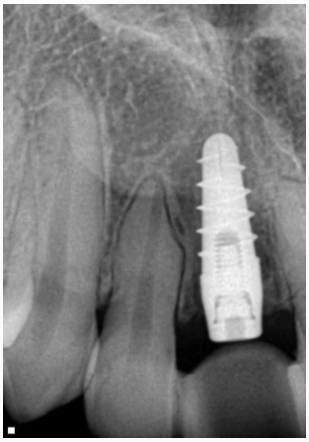

Figure 7: Rx control.

Figure 8: The patient after having the graft to remove the stitches.

Figure 9: 14-I-2019.

Figure 10: 15 days after grafting (24-I-2019).

patient on the site of the upper central incisor of the right a genetic. In July 2018, at the end of the nineteenth year of age, after bone growth and after careful examination of the CBCT, she underwent a split crest operation at the 1.1 site level with contextual insertion

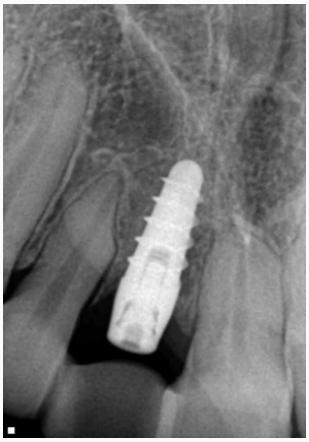

Figure 11: In April 2019 the Maryland bridge was removed, an optical impression was taken to receive the abutment and the customized provisional from the milling center.

Figure 12: In May 2019 the definitive abutment was screwed with subsequent taking of the position impression for the definitive metal-ceramic crown cemented in July 2019. Checks and follow up with dates in the images below.

Figure 13: Element 1.1 in this image presented mucositis caused by the patient's poor degree of oral hygiene that we were unable to further motivate and subsequently resolved with professional hygiene and gingival curettage.

of the 3.8 mm × 10 mm Sweden & Martina Prama® implant. The Sweden & Martina Prama® implant was chosen for the well-known characteristics of its implant neck, which make it possible to obtain a natural gingival scallop thanks to the particular design of micro coils that allow the myofribroblasts of the gingival connective to adhere intimately to the neck of the same.

Discussion

Dental agenesis has a major functional and esthetic impact, exacerbated by the number of teeth involved. The consequences of agenesis can include the emergence of diastemas, infraocclusion of deciduous teeth, inadequate angulations of adjacent teeth, occlusal trauma, among others. The planning of these cases is invariably

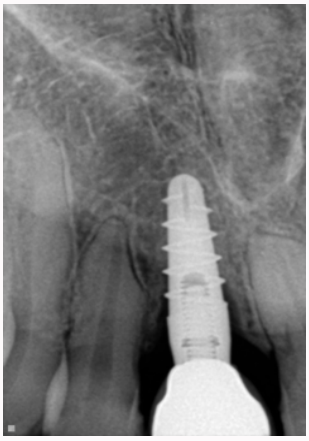

Figure 14: Control radiography after two years (19-II-2021).

Figure 15: Control photos after two years (19-II-2021).

Figure 16: Follow up after two years (19-II-2021).

interdisciplinary, where the main doubt in treating dental agenesis cases typically hinges on the dilemma of space closure or space opening for prosthetic rehabilitation [5-18]. In the literature, in fact, there are four ways to make up for the lack of bone thickness: Prosthetic rehabilitation, bone grafting, bone regeneration through membranes or bone regeneration through split-crest. The closure or opening of spaces in agenesis cases depends on the space discrepancy in the arch, type of facial profile, presence of maxillary dental protrusion or retrusion, type of malocclusion, agenesis symmetry and size and shape of teeth to be moved. Another challenge is the need to carry out treatment in patients that are still growing, where early diagnosis at around 7 to 9 years favors treatment outcome because teeth can be moved so as to minimize potential functional and esthetic compromise, conferring better quality of life for the child. The current prosthetic solution of choice for agenesis cases, and considered a more conservative approach, is implant-supported prosthesis, although this treatment is not always possible. Factors such as age, bone quantity and quality as well as space availability can preclude placement of this type of implant. There is a consensus that, in young patients, implants and their prosthesis should only be fabricated after growth is fully complete. Some studies show that, even after complete dental and skeletal development, infraocclusion and progressive malalignment in crowns can occur in the anterior region of the maxilla. We have opted for the future solution of the missing element through implantology as a resolving technique to avoid possible functional problems in, to improve the smile display and to satisfy the wishes of the parents avoiding extensive prosthetic artifacts. The choice of the Sweden & Martina Prama® implant. as the implant of choice is due to its particular shape of the neck both at the macroscopic level because the neck was built according to the dictates of the BOPT, and at the microscopic level thanks to the coils to facilitate the growth and stabilization of the connective. Thanks to the innovation of Sweden and Martina with the Sweden & Martina Prama® implant the UTM surface is born. The UTM (Ultrathin Threaded Microsurface) surface with its roughness of 60 microns has been specially designed to be an excellent substrate for both soft and hard tissues. It is not a machined surface, but it is an ad hoc micro-threading to enhance cellular organization, exploiting the principle of contact guidance, according to which cells are led to arrange themselves and move following the surrounding geometric stimuli. The fibroblasts are then guided in this one-way environment, as if they are in a rail, where they can only stretch and contract. The controlled and guided movement allows the cells to position themselves correctly in the microspire, spending little of their energy, which therefore remains available for what is the ultimate destiny of each cell: To duplicate itself. According to what is present in the literature, the correct timing of 6 to 9 months of healing from the split-crest and contextual positioning of the implant was respected before it was functionalized.

Conclusion

This case report illustrates the success of interdisciplinary treatment, which combines orthodontics, prosthetics and surgery to solve the problem caused by the agenesis of the maxillary central incisor. The success of the treatment is also due to modern surgical innovations as well as to correct planning. The implantology of the future will be this: The modulation of biological signals that control cell differentiation in a harmonious way and

biomimetic. It is a challenge that starts from afar, from patient research and analysis of cellular responses *in vitro* and *in vivo*. It is a long road, where every improvement that comes to the clinic hides a history of attempts, failures, frustrations, but also of enthusiasm, inspiration and discoveries. It is a path that requires the contribution of everyone, basic researchers, clinicians, and users. It is a challenging journey, but it is a journey that is changing the way of doing dentistry.

References

1. Salvadori S, Viganò VM, Pitto I, Maspero C, Farronato G. Congenitally missing teeth: Prevalence and incidence.
2. Fekonja A. Hypodontia in orthodontically treated children. Eur J Orthod. 2005;27(5):457-60.
3. Polder BJ, Van't Hof MA, Van der Linden FP, Kuijpers-Jagtman AM. A meta-analysis of the prevalence of dental agenesis of permanent teeth. Community Dent Oral Epidemiol. 2004;32:217-26.
4. Larmour CJ, Mossey PA, Thind BS, Forgie AH, Stirrups DR. Hypodontia--a retrospective review of prevalence and etiology. Part I. Quintessence Int. 2005;36:263-70.
5. Vahid-Dastjerdi E, Borzabadi-Farahani A, Mahdian M, Amini N. Non-syndromic hypodontia in an Iranian orthodontic population. J Oral Sci. 2010;52:455-61.

6. Bolan M, Derech CD, Correa M, Ribeiro GL, Almeida IC. Palatal expansion in a patient with solitary median maxillary central incisor syndrome. Am J Orthod Dentofacial Orthop. 2010;138:493-7.

7. Chandrasekaran D, Yezdani A, Tajir F, Saravanan B, Rajasekar L. Solitary median maxillary central incisor: A case report of a rare dental anomaly. J Pharm Bioallied Sci. 2015;7:S307-8.

8. Rosa M, Zachrisson BU. Integrating space closure and esthetic dentistry in patients with missing maxillary lateral incisors. J Clin Orthod. 2007;41:563-73.

9. Behr M, Driemel O, Mertins V, Gerlach T, Kolbeck C, Rohr N. Concepts for the treatment of adolescent patients with missing permanent teeth. Oral Maxillofac Surg. 2008;12:49-60.

10. Behr M, Proff P, Leitzmann M, Pretzel M, Handel G, Schmalz G. Survey of congenitally missing teeth in orthodontic patients in Eastern Bavaria. Eur J Orthod. 2011;33:32-6.

11. Kinzer GA, Kokich VO Jr. Managing congenitally missing lateral incisors. Part III: Single-tooth implants. J Esthet Restor Dent. 2005;17:202-10.

12. Iseri H, Solow B. Continued eruption of maxillary incisors and first molars in girls from 9 to 25 years, studied by the implant method. Eur J Orthod. 1996;18:245-56.

13. Thilander B, Odman J, Jemt T. Single implants in the upper incisor region and their relationship to the adjacent teeth. An 8-year follow-up study. Clin Oral Implants Res. 1999;10:346-55.

14. Bergendal B. When should we extract deciduous teeth and place implants in young individuals with tooth agenesis? J Oral Rehabil. 2008;35:55-63.

15. Waechter J, Leite FR, Nascimento GG, Carmo Filho LC, Faot F. The split crest technique and dental implants: A systematic review and meta-analysis. Int J Oral Maxillofac Surg. 2017;46(1):116-28.

16. Ceruso FM, Ottria L, Martelli M, Gargari M, Barlattani A Jr. Transgingival implants with a convergent collar (PRAMA); surgical and screwed prosthetic approach. A case report. J Biol Regul Homeost Agents. 2020;34(1):71-7.

17. Guerra D, Severino M, Caruso S, Rastelli S, Gatto R. The importance of using physical tridimensional models for the management and planning of extended osseous odontogenic lesions. Dent J (Basel). 2021;9(11):134.

18. Caruso S, Nota A, Caruso S, Severino M, Gatto R, Meuli S, et al. Mandibular advancement with clear aligners in the treatment of skeletal Class II. A retrospective controlled study. Eur J Paediatr Dent. 2021;22(1):26-30.