Clinics in Surgery

Case Report
Published: 08 Oct, 2021

Idiopathic Rigid Clubfoot with Midfoot Abductus

Pablo Jesús Mateos Fernández*, Juan Antonio Constantino Cabrera and Carlos Quiles Casas

Orthopedic Surgery and Traumatology Service, Complejo Hospitalario Universitario de Badajoz, Spain

Abstract

We report a rare case of a newborn patient with severe, rigid, bilateral idiopathic clubfeet with midfoot abductus, successfully corrected through á la carte complete circumferential release with peroneus brevis and abductor digiti minimi muscles lengthening. To our knowledge, this deformity patterns has not been described in idiopathic clubfoot. The patient achieved satisfactory functional and cosmetic outcomes at two-year follow-up.

Introduction

Clubfoot, also called congenital idiopathic talipes equinovarus, is a structural deformity of the foot that is present at birth with a prevalence of 1 to 5 per 1000 live births [1-3]. The deformity of clubfoot consists of equinus and varus of the hindfoot and adductus and varus of the midfoot affecting tridimensionally [1,2]. There are abnormalities described in almost every tissue of the foot, including muscles, ligaments, tendons and skeletal elements. Although clubfoot etiology is unknown, several studies prove that both genetic and environmental components are involved. Casting and periodic manipulations (Ponseti method) is used as initial treatment. However, sometimes surgical correction is required [1,4,5].

Case Presentation

A 32-year-old woman gave birth to a male at 37+5 weeks' gestation by eutocic delivery and cephalic presentation without complications. The obstetric history included the pregnancy always controlled and all the prenatal ultrasounds did not have incidents. Parental antecedents were unremarkable, except that both had hypothyroidism treated with Eutirox®. Older brother was healthy. The birth weight was 2990 g and Apgar 10/10. Neonatology service consulted for a newborn child with bilateral deformity of the feet. The initial evaluation revealed a child with bilateral deformity of the feet, with a dorsal crease at the ankle and another plantar and external crease at the midfoot; with equinus and varus deformity of the hindfoot and midfoot abductus (Figure 1). The rest of the evaluation was normal: Bilateral health hips (Ortolani, Barlow and Klisic test negative, with complete and symmetrical movements), with no other limbs deformities. We ordered a Genetic Evaluation because of the deformity of the feet. The results of the study revealed three Copy Number Variations (CNVs) instead of two at 4p15.33 and in Xp22.33/Yp11.32 chromosome; classified as benign or with uncertain clinical significance of CNVs comparing with databases Clin Gen and Genomics Variants. Pediatric Genetic Unit concluded that patient phenotype was not significant except for the feet deformity.

Figure 1: Neonatal picture showing clinical deformity.

OPEN ACCESS

****Correspondence:***
Pablo Jesús Mateos Fernández, Orthopedic Surgery and Traumatology Service, Complejo Hospitalario Universitario de Badajoz, Badajoz, Spain,
E-mail: pjmateosf@gmail.com

Received Date: *30 Aug 2021*
Accepted Date*: 05 Oct 2021*
Published Date*: 08 Oct 2021*

Citation:
Mateos PJ, Cabrera JA, Quiles C. Idiopathic Rigid Clubfoot with Midfoot Abductus. Clin Surg. 2021; 6: 3327.

Figure 2: (A: anterolateral view of the right foot. B: anterolateral view of the left foot. C: posteromedial view of both clubfeet).

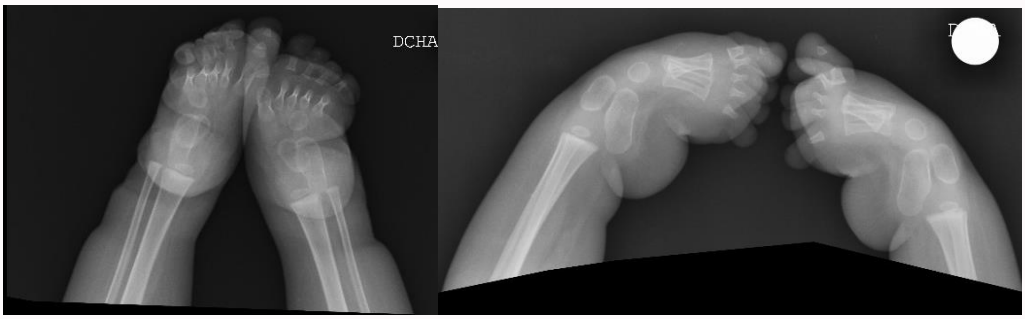

Figure 3: (A and B: preoperatory Rx, AP view and lateral).

Figure 4: A and B: images of right foot. C and D: images of left foot. E: image of both feet.

Three months later, at our Pediatric Orthopaedic Unit, we reexplored the patient finding that the congenital idiopathic talipes equinovarus with the midfoot abductus was rigid (Figure 2), so we decided to correct the deformity surgically when he was 10 months old. Preoperatory radiographs (Figure 3) showed bilateral clubfeet with midfoot abducted.

Patient was diagnosed as having a severe equinocavovarus foot with abductus midfoot and reconstructive surgery was planned. We opted to use and à la carte complete circumferential release (posterior and medial release of subtalar joint capsule, posterior release of talocrural joint capsule, peroneus brevis muscles release, Z-tenotomy of flexor digitorum longus muscle and release of the plantar fascia) with Achilles tendon and Z-plasty over external crease and abductor digiti minimi muscles lengthening of both feet. We maintained correction with K-wires from calcaneus to tibia and from 1º metatarsal bone to talus during 6 weeks with optimal clinical results (Figure 4). Once correction was obtained, we use an AFO to supply the maintenance of the surgical correction.

Figure 5: Right foot (A) and left foot (B) corrected after 6 weeks postoperatively.

At the most recent postoperative evaluation, 6 months after the surgery (Figure 5), the patient was able to stand up and take first steps following the normal child development stages. At 2 years follow-up, the 3-year-old patient presented a slight progression of the equinus and varus from both feet which did not interfere with the gait or with his daily activities (Figure 6). The boy continued being followed up every 3 months and persisted with physioteraphic therapy in order to stop progression.

Results and Discussion

Clubfeet or congenital idiopathic talipes equinovarus is a deformity of the feet which consist on an equinocavovarus of the hindfoot with the adducted midfoot [1]. We present a case of a patient who was born with severe rigid congenital bilateral clubfoot with the exception that the midfoot was abductus. The genetic evaluation revealed that there were CNVs classified as benign or with uncertain clinical significance. The patient was diagnosed as idiopathic rigid clubfoot with midfoot abductus. To our knowledge this clubfoot variant has never been reported in medical literature.

Historically, extensive soft tissue releases to treat clubfoot have been performed in infants often age 3 to 6 months with various approaches and techniques [2]. The complications met during or after surgery, such as scarring, stiff residual clubfoot failed correction, wound breakdown, skin necrosis and overcorrection, and the disappointing long-term outcomes resulted in a turn toward a less invasive method the Ponseti technique [7-11].

However, there are particular cases neglected, previously operated, or syndromic cases that cannot be managed sufficiently with the Ponseti method. Those cases are usually feet after previous extensive surgery, severe stiff recurrences owing to lack of follow-up, non-idiopathic clubfoot, and stiff residual clubfoot components in children and young adult [4].

In our case, owing an unusual clinical picture, we decided to perform surgical correction with a circumferential to the release card and lengthening of peroneus brevis and the abductor digiti minimi muscles. Our reconstructive goals included unimpeded weight-bearing ambulation and shoe wear, with a reasonable aesthetic appearance. Satisfactory corrections were successfully achieved and maintained stable six months after surgery. Despite this correction, these clinical results will be deteriorated in a long-term follow-up since in idiopathic clubfoot the majority of relapses occur in the first 2 to 3 years of life and rarely after the age of 5 [12,13]. After 2 years from surgical repair, the functional outcome was satisfactory although a slight progression of the equinovarus appeared which did not interfere with the normal development of the patient.

Figure 6: Slight progression of equinus and varus deformity after 2 years postoperatively.

Conclusion

In conclusion, we believe that the patient described in this report displayed a rare case of idiopathic clubfoot with midfoot abductus. In short-term follow up satisfactory functional, as well as aesthetic, results was achieved with extensive soft tissue releases.

References

1. Gibbons PJ, Gray K. Update on clubfoot. J Paediatr Child Health. 2013;49(9):E434-7.
2. Bridgens J, Kiely N. Current management of clubfoot (congenital talipes equinovarus). BMJ. 2010;340:c355.
3. El Batti S, Solla F, Clément J-L, Rosello O, Oborocianu I, Chau E, et al. Initial treatment of congenital idiopathic clubfoot: Prognostic factors. Orthop Traumatol Surg Res. 2016;102(8):1081-5.
4. Radler C, Mindler GT. Treatment of severe recurrent clubfoot. Foot Ankle Clin. 2015;20(4):563-86.
5. Zhao D, Li H, Zhao L, Liu J, Wu Z, Jin F. Results of clubfoot management using the Ponseti method: Do the details matter? A Systematic review. Clin Orthop Relat Res. 2014;472(4):1329-36.
6. Turco VJ. Surgical correction of the resistant clubfoot. One-stage posteromedial release with internal fixation: A preliminary report. J Bone Joint Surg Am. 1971;53(3):477-97.
7. Aronson J, Puskarich CL. Deformity and disability from treated clubfoot. J Pediatr Orthop. 1990;10(1):109-19.
8. Dobbs MB, Nunley R, Schoenecker PL. Long-term follow-up of patients

with clubfeet treated with extensive soft-tissue release. J Bone Joint Surg Am. 2006;88(5):986-96.

9. Green AD, Lloyd-Roberts GC. The results of early posterior release in resistant club feet. A long-term review. J Bone Joint Surg Br. 1985;67(4):588-93.

10. Morcuende JA, Dolan LA, Dietz FR, Ponseti IV. Radical reduction in the rate of extensive corrective surgery for clubfoot using the Ponseti method. Pediatrics. 2004;113(2):376-80.

11. Ponseti IV, Smoley EN. The classic: Congenital club foot: The results of treatment.1963. Clin Orthop Relat Res. 2009;467(5):1133-45.

12. Dietz F R. Treatment of a recurrent clubfoot deformity after initial correction with the Ponseti technique. Instr Course Lect. 2006;55:625-9.

13. Ponseti IV, Zhivkov M, Davis N, Sinclair M, Dobbs MB, Morcuende JA. Treatment of the complex idiopathic clubfoot. Clin Orthop Relat Res. 2006;451:171-6.