Clinics in Surgery

Research Article
Published: 21 Aug, 2017

Giant Spinal Schwannomas

Ahmet Öğrenci[1], Orkun Koban[1], Salim Şentürk[2], Onur Yaman[2], Mehdi Sasani[2], Sedat Dalbayrak[1] and Ali Fahir Özer[2]*

[1]*Department of Neurosurgery, Nörospinal Akademi, Turkey*

[2]*Department of Neurosurgery, Koç University, Istanbul, Turkey*

Abstract

Introduction: Spinal schwannomas constitute up to 30% of all spinal tumors and they are usually located at intradural extramedullary region (72%). Schwannomas may also be located extradurally (13%), intradural and extradural (13%) and intramedullary (1%). They originated from the schwann cell and they grow very slowly. They are usually solitary and most of them are located in the lumbar region. Many criteria have been described spinal giant schwannomas location, shape and sizes.

Materials and Methods: We evaluated spinal giant schwannomas cases retrospectively that were operated between 2005 and 2012. There were 13 spinal giant schwannoma cases. We evaluated patient preoperative and postoperative pain with Visual Analog Scale (VAS). We also examined patients' preoperative and postoperative neurological statue.

Results: Five of the 13 patients were male and 8 were female. Mean age was 47.8 for male and 48.8 for female, 5 cases were located at cervical, 3 at thoracic, 3 at lumbar, 1 at presacral, 1 at lumbosacral region. Pain was the common symptom of the patients (92.3%). Neurological deficit and numbness were other most common symptoms. Minimum spinal giant schwannoma was about 3 cm × 2 cm × 3 cm and maximum was about 10 cm × 10 cm × 12 cm size. Neurological deficit and pain were correlated with spinal giant schwannomas diameter. We performed stabilization only in 2 patients. One of them had deformity at the thoracic region and recurrence mass of schwannoma. The other had a widely lytic lesion at lumbosacral region. So we have done reconstruction with stabilization after excision. Rest of the patients treated with only excision. Pain decreased and neurological status was improved following the surgery.

Conclusion: Surgical treatment is the common treatment for spinal giant schwannomas. Neural decompression is the first aim of the surgery. And gross total resection of the spinal giant schwannomas improves neurological statue. Approach and type of the surgery depends according to the location of the schwannoma. In some cases transforaminal approach will provide an area to remove the mass. Also in some case only laminectomy will be enough to remove the spinal giant shwannoma. Some cases may need instrumentation and stabilization.

Keywords: Giant; Spinal schwannoma; Neurological

OPEN ACCESS

Correspondence:
Ahmet Öğrenci, Department of Neurosurgery, Neurospinal Academy-Kurtköy Ersoy Hospital, Istanbul, Turkey, Tel: +905068860451; E-mail: drahmetogrenci@gmail.com

Received Date: *05 Jun 2017*
Accepted Date*: 04 Aug 2017*
Published Date*: 21 Aug 2017*

Citation:
Öğrenci A, Koban O, Şentürk S, Yaman O, Sasani M, Dalbayrak S, et al. Giant Spinal Schwannomas. Clin Surg. 2017; 2: 1593.

Introduction

Although definitions for giant schwannomas are modified over time, the definition is also used frequently still made by Sridhar [1]. Accordingly, definition of giant schwannomas is done when holding two or more vertebral segments, being dumbbell shape appearance of intraspinal - extraspinal extension, creating large corpus tumors and causing destruction than over 2.5 cm [1-4]. They are spinal neoplasms which usually spread extradural. We have made a brief literature review about spinal giant schwannomas by this article and share our experience in dealing with this issue.

Materials and Methods

Cases fit into definitions of giant schwannomas and surgically treated were evaluated retrospectively. We examined postoperative preoperative images, files, operative notes and follow charts of 13 patients who underwent surgical treatment during 2005-2012. VAS was used for the assessment of preoperative and postoperative pain degree. It is compared with the early and late postoperative neurological deficits in neurological examination of the extremities. It was compared in which way was used for surgery. It was seen that which patients were re-operated. It was viewed that in which patients the stabilization was performed. Besides MR, tomography images were seen from all the patients to examine the bone destruction. Bone destruction was observed in 6 of the cases. All patients were checked with postoperative MR.

Results

Accordingly for this, 5 patients have got giant schwannoma with cervical, 3 patients with thoracic, 3 patients with lumbar,1 patient presacral, and 1 patient lumbosacral region. Five of them were male patients, 8 of them women. The average age for men was 47.8 and 48.8 for woman. The average age for all patients was 48.4. Of these patients, the most common form of presentation was pain (92.3%). Compared to the localization of neurological deficits and numbness were other common complaints. The smallest of the giant schwannomas had a dimension of 3 cm × 2 cm × 3 cm to 10 cm × 10 cm × 12 cm who was in the largest size. There was partial correlation between the size of schwannomas and neurological deficits and pain scores. Surgery for deformity was performed to the one patient who had a thoracic deformity. In the first operation, laminectomy and tumor excision was performed in a patient who had a kyphoscoliosis and after 3 years, because of increased deformity and recurrence of tumor patient underwent excision and stabilization. Deformity of the patient, who was followed 3 years after stabilization and removed the instrumentation, was advanced. Deformity surgery was performed again on re-development. In 2 times surgery of lumbosacral decompression and reconstruction was performed in the patient who had the lumbosacral giant schwannoma (Figure 1). There was no patient performed with stabilization except two patients. Lateral retroperitoneal excision performed to the mass which located at the L1 level (Figure 2). Highly significant improvement was seen at the scoring of pain after the surgeries. Mean follow-up period was of 3.7 years (1-8 years) while the average VAS scores at 8.15 of the patients preoperative, postoperative mean value was 2.3.

Figure 1: In the first operation, laminectomy and tumor excision was performed in a patient who had a kyphoscoliosis and after 3 years, because of increased deformity and recurrence of tumor patient underwent excision and stabilization. Deformity of the patient, who were followed 3 years after stabilization and removed the instrumentation was advanced.Deformity surgery was performed again on re-development.

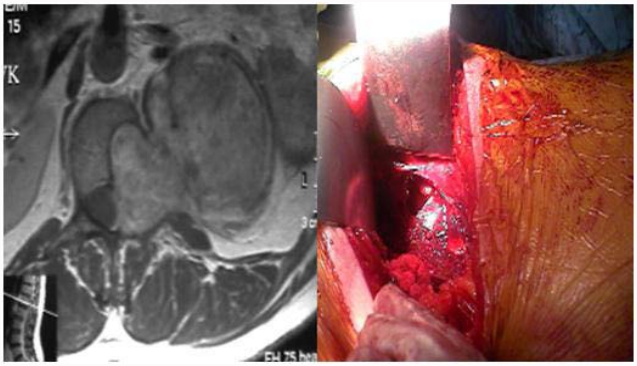

Figure 2: Lateral retroperitoneal excision performed to the mass which located at the L1 level.

Discussion

Spinal schwannomas originate from nerve sheath origin of schwann cells and generally they have slow-growing. They can be in any location where the schwa cells exists. However, it is located commonly at cervical region of C5-6 and lower lumbar region. In our series, we saw that they located mainly at the cervical region too. As likely to be seen in many disc disease at this level and nerve root irritation is accused [5]. The other scenario is the thickest and longest roots are here [6]. They are usually seen in 4 decade and beyond. The average age range of the patients who underwent surgery also fit into these decades. Although in pediatric age group, giant spinal schwannoma are rarely seen, they can be seen in different formations [7]. In pediatric patients under the age of 10 the incidence of schwannomas in all schwannomas is reported as 0.7%. In our series we have seen giant schwannoma in a patient under 18 years of age, it was re-operated on because of the existing scoliotic deformitesi after surgically removed the tumor excision was performed again because of the development of recurrent schwannoma. Pediatric schwannomas are usually very aggressive and usually are associated with NF2. However, in our case it wasn't detected NF. It is said that there was no significant difference in the distribution of men and women in spinal schwannomas [8]. The number of female is greater than male in our 13 cases. Usually they have smooth border encapsulated form. Multiple form is associated with Von Recklingenhaus disease [9]. It can present in different ways depending on the involvement of the spinal canal, but the most commons are sensory- motor deficits, radicular pain and low back pain in their application form [10]. The incidence of pain is 92.3% in the series. Only 1 patient had no pain complaint. According to the settlement in and out of the spinal canal, giant schwannomas can present in different ways. Motor, sensory deficits, urinary and fecal problems can be reasoned by intradural location. They are usually present in different ways according to the settlement which are at extradural region. In our series, only 2 patients had involvement of the mass in intradural region when the others had involvement extradural and extradural-intradural region. We had no patients with involvement in intramedullary.

These schwannomas are common in the lumbar region after myofascial plans are considered invasive. These invasive tumors, which can remain in the psoas muscle and can be diagnosed at this point. By spreading the retroperitoneal region can cause renal problems with involvement in the renal region. It can pressure ureter. Retroperitoneal spreading can be very large sizes. Hematuria and gastrointestinal symptoms may occur [11]. Abdominal pain and weight loss is expected.

Vascular problems may occur after the invasion of abdominal aorta and vascular structures [12]. Renal problems were seen as a result of spreading to the retroperitoneal area in 1 patient. Urinary system strain was present in urination due to compression. In the same way, depending on the involvement of the thoracic spine can cause back pain [12], and it can invade the lungs. It can cause respiratory problems we didn't have a patient who had a mass enough to create respiratory problems.

They can make the invasion of the vertebral artery in the cervical region [13]. Some can show invasion and lytic lesions of vertebral corpus at cervical region which grows through to the anterior [14]

and one patient had a similar problem. In the upper cervical region, there can be catastrophic complaints. We had a patient who had the upper cervical involvement, but there was no neurological problem after surgery because of the less medullary compression.

Diagnosis

Radiographs should be used at the first level to diagnose the disease. Because the findings made by giant schwannoma can be seen in radiographs. Neural foramen expansion, corpus destruction, fractures due to destruction collapse of the levels, pedicle erosions can be seen. However, similar findings are seen on CT and lytic lesion size is easier to understand [15]. CT scans should be performed to all patients in those who were suspected of having schwannomas.

MRI is a sine qua non imaging method. The location, the character and the spreading of the tumor can be seen. Spinal schwannomas are seen usually isointense on T1, hyperintense on T2 in MRI. In contrast sectional homogeneous enhancement is seen in spinal schwannomas while heterogeneous enhancement is seen in giant spinal schwannomas [16]. Reasons are being hemorrhagic, cystic and different cellularity formation. It may be needed for diagnosis with other tests for different areas of patient's involvement. It is also difficult to distinguish radiological images of schwannomas in some tumors although it is the type of dumbbell shape and foraminal extension. Therefore, the other systems must be examined carefully and should be screened for metastasis. It may be difficult to recognize from malignant nerve sheath tumors because of radiological similarities. In the extension of tumors through the abdomen, gastrointestinal and vascular compression can be seen. Even constipation depends on the gastrointestinal compression have been reported [17]. Abdominal aortography is recommended for the tumors which extend through the abdomen located at lumbosacral region. We have done abdominal aortography in our patient with lumbosacral involvement and abdominal aorta's occlusion was detected on pressure. Urological tests should be added at the cases with ureter and renal urologic compression. Voiding capacity should be determined. Accordingly we determined voiding capacity in one patient. Thorax should be viewed in the thoracic region involvement by giant schwannoma. Thoracic CT examinations were performed at the tumors which is located in the thoracic region.

Treatment

Surgical approach has been adopted as the first treatment to reduce the tumor burden is the primary purpose for space-occupying lesions. The results are always found to be better at performing surgery for gross total resection to remove the neural tissue compression. Diagnostic biopsy can be recommended to define the disease to help radiology [18]. Surgery is an option after biopsy but surgery will be the only way for the tumor if it is a giant. Surgical treatment varies according to the size and location of the lesions. Minimally invasive transforaminal approach can be enough for the tumors which extend from the foramen. Excision is possible only in a few tumors of giant schwannomas by this way. We couldn't practice it in our series at the same time, posterior laminectomy can be performed to the tumors which extent to the canal. It was possible that extraction tumor by one side partial hemilaminectomy in our one patient [19]. Facetectomy may be added in appropriate cases, if there was bone destruction, bone resection and stabilization should be added to the surgery. We have performed stabilization in our 2 patients because of various reasons of deformity. We did not practice any cage. Acrylic was applied to the defective area to the patient in the lumbosacral deformity. Anterior transperitoneal approach must combine to posterior approach when anterior corpus resection and cage will be performed. Only posterior approach will be inadequate for resection. Phenol cauterization and filling bone defects with allograft and otograft can be performed besides the surgery. Lateral extracavitary approach can be planned to the tumors which expand to laterally while only posterior approach can be made in the midline thoracic region tumors. In order to reach these tumors may require resection of ribs. We've also added a rib resection of the midline approach in our case. In localized tumors at the cervical region, anterior and posterior approach can be done. Laminectomy or laminoplasty can be performed while surgery. Decompressive laminectomy can be added in the upper cervical region. We have done posterior decompression all of them except one which are located in the cervical. We just have added an anterior resection because of the anterior expanding. It wasn't necessary to the stabilization surgical care and appropriate approach decreases surgical morbidity. In the knee flexion weakness in one patient was observed with a localized tumor in lumbar region as an addition deficiency.

Care Requiring Points

Pre surgery

Preoperative CT evaluation MRI and X-rays should be done preoperatively. According to the degree of invasion, neighboring tissues should be examined. MR image should be viewed in detail. Contrast images should be examined in more detail in terms of invasion. Heterogeneous enhancement should be thought as invasion. X-rays and CT images should be examined for bone structure [20]. Possible instability can be seen by these images. Amount of bleeding is more at preoperative during surgery in patients who have bone involvement [21]. Hypervascularity is likely due to bone involvement relations with neighboring tissue needed to be clarified by additional studies. It has a benefit of studying with EMG for controlling postoperative.

During surgery

Caution should be exercised in terms of giant and invasive schwannomas for the neighboring tissues. Ureters, iliac veins, and cervical vertebral artery should be cared before and pre op surgery the position should be planned to repair deformities, after the extensive resection for sacral area. The decision of the surgeon is important to sacrify the roots pre op. There are many major publications that there will not be a major neurodeficiency after sacrificing roots because of the roots originating from sensory branches [22]. There are some publications that other roots compensate the roots task which is sacrificed. Total resection to be planned, this can be done SEPP and MEP are recommended before the patient receive anesthesia. Examination must be submitted in particular if any suspection is there between schwannoma and MNST on MR image and it should also guide the surgery [23]. Facetectomies and laminectomies should be done minimally to prevent the instability.

After surgery

The most important point is that whether the additional deficiency occurs or not after the surgery. EMG control and postoperative neurologic examination should be done carefully. Ki-67 is a very important parameter Ki-67 should be used for follow up and tumor residue. To be over 2% should be complimented. It should be cautionary for recurrence. Early postoperative MRI images should be examined carefully for residuals. Neurological

examination and evaluation is more valuable than MRI. MRI can create artefacts if there is instrumentation and can be misleading for scar tissue, postoperative changes, hemorrhage and inflammation. It is recommended to wait 1 year if there is not a position of major clinical status. All of the patients in our series were scanned by early postoperative MRI. It was seen that total resection was performed in all patients. We saw the giant schwannomas could be excised by appropriate approach.

References

1. Sridhar K, Ramamurthi R, Vasudevan MC, Ramamurthi B. Giant invasive spinal schwannomas: definition and surgical management. J Neurosurg. 2001;94(2):210-5.
2. Ueda R, Yoshida K, Kawase T. Intradural C-1 ventral root schwannomas treated by surgical resection via the lateral suboccipital transcondylar approach: three case reports. Neurol Med Chir. 2006;46(6):298-301.
3. Dickman CA, Fehlings MG, Goksalan ZL. Spinal cord and spinal column tumors: Principles and practice. New York: Stuttgart Thieme; 2006. p. 712.
4. Colosimo C, Cerase A, Denaro L, Maira G, Greco R. Magnetic resonanceimaging of intramedullary spinal cord schwannomas. Report of two cases and review of the literature. J Neurosurg. 2003;99(1):114-7.
5. Chiang, En-Rung, Ming-Chau Chang, Tain-Hsiung Chen. Giant retroperitoneal schwannoma from the fifth lumbar nerve root with vertebral body osteolysis: a case report and literature review. Arch Orthop Trauma Surg. 2009;129(4):495-9.
6. Cohen MS, Wall EJ, Olmarker K, Rydevik BL, Garfin SR. Anatomy of the spinal nerve roots in the lumbar and lower thoracic spine. In: Rothman RH, Simeone FA, editors. The Spine. 3rd and 4th ed. Philadelphia: WB Saunders Company; 1992. pp. 99-106.
7. Vadivelu S, Prasad P, Adesina AM, Kim E, Luerssen TG, Jea A. Giant invasive spinal schwannoma in children: a case report and review of the literature. J Med Case Rep. 2013;7:289.
8. Seppala MT, Haltia MJ, Sankila RJ, Jaaskelainen JE, Heiskanen O. Long-term outcome after removal of spinal schwannoma: a clinicopathological study of 187 cases. J Neurosurg. 1995;83(4):621-6.
9. Conti P, Pansini G, Mouchaty H, Capuano C,Conti R. Spinal neurinomas: retrospective analysis and long-term outcome of 179 consecutively operated cases and review of the literature. Surg Neurol. 2004;61(1):34-43.
10. Jeon JH, Hwang HS, Jeong JH, Park SH, Moon JG, Kim CH. Spinal schwannoma; analysis of 40 cases. J Korean Neurosurg Soc. 2008;43(3):135-8.
11. Singh V, Kapoor R. Atypical presentations of benign retroperitoneal schwannoma: report of three cases with review of literature. Int Urol Nephrol. 2005;37(3):547-9.
12. Angelopoulos E, Eleftheriou K, Kyriakopoulos G, Athanassiadi K, Rontogianni D, Routsi C. A Giant Intrathoracic Malignant Schwannoma Causing Respiratory Failure in a Patient without von Recklinghausen's Disease. Case reports in Medicine. 2016;3.
13. Oruckaptan HH, Gürçay O. Combined posterior and posterolateral one-stage removal of a giant cervical dumbbell schwannoma. Pediatr Neurosurg. 1999;30(2):102-7.
14. Singrakhia MD, Parmar H, Maheshwari M, Fehlings M. Cervical schwannoma presenting as an expansile vertebral body lesion: report of two cases with a technical note on the surgical management. Surg Neurol. 2006;66(2):192-6.
15. Barnowsky L, Dalal R. Extradural schwannoma manifested as an expansile vertebral lesion. AJR Am J Roentgenol. 1992;159(6):1352-3.
16. Parmar HA, Ibrahim M, Castillo M, Mukherji SK. Pictorial essay: diverse imaging features of spinal schwannomas. J Comput Assist Tomogr. 2007;31(3):329-34.
17. Samarakoon L, Weerasekera A, Sanjeewa R, Kollure S. Giant presacral schwannoma presenting with constipation: a case report. J Med Case Rep. 2012;6:285.
18. Valle-Giler EP, Garces J, Smith RD, Sulaiman WA. One-stage resection of giant invasive thoracic schwannoma: case report and review of literature. Ochsner J. 2014;14(1):135-40.
19. Canbay S, Hasturk AE, Basmaci M, Erten F, Harman F. Management of thoracal and lumbar schwannomas using a unilateral approach without instability: an analysis of 15 cases. Asian Spine J. 2012;6(1):43-9.
20. Gustav K, von Schulthess, Christoph Zollikofer. Diseases of the Brain, Head & Neck, Spine: Diagnostic Imaging and Interventional Techniques. Springer Science & Business Media. 2008;9.
21. Yu NH, Lee SE, Jahng TA, Chung CK. Giant invasive spinal schwannoma: its clinical features and surgical management. Neurosurgery. 2012;71(1):58-67.
22. Kim P, Ebersold MJ, Onofrio BM, Quast LM. Surgery of spinal nerve schwannoma. Risk of neurological deficit after resection of involved root. J Neurosurg. 1989;71(6):810-4.
23. Kim ER, Choi EO, Lee KB, Kang CH, Kim YT, Park IK. A recurrent cellular schwannoma. Korean J Thorac Cardiovasc Surg. 2014;47(5):487-90.