



Flanged Sutureless Scleral Fixation Technique for Dislocated Sulcus IOL in Patient with High Myopia

Remzi Karadag*, Nadim Bromound and Ozgur Cakici

Department of Ophthalmology, Istanbul Medeniyet University, Turkey

Abstract

We describe a flanged Sutureless Scleral Fixation (FSSF) technique for dislocated sulcus Intraocular Lens (IOL) in patient with high myopia. We formed a 2 mm scleral tunnel 2 mm from and parallel to the limbus with 27-gauge needle entering sclera transconjunctivally. The leading haptic was threaded into the lumen of the needle using a 23-gauge forceps. This haptic was externalized onto the conjunctiva and a transconjunctival safety suture is placed at the tunnel entry side around the haptic with a 10-0 nylon suture. These steps are repeated for the other haptic. The ends of the haptics were cauterized to make a flange. The flanges of the haptics were pushed back and fixed into the scleral tunnels. The safety suture is removed at postoperative first week. No complications were seen intraoperatively or postoperatively. Using FSSF of IOL method in patient with high myopia is an alternative scleral fixation surgery.

Keywords: Dislocated sulcus IOL; Flanged, High myopia; Intrascleral; Haptic

Introduction

Intraocular Lens (IOL) dislocation develops after cataract surgery in the presence of insufficient capsule or zonular support. IOL dislocation can be seen more in association with factors such as high myopia, previous vitreoretinal surgery, and uveitis [1]. Having high myopia is one of the most common causes of late-onset IOL dislocations [2]. When an IOL dislocation occurs, either the IOL can be removed and replaced with a new one, or IOL can be repositioned with different methods. The repositioning of the IOL can vary depending on the nature of the lens. Because posterior chamber lenses are used, iris or sclera fixation methods can be used in the correction of these lenses. The methods used have their own advantages and disadvantages [1]. In the management of dislocated IOLs due to high myopia, replacement with a new anterior chamber lens or scleral fixation lens, iris or sclera suture fixation methods were used [2]. Recently, Sutureless Scleral Fixation (SSF) methods began to be used widely [3-6]. There are very few publications in the literature about SSF of dislocated sulcus IOL [7]. However, there is no published literature regarding the SSF of dislocated sulcus IOL in patients with high myopia. In this case report, 27-gauge needle-assisted flanged SSF method will be presented in a patient with high myopia and dislocated three pieces IOL in the sulcus.

Case Presentation

A 50-year-old female operated in another clinic presented with low vision 10 months after cataract surgery. Intra-temporally dislocated three pieces IOL in sulcus was observed at the examination (Figure 1a). We planned to fixate the implanted IOL with SSF techniques which require less manipulation since we didn't prefer explanting the IOL. Since we do not know the haptic structure of the IOL inserted in cataract surgery, we decided to choose the SSF method after seeing the lens haptics during surgery. After marking of the peripheral cornea at 180 degrees apart at the 6 o'clock and 12 o'clock position, two opposite corneal incisions were made with the MVR knife (Figure 1b). The anterior chamber was filled with OVD. Because of the "J" shape of the three-piece IOL haptics that have already been inserted, we have decided to make a flanged sutureless intrascleral haptic fixation method. We formed a transconjunctival 2 mm scleral tunnel, 2 mm from and parallel to the limbus with 27-gauge needle at an approximately 20 degrees angle (Figure 1c, 1d). The leading haptic was threaded into the lumen of the needle using a 23-gauge serrated forceps (Figure 1e). This haptic was externalized onto the conjunctiva (Figure 1f) and a transconjunctival safety suture is placed at the scleral tunnel entry site around the haptic with a 10-0 nylon suture (Figure 2a). These steps are repeated for the other haptic (Figure 2b, 2c). The ends of the haptics were cauterized to make a flange (Figure 2d). The flanges of the haptics were pushed back and fixed into the scleral tunnels (Figure 2e, 2f). This safety suture is removed at postoperative first week. No

OPEN ACCESS

*Correspondence:

Remzi Karadag, Department of Ophthalmology, Istanbul Medeniyet University, Goztepe, Istanbul, Turkey, Tel: +90 216 2803333; Fax: +90 216 6022800;

E-mail: drkaradag@yahoo.com

Received Date: 19 Sep 2019

Accepted Date: 21 Oct 2019

Published Date: 30 Oct 2019

Citation:

Karadag R, Bromound N, Cakici O. Flanged Sutureless Scleral Fixation Technique for Dislocated Sulcus IOL in Patient with High Myopia. Clin Surg. 2019; 4: 2632.

Copyright © 2019 Remzi Karadag.

This is an open access article distributed under the Creative Commons Attribution License, which permits unrestricted use, distribution, and reproduction in any medium, provided the original work is properly cited.

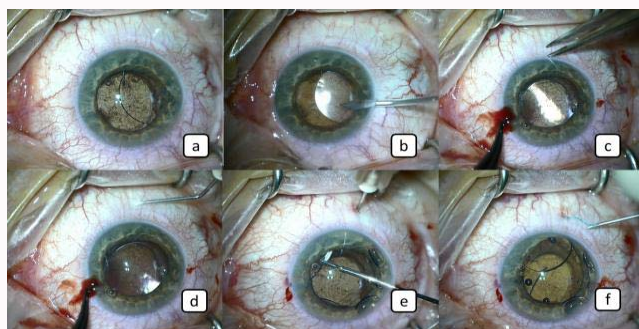


Figure 1: a: Inferotemporally dislocated three pieces sulcus IOL, b: Two opposite corneal incision were made with the MVR knife, c,d: 2 mm scleral tunnel 2 mm from and parallel to the limbus with 27-gauge needle, e: The leading haptic was threaded into the lumen of the needle using a 23-gauge forceps, f: The haptic was externalized onto the conjunctiva.

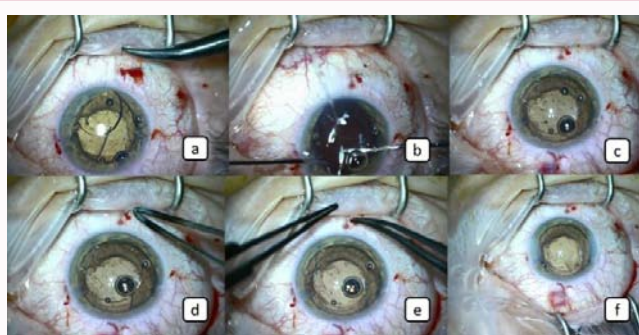


Figure 2: a: Transconjunctival safety suture is placed at the scleral tunnel entry site around the haptic, b,c: The second haptic was threaded into the lumen of the needle using a 23-gauge forceps and the haptic was externalized onto the conjunctiva, after then safety suture is placed, d: The ends of the haptics were cauterized to make a flange, e: The flanges of the haptics were pushed back and fixed into the sclera tunnels, f: The appearance of eye at the end of the surgery.

complications were seen intraoperatively or postoperatively. After 1 month follow-up period IOL was seen stabilized.

Discussion

Since the eyes of patients with high myopia are larger in diameter, IOLs placed in these eyes are more likely to be dislocated than normal subjects. In addition, zonular weakness can develop because of the eye diameter enlargement in these patients. When sulcus-fixated IOL is inserted due to the above reasons it can be dislocated [2]. Severe IOL decentration or dislocation may cause glare, diplopia and decreased visual acuity; surgical intervention may become necessary in such cases [1]. There are many surgical methods. The choice of methods is mostly dependent on the state of the capsule. According to the state of the capsule, IOL can be repositioned in the sulcus. Iris or sclera fixation methods can be used [1]. Recently, SSF methods have been widely used. So far, these methods are usually performed as implantation of three-piece lenses in aphakic patients with insufficient capsule support. These methods have the advantages of not using suture and avoiding complications due to suture [3-10]. In our case, we chose flanged SSF because it had a three-piece IOL "J" haptic. Intrascleral fixated IOL implantation methods that have been made up to now; three-piece IOLs with a "C" haptic are generally

preferred [3]. The reason for choosing such a lens is that it is easier to place both haptics in the sclera than the "J" haptics. Generally The first haptic emerges from the sclera when attempting to place the second haptic into the sclera in "J" IOLs. In order to prevent this possibility, we put a safety suture with 10-0 nylon suture after being taken out of the first haptic. After placing both haptics in scleral tunnels, we formed a knob by cauterizing the tip of the haptics. We achieved good stability in haptics by both of them; safety suture and knob at the tip of the haptics. Yamane et al. for the first time reported a flanged sutureless intrascleral IOL fixation method with the help of a cautery. They pulled the haptics out of the eye by two 30 gauge needles [6]. According to our idea the fact that two needles at the same time inside the eye increase the possibility of surrounding tissues damage [8]. In our method, with a 27 gauge needle, we first removed the first haptic from the eye and placed a safety suture, then we pulled the second haptic out and put a safety suture and cauterized the end of the haptics to make a flange. We took these safety sutures at the end of the first post-operative week that we thought fibrosis developed around the haptics. In transconjunctival scleral-fixated IOL implantation methods, the temporary safety suture provides both a good haptic stabilization and a reduction in the postoperative hypotonia and risk of endophthalmitis. We have not found any complications in our case' follow-up. In conclusion, using flanged sutureless intrascleral IOL fixation method in patient with high myopia is an alternative SSF surgery.

References

1. Dajee KP, Abbey AM, Williams GA. Management of dislocated intraocular lenses in eyes with insufficient capsular support. *Curr Opin Ophthalmol.* 2016;27(3):191-5.
2. Fernández-Buenaga R, Alio JL, Pérez-Ardoy AL, Cortes LP, Barraquer R, Negrete JM. Late in-the-bag intraocular lens dislocation requiring explantation: risk factors and outcomes. *Eye (Lond).* 2013;27(7):795-801.
3. Karadag R, Celik HU, Bayramlar H, Rapuano CJ. Sutureless Intrascleral Fixated Intraocular Lens Implantation. *J Refract Surg.* 2016;32(9):586-97.
4. Totan Y, Karadag R. Trocar-assisted sutureless intrascleral posterior chamber foldable intra-ocular lens fixation. *Eye (Lond).* 2012;26(6):788-91.
5. Totan Y, Karadag R. Two techniques for sutureless intrascleral posterior chamber IOL fixation. *J Refract Surg.* 2013;29(2):90-4.
6. Yamane S, Sato S, Maruyama-Inoue M, Kadonosono K. Flanged Intrascleral Intraocular Lens Fixation with Double-Needle Technique. *Ophthalmology.* 2017;124(8):1136-42.
7. Singh R, Bhalekar S. Repositioning a dislocated intraocular lens in the ciliary sulcus using 23-gauge sutureless pars plana vitrectomy. *J Cataract Refract Surg.* 2011;37(3):438-40.
8. Yamane S, Inoue M, Arakawa A, Kadonosono K. Sutureless 27-gauge needle-guided intrascleral intraocular lens implantation with lamellar scleral dissection. *Ophthalmology.* 2014;121(8):61-6.
9. Karadag R, Bayramlar H, Azari AA, Rapuano CJ. Trocar-Assisted, Sutureless, Scleral-Fixated Intraocular Lens Implantation Combined With Penetrating Keratoplasty. *Cornea.* 2016;35(9):1261-5.
10. Totan Y, Karadag R. New approach: removal of silicone oil and trocar assisted sutureless scleral fixated intraocular lens implantation at the same session. *Int J Ophthalmol.* 2014;7(4):734-6.