



Fibrosarcoma of the Foot Misdiagnosed as Neurinoma with Fatal Outcome

Elroy Patrick Weledji*, Divine Eyongeta and Pius Fokam

Department of Surgery, University of Buea, Cameroon

Keywords

Fibrosarcoma; Malignant tumour; Soft tissue tumour

Clinical Image

Fibrosarcoma make up a small percentage of soft somatic tissue malignancies. With respect to anatomical location, fibrosarcomas of the foot constitute an even smaller percentage of reported cases of fibrosarcoma (Figure 1a,1b). Fibrosarcoma (Fibroblastic Sarcoma) is a malignant tumor derived from fibrous connective tissue and characterized by the presence of immature proliferating fibroblasts or undifferentiated anaplastic spindle cells in a storiform pattern. The diagnosis is often difficult to make because of the similar microscopic presentation of plantar fibromatoma and fibrosarcoma (Figure 2). The diagnosis is thus made by exclusion. In addition the postoperative local recurrence of fibrosarcoma is great. We report a case of a progressively enlarging and ulcerating large plantar fibrosarcoma in a 35-year old black African woman. A pathological diagnosis of a neurinoma based on the microscopic examination of wavy neural fusiform fibres in bands Antoni A and Antoni B foci without atypia was suggested. Wide local excision (Figures 1a, 1b) with no adjuvant radio/chemotherapy was followed by local recurrence and death 4 months later from lung metastases.

OPEN ACCESS

*Correspondence:

Elroy Patrick Weledji, Department of Surgery, University of Buea, PO Box 63, Buea, Cameroon,

E-mail: elroypat@yahoo.co.uk

Received Date: 10 Jul 2019

Accepted Date: 15 Aug 2019

Published Date: 21 Aug 2019

Citation:

Weledji EP, Eyongeta D, Fokam P. Fibrosarcoma of the Foot

Misdiagnosed as Neurinoma with Fatal Outcome. *Clin Surg.* 2019; 4: 2555.

Copyright © 2019 Elroy Patrick Weledji. This is an open access

article distributed under the Creative Commons Attribution License, which permits unrestricted use, distribution, and reproduction in any medium, provided the original work is properly cited.

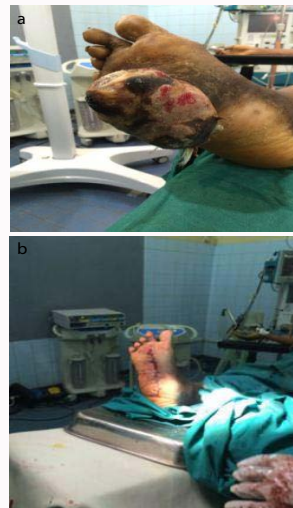

Figure 1: (a) preoperative. (b) postoperative.

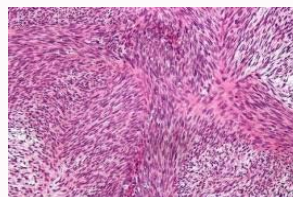


Figure 2: Fibrosarcoma: The histomorphological herringbone pattern in a malignant peripheral nerve sheath tumor is similar to synovial sarcoma and fibrosarcoma. The diagnosis is only made by exclusion.