



# Exploration on the Application of Successive Triangular Skin Flap Peeling Method in Transcutaneous Blepharoplasty

Mengjuan Li\*

Department of Plastic Surgery, Xiangya Hospital, Central South University, P.R. China

## Abstract

**Objective:** To introduce the clinical application of transcutaneous blepharoplasty with successive small triangular skin flap and evaluate the postoperative effects.

**Methods:** During the surgery, the incision of skin is about 2 mm below the eyelid margin, and then developing a plane between septum and the preseptal orbicularis to expose the orbital septum. Two successive small triangular skin flaps were designed chronologically to remove the slack skin, and then the skin incision is sutured with 7-0 nylon line. The suture is removed 7 days after the surgery, and the follow-up period was 6 to 12 months.

**Results:** This method can control the amount of slack skin and morphology of the lower eyelid was significantly improved. Only 1 patient showed insufficient amount of postoperative peeling, and the improvement effect was not obvious.

**Conclusion:** The transcutaneous blepharoplasty with successive small triangular skin flap can estimate the amount of redundant skin more accurately. What's more, it can reduce the incidence of complications, especially the lower eyelid ectropion and improve the rate of satisfaction, and is worth advocating in transcutaneous blepharoplasty.

**Keywords:** Lower blepharoplasty; Transcutaneous; Successive small triangular skin muscle flap

## OPEN ACCESS

### \*Correspondence:

Mengjuan Li, Department of Plastic Surgery, Xiangya Hospital, Central South University, 87 Xiangya Road, Changsha 410008, P.R. China, Tel: 18838990871;

E-mail: 18838990871@163.com

Received Date: 07 Apr 2022

Accepted Date: 05 May 2022

Published Date: 23 May 2022

### Citation:

Li M. Exploration on the Application of Successive Triangular Skin Flap Peeling Method in Transcutaneous Blepharoplasty. *Clin Surg.* 2022; 7: 3513.

Copyright © 2022 Mengjuan Li. This is an open access article distributed under the Creative Commons Attribution License, which permits unrestricted use, distribution, and reproduction in any medium, provided the original work is properly cited.

## Introduction

Transcutaneous blepharoplasty is one of the routine operations in plastic surgery, but the amount of skin needs to cut is not easy to control. Too much skin excision is prone to lower eyelid retraction and blepharoplasty separation, and too little excision leads to unsatisfactory improvement of lower eyelid shape. In this study, two successive small triangular flaps were designed to cut the skin in the transcutaneous blepharoplasty. Through the observation of the curative effect of 58 patients, it is found that this method can estimate the redundant skin more accurately, the incidence rate of postoperative complications (especially lower eyelid ectropion) is low and the patients' satisfaction is high, so it is an accurate redundant skin removal method worthy to be advocated.

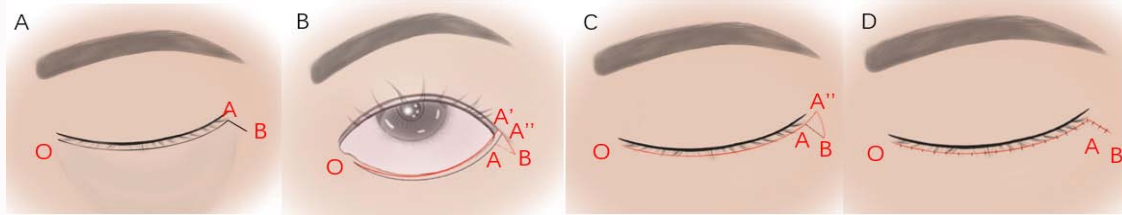
## Clinical Data

From April 2019 to April 2021, a total of 58 patients were treated with transcutaneous blepharoplasty with successive small triangular skin flap. 37 patients underwent orbital fat transposition and fixation at the same time. All patients were photographed before operation and signed the operation consent.

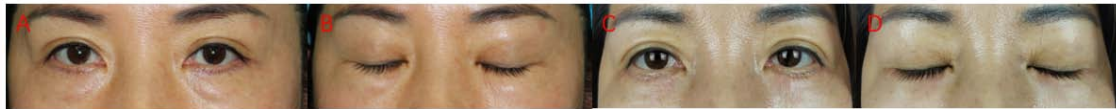## Methods

This operation adopts the method of successive small triangular skin flap, which includes three key steps: formation of musculocutaneous flap, removal of successive small triangular skin flap and lateral canthoplasty.

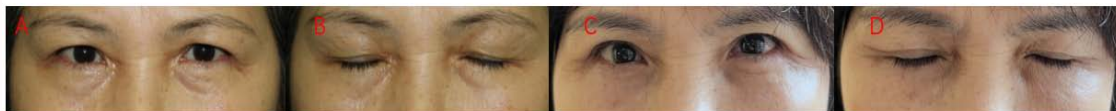- The patients were told in supine position and closed the eyes. Then we designed the incision parallel to the lower palpebral margin and move down 2 mm, marked the lower orbital margin, and fix it with iodine tincture.
- After routine disinfection, subcutaneous infiltration anesthesia with 2% lidocaine and 1:200,000 epinephrine was performed.



**Figure 1:** Schematic diagram of operation A: design surgical incision line; B: remove redundant skin from the horizontal directions (OA' A); C: remove redundant skin from the vertical directions (AA''B); D: Continuous suture of lower eyelid skin.



**Figure 2:** Female, 52 years old. A, B: preoperative photos; of C, D: postoperative photos, Eight months after operation.



**Figure 3:** Female, 59 years old. A, B: preoperative photos; of C, D: postoperative photos, 1 year after operation.

- Cutting the skin along the incision line of below the lower palpebral margin. Then separating the skin about 5 mm below the superficial surface of orbicularis oculi muscle and cutting the orbicularis oculi muscle parallel to the skin incision. Exposing the orbital septum and separating to about 5 mm below the lower orbital margin along the superficial surface of the orbital septum with blunt dissection (Figure 1A).

- Open the orbital septum to expose orbital fat. For patients with obvious lacrimal groove deformity, the anterior maxillary space can be further opened and the orbital septum fat can be transferred into this space.

- Spread the free lower eyelid flap on the lower eyelid and tell the patient do his utmost to look up and keep still. Then judge the skin redundancy parallel to the lower eyelid margin. Mark the first triangular flap (with the inner incision as the vertex and the outer edge of the incision as the bottom of triangle) and remove it. Lift the skin flap to the outside to judge the redundancy of the outside skin, mark the second triangular flap (with the turning point of the incision as the vertex and the lateral incision as the bottom edge of triangle) and remove it. In this way, we can realize the redundant skin was cut sufficiently (Figure 1B, 1C).

- 6.5-0 absorbable thread is used to fix the lower eyelid flap to the lateral canthal ligament, and 7-0 nylon thread is used to continuously suture the cut skin and muscle (Figure 1D).

- Routine eyelid ice compress, timely cleaning of eye secretions and use ophthalmic antibiotic eye ointment to prevent infection were carried out after the operation.

- Follow-up time is 6 to 12 months after operation, take photos of the patients and ask patients' satisfaction at the same time.

## Results

In this study, total of 58 patients were followed-up, ranging in age from 32 to 67 years old and with an average age of 40 years old.

There were 9 male patients (15.5%) and 49 female patients (84.5%). All patients did not occur lower eyelid ectropion, no obvious postoperative hematoma and seroma; only 2 patients had transient conjunctival edema and improved within 2 weeks after using hormone eye ointment. One patient recurred 8 months after operation because of the conservative resection of redundant skin. The incisions were all healed in one stage. The redundant skin of lower eyelid can be judged accurately, and the appearance can be improved obviously. The overall satisfaction rate is 98%. (Typical cases: Figure 2, 3).

## Discussion

Periocular aging mainly manifested as pouch-shaped protrusion of lower eyelid, sagging of lower eyelid skin accompanied by obvious lacrimal groove deformity and palpebral groove, which directly affects people's mental state and aesthetic feeling. In the past, it was generally believed that the causes of eye bags were the loose of skin around eyes, the loose or hypertrophy of orbicularis oculi muscle or the weaken of orbital septum with orbital fat hernia. At present, it was generally believed that eye bags were mostly formed by the decrease of orbital fat volume, sagging of middle face and bone absorption of orbital margin, and were aggravated by the shadow of prominent orbital fat and orbicularis muscle [1-3]. Lower eyelid blepharoplasty is extremely challenging due to individual differences and extremely high incidence of complications [4]. At present, blepharoplasty can be roughly divided into transconjunctival blepharoplasty and transcutaneous blepharoplasty. Patients with the loose of lower eyelid skin and orbicularis oculi muscle are the best indications for transcutaneous blepharoplasty [2,5,6]. Transcutaneous blepharoplasty with musculocutaneous flap has less risk, can produce natural and predictable postoperative effect and is an excellent indication for patients with redundant skin and muscles [7]. Transcutaneous blepharoplasty has the risk of complications such as lower eyelid retraction, scleral exposure and lateral angle rounding [7,8]. The causes of lower eyelid retraction mainly include excessive skin cutting, lower eyelid hematoma systematization, diaphragm fibrosis

and intraoperative injury of zygomatic branch of facial nerve [9-12]. The difficulty to judge the redundant skin is the main reason for the poor postoperative morphological improvement and complications. Because of the poor skin elasticity of lower eyelid and the asymmetric appearance of bilateral bags under the eyes, it is difficult to accurately judge the peeling amount of lower eyelid. Successive triangular flap method is the key to accurately control the redundant skin. Two small triangular flaps were designed in the operation, so as to gradually adjust and remove the redundant skin, which can greatly reduce the risk of lower eyelid ectropion and postoperative complications. Two small triangular flaps designed successively can remove redundant skin from the horizontal and vertical directions, so as to accurately determine the amount of tissue to be removed. The successive triangle skin flap method also has a good effect on bilateral asymmetrical pouch. The bilateral symmetrical appearance can be better improved by judging the bilateral lower eyelid separately. The transcutaneous blepharoplasty with successive small triangular skin flap requires a high compliance of patients during the operation, which can affect the incidence of lower eyelid ectropion directly. Because of the poor skin elasticity, the judge of redundant skin during operation should be conservative and repeated evaluation can help to reach the best results.

## Conclusion

The transcutaneous blepharoplasty with successive small triangular skin flap can accurately judge the redundant skin. The postoperative effect is stable with the hidden eyelid scar and lower incidence of complications, which is worthy further advocacy and clinical application.

## References

1. Murri M, Hamill EB, Hauck MJ, Marx DP. An update on lower lid blepharoplasty. *Semin Plast Surg.* 2017;31(1):46-50.
2. Bhattacharjee K, Ghosh S, Ugradar S, Azhdam AM. Lower eyelid blepharoplasty: An overview. *Indian J Ophthalmol.* 2020;68(10):2075-83.
3. Lambros V. Observations on periorbital and midfaceaging. *Plast Reconstr Surg.* 2007;120(5):1367-76.
4. Pacella SJ, Codner MA. Minor complications after blepharoplasty: Dryeyes, chemosis, granulomas, ptosis, and scleral show. *Plast Reconstr Surg.* 2010;125:709-18.
5. Smith CB, Waite PD. Lower transcutaneous blepharoplasty. *Atlas Oral Maxillofac Surg Clin North Am.* 2016;24(2):135-45.
6. Rouso DE, Brys AK. Extended lower eyelid skin muscle blepharoplasty. *Facial Plast Surg.* 2011;27(1):67-76.
7. Shadfar S, Perkins SW. Transcutaneous skin-muscle flap suspension lower-eyelid blepharoplasty. *JAMA Facial Plast Surg.* 2015;17(6):459-61.
8. Hutchinson C. Cosmetic oculoplastic surgery-eyelid, forehead, and facial techniques. *Br J Ophthalmol.* 1999;83(10):1207b-11207.
9. Bhoutekar P, Winters R. Blepharoplasty subciliary approach. StatPearls. Treasure Island (FL): StatPearls Publishing. 2020.
10. Seiff SR. Complications of upper and lower blepharoplasty. *Int Ophthalmol Clin.* 1992;32:67-77.
11. Hamako C, Baylis HI. Lower eyelid retraction after blepharoplasty. *Am J Ophthalmol.* 1980;89:517-21.
12. Carraway JH, Mellow CG. The prevention and treatment of lower lidectropion following blepharoplasty. *Plast Reconstr Surg.* 1990;85:971-81.