Clinics in Surgery

Review Article
Published: 25 May, 2017

Evaluation and Surgical Treatment of Adult Pectus Excavatum Patients

*MennatAllah M. Ewais and Dawn E. Jaroszewski**

Department of Cardiothoracic Surgery, Mayo Clinic Hospital, Phoenix, Arizona, USA

Abstract

Pectus excavatum is one of the most common congenital chest wall deformities, in which the sternum and the adjacent costal cartilages are displaced posteriorly. Physiological limitations and psychological impacts of the deformity may occur as the patient ages and the chest wall becomes more rigid. Adult patients can undergo surgical correction of their deformity with excellent results. A minimally invasive approach to the repair of adult patients can be successfully utilized.

Introduction

The two most common congenital chest wall deformities are pectus excavatum (PE) and pectus carinatum [1-3]. Although in the past physicians considered PE primarily an aesthetic problem, studies continue to document physiologic limitations caused by the deformity [4-8]. Significant improvement in cardiopulmonary function and exercise ability can be achieved with surgical correction [4,6,7,9-13]. In most patients the development of PE tends to be more prominent during periods of rapid skeletal growth with stabilization after reaching skeletal maturity [14]. Most patients begin experiencing symptoms in their adolescence, however, some may not develop symptoms until adulthood as the chest wall becomes more rigid [7,15-16]. Both open and minimally invasive techniques have been described for repair of adult PE with the modified Nuss procedure becoming a more common repair method with experience and technique modifications [7,15,17-26] (Figure1).

Key Points

- Comprehensive history, physical examination and investigations are necessary for evaluation of PE repair.
- Symptomatic adult patients with evidence of cardiac compression are candidate for surgical repair.
- Modified Nuss procedure has been performed in adult patients with successful results.
- Some form of open repair is required only for a small percentage of more complex and recurrent PE cases.

Female patients can have their deformity repaired along with breast implants during the same surgical procedure.

Presentation of Adult Pectus Patients

The age of presentation of PE varies. Although it can be present at birth, most patients present during their childhood period or teenage years [7,27]. PE can be a cosmetic problem with minor symptoms however, it can also present with compromise in cardiopulmonary function [4,6]. Symptoms such as shortness of breath, palpitations, chest pain and fatigue may become more prominent with advancing age due to the decrease in the chest wall compliance with subsequent increase in cardiac compression [7,16,28-29]. Kraatgen et al. [16] reported the majority of his adult patients did not have symptoms occur until the 4th and 5th decades. Most commonly reported symptoms include progressive shortness of breath, tachycardia/palpitations, exercise intolerance and chest pain [16,27-30]. There is an association in some patients between connective tissue disorders such as Marfan, Ehlers-Danlos, and Noonan syndromes and PE [30-31].

Cardio-pulmonary Implications of Pectus on Adults

Studies have proven that severe PE can cause significant compression to the right heart chambers [4,29,32]. Displacement of the heart into the left chest may occur to varying degreesand significant

OPEN ACCESS

Correspondence:
Dawn E. Jaroszewski, Department of Cardiothoracic Surgery, Mayo Clinic, Arizona, 5777 E Mayo Blvd., Phoenix, USA, Tel: 480-342-2270; Fax: 480-342-2269;
E-mail: jaroszewski.dawn@mayo.edu

Received Date: *02 Feb 2017*
Accepted Date*: 15 May 2017*
Published Date*: 25 May 2017*

Citation:
Ewais MAM, Jaroszewski DE. Evaluation and Surgical Treatment of Adult Pectus Excavatum Patients. Clin Surg. 2017; 2: 1481.

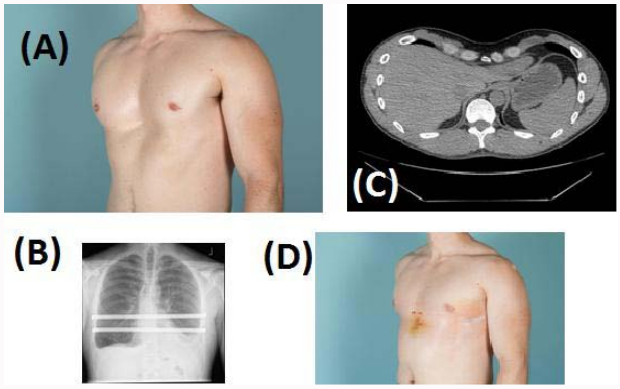

Figure 1: A 36 year old patient with severe PE deformity (a), Computerized tomographic scan shows Inspiratory Haller Index: 5 (b). Patient was repaired with modified Nuss procedure with placement of 2 sternal pectus bars as shown in posteroanterior radiographic image(c) to achieve adequate chest wall elevation (d).

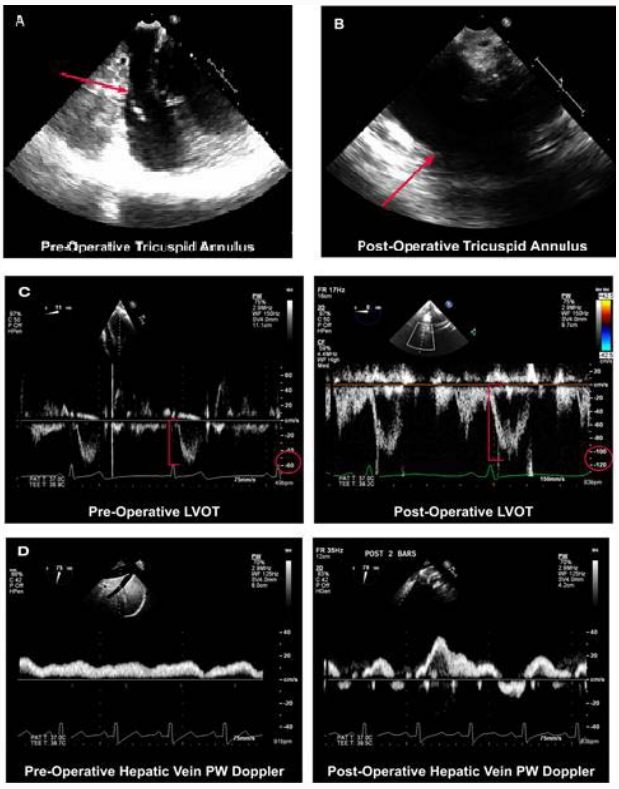

Figure 2: Right-sided heart compression can be significant due to the pectus deformity. Tricuspid annulus dimensions (a, b) and with associated diastolic dysfunction that is improved after surgical repair.Left ventricular outflow tract velocities (c) and hepatic vein doppler pulse waves (d) can be seen to significantly increase after surgical repair.

right sided heart compression can cause diastolic dysfunction and decreased cardiac output [4,32]. Surgical repair has been shown to provide significant increase in right sided chamber size, increased flow velocities and improved cardiac output [4,15,32] (Figure 2). With right atrium compression subsequent reduction inthe atrial filling and venous return can occur [33]. Mocchegiani et al. [34] studied the relation between the severity of PE and its impact on the morphology and the function of the right ventricle (RV). They found that in PE patients, the right ventricle outflow tract was significantly narrower at the aortic root level and right ventricle end-diastolic and end-systolic areas were larger in controls. The study also showed significant morphological variations in the RV of PE patients compared to the control group, there was a higher incidence of RV with rounded apex, trabecular hypertrophy, and changes in the structure of moderator band were seen as well, as RV wall sacculation [34]. In a recent retrospective study conducted for adult patients who underwent surgical repair for their PE deformity using a modified Nuss procedure from 2011 to 2014, Chao et al. [4], reported significant increase in the RV outflow tract (16.2%), cardiac output (38.3%) and in the RV stroke volume (33.6%) in comparison to the preoperative values.

Cardiopulmonary exercise testing (CPET) is used to assess the exercise capacity and evaluate the physiological impairments which can result as a consequence of the pectus deformity [35-36]. Limitations in cardiopulmonary functions have been reported in PE patients with abnormally low peak oxygen up take VO_2 (L/min) and O_2 pulse (mL/beat) during exercise testing [9,12]. Fick equation is used to calculate the VO_2; VO_2 = cardiac output (CO)x difference between the oxygen content in the arterial and the venous blood $C(a\text{-}\bar{v})O_2$, while the O_2 pulse is used to determine the stroke volume during exercise testing [36]. In PE patients, one or more of these parameters can be affected which then lead to decline in the exercise endurance [36]. The patient's standard exercise history must be documented during assessment. Cardiac output, which is the product of the stroke volume (SV) and the heart rate (HR), can decrease with inactivity [37]. Therefore it is important to take into consideration the patient's exercise history as patient's activity may decrease after surgery, which then can affect the measurements of the VO_2 [36]. The effects of surgical correction have been debated with variable results published [6,9,10,38]. Neviere et al. [9] reported a significant increase in exercise ability and in the VO_2 and O_2 pulse at 1 year follow up in 70 patients who underwent surgical repair of PE compared to their preoperative measurements. Sigalet et al. [6] also found significant cardiopulmonary function improvement at >3 months following the removal of the pectus bars. There were improvements in VO_2 max, O_2 Pulse and respiratory quotient in comparison to the preoperative measurements. No long term results have been published and a more recent midterm evaluation by Udholm et al. [38] did not show any significant improvement in the cardiac output or in the VO_2 max in adult patients 1 year after repair, however they previously reported normalization of the cardiopulmonary function in teenagers patients at three years following surgical repair [10].

There have been several Meta-analyses performed on cardiopulmonary changes after surgery with conflicting results. Malek et al. [39] included eight studies in their literature review and they reported significant improvement in cardiovascular function which increased by more than a half standard deviation after surgical repair of PE. Several parameters were used for assessing the cardiovascular function in these studies, such as the cardiac output, heart rate, stroke volume, ejection fraction, VO_2 max and O_2 Pulse. No evidence suggested publication bias or missing small studies with negative results in their Meta-analysis. Maagaard et al. [40] reported in their recent literature review that the majority of the articles that studied the exercise capacity showed an increase in the exercise capacity as shown either in the increased peak oxygen uptake or the oxygen pulse with only one study which showed a significant decrease. This could be explained by the short 3 month post-operative follow up period with decreased physical activity following repair. The wide variability in the included studies in terms of the surgical techniques, number/

Table 1: A summary of some published results of Adult PE patients with minimally invasive repair.

Author	Numbers of adult patients	Median age (y)	Male (%)	Median operative time (min)	Numbers of bars (%)	Median postoperative stay (days)	Complications n (%)
Pileegard [17]	52	37	44 (85)	60	1 (30), 2 (66), 3 (4)	4	Deep infection after re-operation caused by lateral bar dislocation 1 (2)
Jaroszewski et al. [15]	151[a]	Mean: 40.4	108 (71.5)	Mean*: 121	2 (55), 3 (44.4), 4 (0.7)	Mean*: 2010-2012: 5 2013-2015: 3.3	*Bar rotation 10 (6.6), readmission 6 (4), pleural effusion required thoracocentesis 6 (4), pneumothorax required chest tube insertion 1 (0.7), pulmonary embolism 1(0.7), bleeding required transfusion 1 (0.7), reoperation for bleeding 1 (0.7)
	115[b]	Mean: 23.7	88 (76.5)	Mean*: 111	1 (0.9), 2 (56.5), 3 (42.6)	Mean*: 2010-2012: 4 2013-2015: 3.1	*Bar rotation 2 (1.7), infection 1 (0.9), pleural effusion required thoracocentesis3 (2.6), pneumothorax required chest tube insertion 1 (0.9), reoperation for bleeding 2 (1.7)
Esteves et al. [20]	19	Mean: 22.5	12 (63)	Mean: 96.5	1 (95), 2 (5)	Mean: 6.1	0 (0)
Yoon et al. [21]	44	20	38 (86.4)	90	1 (63.8), 2 (36.2)	3	Reoperation to correct bar rotation 2 (4.5), and incomplete repair 1 (2.2). Pneumothorax required thoracostomy 2 (4.5), wound infection required surgical revision 2 (4.5). Pericarditis and pericardial effusion 1 (2.2),
Olbrecht et al. [22]	52	23	42 (80.8)	82	1 (94.2), 2 (5.8)	3	pneumothorax required tube thoracostomy 2 (3.9), superficial site infection 11 (21.6%); 3 of them (5.9) required surgical revision and 2 (3.9) required early bar removal, bar displacement required repair 4 (7.7), upper sternal depression required 2nd bar insertion 2 (3.9), development of pectus carinatum required repair 1 (1.9), recurrence of PE occur in 2 (3.9) patients none of them required repair
Schalamon et al. [23]	43	Mean: 22	39 (91)	Mean: 70	1 (81), 2 (19)	Mean: 9.3	Puncture of a pleural effusion 5 (12), pneumothorax required drainage 2 (5), bar displacement with no required repair 1 (2)
Hebra et al. [24]	30	Mean: 23	NR (75)	60% operative time: 1 to 2 hours	2 (16)	Mean: 6	Seroma (10%), bar displacement (6%),pneumothorax requiring tube thoracostomy (6%), superficial wound infection (3%), and stabilizer bar fracture (3%). Two patients required conversion to modified Ravitch repair.
Aronson et al. [25]	35	23	28 (80)	65	2 (3)	7	Pneumothorax 9 (26), wound abscess in 3 (9), and bar displacement 5 (14).
Cheng et al. [26]	96	Mean: 24.5	80 (83)	80	2 (22.9)	Mean: 7.2	Pleural effusion 1 (1) required needle thoracocentesis Pericardial effusion 1 (1) required pericardiocentesis and steroid 2 months postoperative, surgical revision for bar displacement 2 (2.6)

[a]151 patients, 30-72 years of age.
[b]115 patients, 18-29 years of age.
*Information on patients underwent minimally invasive repair of pectus excavatum.
NR: not reported

age of the patients, the measured endpoints, the follow up period and the absence of matched group in most of the studies should be taken into consideration [40]. All of these analyses supported the need for surgical repair of PE deformity and contradict what has been thought previously that PE is merely a cosmetic problem [41].

Indications for Surgical Intervention

A comprehensive history, physical examination and investigational studies should be done to rule out other potential causes that might contribute to the patients' symptoms, and to evaluate the necessity of surgical repair. More common symptoms of exercise intolerance, dyspnea with exertion and chest pain in adult patient with PE can be caused by a number of serious medical conditions that must be ruled out in the differential. In adults of advanced age, investigation for coronary disease may be prudent. Diagnostic studies include echocardiography, electrocardiography, cardiopulmonary exercise testing (CPET) and computerized tomography (CT) scan or magnetic resonance imaging (MRI) [28,42]. The severity index or Haller index is measured by dividing the maximum internal width of the chest by the distance between the sternum posteriorly and vertebral body anteriorly [43]. It is recommended to assess the deformity both in the inspiratory and the expiratory views, as when patient exhales the chest becomes more compressed and the deformity becomes more evident [44]. Another measurement has been used to assess the severity of pectus deformity, the correction index;which estimates the percentage of correction necessary to normalize the chest wall and may be a more valid assessment in patients whose chest is barrel in shape and their Haller Index subsequently is falsely low [45,46]. It

is measured by calculating the distance between the spine anteriorly and most anterior internal rib (b) at its maximum point from the least distance between the spine anteriorly and the sternum posteriorly (a). The used equation is (b-a)/b × 100 [45,46]. Typical surgical candidates are symptomatic with evidence of cardiac compression on echocardiography or CT scan/MRIstudies, have abnormal CPET and Haller index >3.2 or correction index >10% [43,47].

Surgical Therapy

The Ravitch is an invasive procedure that has been used for PE repair for many decades. The procedure involves open resection of varying degrees to the deformed costal cartilages [48]. A number of modifications have been introduced to the Ravitch technique which included decreasing the amount of cartilages being resected, preserving theperichondrium, and the use of a metal strut or mesh posterior to the sternum for anterior support [18,49]. A minimally invasive repair approach to PE was introduced for children and adolescents in 1998 [50]. The Nuss procedure involved temporary placement of substernal support bar to elevate the deformity for a minimum of 2 years and removal of the bar as an outpatient procedure without the morbidity and long term consequences of cartilage resection [17,28].

MIRPE for Adult Patients

Although initially thought to be applicable to only young patients, a minimally invasive repair of pectus Excavatum (MIRPE) is being increasingly used for adult patients [13,15,17,19-26]. An MIRPE can be performed in the majority of adults with excellent results and success [15,17] (Table 1). Modifications to the Nuss procedure have been introduced to minimize the higher risks of complications that were initially published in adults [24,51,52]. These modifications included the use of forced sternal elevation to facilitate the introduction of the pectus support bars with less rotational force and allowance of better visualization across the mediastinum [53], use of multiple support bars to distribute the force needed for the chest elevation [15,52] and improved methods to secure the bars to prevent rotation [15,19,54,55]. Pilegaard [55] recommended the use of a shorter bar and amulti-point fixation technique has also been used by Park et al. [52]. In our clinical practice, the use of multipoint Fiber Wire fixation of the bars bilaterally and reinforcement of the interspaces to avoid intercostal muscle stripping has greatly reduced the incidence of bar rotations [15,54].

Others have noted that multiple bars help balance the increased pressure of supporting the adult chest wall [52,56,57]. Several studies have shown increased need for multiple bars in older patients, 70% in patients over 30 years required 2 or more bars as reported by Pilegaard [17]. In our own practice, we utilized 2 or more bars in over 99% of patients over age 18 [15]. Some surgeons have advocated the Ravitch in older patients [18,49]. In our experience, over 88% of the patients over 30 years were successfully repaired with MIRPE however some required a hybrid procedure (described to follow) in which addition to pectus support bars, an open resection for fracture or osteotomy was needed to achieve adequate repair [15]. The length of hospital stay has been reasonable with most series reporting 3-9 days of hospitalization and a low percentage of complications (Table 1) [15,17]. Achieving adequate postoperative analgesia is one of the concerns after Nuss procedure especially in adult patients. Thoracic epidural, intravenous on demand patient administrated narcotics, and subcutaneous continuous flow catheters and local blocks have all been reported

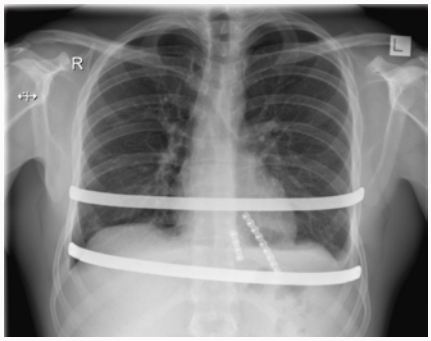

Figure 3: Posteroanterior chest roentgenogram shows titanium plating and sternal support bars were used after hybrid surgical repair.

[58-62]. For our patients, a standardized polypharmacy protocol is followed with good results [15,58] and includes gabapentin, non-steroidal, local subcutaneous catheter delivery and narcotics [58].

Open Hybrid Repair for Complex, Difficult Adult Patients

Asymmetric, calcified and complex deformities may require an open procedure for cartilage resection, osteotomy or repair of fractures with attempted elevation. A hybrid procedure incorporating both principals of osteotomy cuts and pectus support bars may also be considered and is our procedure of choice for these difficult deformities [15] (Figure 3). With age, the chest wall becomes less compliant and the force needed to elevate the deformity is increased [63]. Failure to elevate the sternum or its fracture during attempt elevation usually necessitates the use of an open procedure to correct the defect adequately [15,64]. Patients with severe recurrent deformities, extensive ossification and/or chest wall rigidity or defect severity that prevented elevation underwent a hybrid repair at our institution [65,66]. Extensive and more complex repair is associated with an increase in complications and length of hospital stay [15]. A recently published meta-analysis compared between the Ravitch and the Nuss procedures though it reported a higher complication rate, mostly early complications, in the adult patients underwent Nuss repair, only 90 adult patients were included in the analysis and they emphasized the importance of the availability of long term data to better compare the two procedures [67].

Patient should be counseled about the different surgical approaches for pectus repair. Age increases the difficulty of the repair and surgeon experience with complex cases and older patients is critical to successful outcomes [51,68-70].

Adult Female Patients and Implants

PE is generally thought to be more common in men than women [71]. There are few publications that focused primarily on the PE repair in female patients [72-74]. Breast development can often conceal the PE deformity additionally some women have implants placed to mask their deformity. Symptoms from limitation of cardiopulmonary function may develop in later years. Augmentation together with correction of the chest wall deformity can be performed without significant complications and should be considered in patients who desire so [72,75].

Conclusion

Adult patients may present with new onset or worsening

symptoms from their pectus excavatum. Complete preoperative investigation should be performed to rule out other causes and surgery is offered if medically indicated. Surgical repair has been shown to relieve symptoms and improve cardiopulmonary function in adult patients after repair. Both open and minimally invasive techniques are options. Both patient choice as well as surgeon expertise should be considered in determining the best option for every individual patient repair.

References

1. Scherer LR, Arn PH, Dressel DA, Pyeritz RM, Haller JA Jr. Surgical management of children and young adults with Marfan syndrome and pectus excavatum. J Pediatr Surg. 1988;23(12):1169-72.
2. Cobben JM, Oostra RJ, van Dijk FS. Pectus excavatum and carinatum. Eur J Med Genet. 2014;57(8):414-7.
3. Chung CS, Myrianthopoulos NC. Factors affecting risks of congenital malformations. I. Analysis of epidemiologic factors in congenital malformations. Report from the Collaborative Perinatal Project. Birth Defects Orig Artic Ser. 1975;11(10):1-22.
4. Chao CJ, Jaroszewski DE, Kumar PN, Ewais MM, Appleton CP, Mookadam F, et al. Surgical repair of pectus excavatum relieves right heart chamber compression and improves cardiac output in adult patients-an intraoperative transesophageal echocardiographic study. Am J Surg. 2015;210(6):1118-24.
5. Kelly RE, Mellins RB, Shamberger RC, Mitchell KK, Lawson ML, Oldham KT, et al. Multicenter study of pectus excavatum, final report: complications, static/exercise pulmonary function and anatomic outcomes. J Am Coll Surg. 2013;217(6):1080-9.
6. Sigalet DL, Montgomery M, Harder J, Wong V, Kravarusic D, Alassiri A. Long term cardiopulmonary effects of closed repair of pectus excavatum. Pediatr Surg Int. 2007;23(5):493-97.
7. Jaroszewski DE, Fonkalsrud EW. Repair of pectus chest deformities in 320 adult patients: 21 year experience. Ann Thorac Surg. 2007;84(2):429-33.
8. Lawson ML, Mellins RB, Paulson JF, Shamberger RC, Oldham K, Azizkhan RG, et al. Increasing severity of pectus excavatum is associated with reduced pulmonary function. J Pediatr. 2011;159(2):256-61.
9. Neviere R, Montaigne D, Benhamed L, Catto M, Edme JL, Matran R, et al. Cardiopulmonary response following surgical repair of pectus excavatum in adult patients. Eur J Cardiothorac Surg. 2011;40(2):e77-82.
10. Maagaard M, Tang M, Ringgaard S, Nielsen HH, Frøkiær J, Haubuf M, et al. Normalized cardiopulmonary exercise function in patients with pectus excavatum three years after operation. Ann Thorac Surg. 2013;96(1):272-8.
11. Tang M, Nielsen HH, Lesbo M, Frøkiær J, Maagaard M, Pilegaard HK, et al. Improved cardiopulmonary exercise function after modified Nuss operation for pectus excavatum. Eur J Cardiothorac Surg. 2012;41(5):1063-7.
12. Haller JA Jr, Loughlin GM. Cardiorespiratory function is significantly improved following corrective surgery for severe pectus excavatum. Proposed treatment guidelines. J CardiovascSurg (Torino). 2000;41(1):125-30.
13. Krasopoulos G, Dusmet M, Ladas G, Goldstraw P. Nuss procedure improves the quality of life in young male adults with pectus excavatum deformity. Eur J Cardiothorac Surg. 2006;29(1):1-5.
14. Koumbourlis AC. Pectus excavatum: pathophysiology and clinical characteristics. PaediatrRespir Rev. 2009;10(1):3-6.
15. Jaroszewski DE, Ewais MM, Chao CJ, Gotway MB, Lackey JJ, Myers KM, et al. Success of Minimally Invasive Pectus Excavatum Procedures (Modified Nuss) in Adult Patients (>/=30 Years). Ann Thorac Surg. 2016; 7.
16. Kragten HA, Siebenga J, Hoppener PF, Verburg R, Visker N. Symptomatic pectus excavatum in seniors (SPES): a cardiovascular problem? A prospective cardiological study of 42 senior patients with a symptomatic pectus excavatum. Neth Heart J. 2011;19(2):73-8.
17. Pilegaard HK. Extending the use of Nuss procedure in patients older than 30 years. Eur J Cardiothorac Surg. 2011;40(2):334-7.
18. Fonkalsrud EW. Open repair of pectus excavatum with minimal cartilage resection. Ann Surg. 2004;240(2):231-5.
19. Park HJ, Jeong JY, Jo WM, Shin JS, Lee IS, Kim KT, et al. Minimally invasive repair of pectus excavatum: a novel morphology-tailored, patient-specific approach. J ThoracCardiovasc Surg. 2010;139(2):379-86.
20. Esteves E, Paiva KC, Calcagno-Silva M, Chagas CC, Barbosa-Filho H. Treatment of pectus excavatum in patients over 20 years of age. J LaparoendoscAdvSurg Tech A. 2011;21(1):93-6.
21. Yoon YS, Kim HK, Choi YS, Kim K, Shim YM, Kim J. A modified Nuss procedure for late adolescent and adult pectus excavatum. World J Surg. 2010;34(7):1475-80.
22. Olbrecht VA, Arnold MA, Nabaweesi R, Chang DC, McIltrot KH, Abdullah F, et al. Lorenz bar repair of pectus excavatum in the adult population: should it be done? Ann Thorac Surg. 2008;86(2):402-8; discussion 8-9.
23. Schalamon J, Pokall S, Windhaber J, Hoellwarth ME. Minimally invasive correction of pectus excavatum in adult patients. J ThoracCardiovasc Surg. 2006;132(3):524-9.
24. Hebra A, Jacobs JP, Feliz A, Arenas J, Moore CB, Larson S. Minimally invasive repair of pectus excavatum in adult patients. Am Surg. 2006;72(9):837-42.
25. Aronson DC, Bosgraaf RP, van der Horst C, Ekkelkamp S. Nuss procedure: pediatric surgical solution for adults with pectus excavatum. World J Surg. 2007;31(1):26-9.
26. Cheng YL, Lee SC, Huang TW, Wu CT. Efficacy and safety of modified bilateral thoracoscopy-assisted Nuss procedure in adult patients with pectus excavatum. Eur J Cardiothorac Surg. 2008;34(5):1057-61.
27. Colombani PM. Preoperative assessment of chest wall deformities. SeminThoracCardiovasc Surg. 2009;21(1):58-63.
28. Jaroszewski D, Notrica D, McMahon L, Steidley DE, Deschamps C. Current management of pectus excavatum: a review and update of therapy and treatment recommendations. J Am Board Fam Med. 2010;23(2):230-9.
29. Coln E, Carrasco J, Coln D. Demonstrating relief of cardiac compression with the Nuss minimally invasive repair for pectus excavatum. J Pediatr Surg. 2006;41(4):683-6.
30. Kelly RE Jr, Shamberger RC, Mellins RB, Mitchell KK, Lawson ML, Oldham K, et al. Prospective multicenter study of surgical correction of pectus excavatum: design, perioperative complications, pain, and baseline pulmonary function facilitated by internet-based data collection. J Am Coll Surg. 2007 Aug;205(2):205-16.
31. Kotzot D, Schwabegger AH. Etiology of chest wall deformities--a genetic review for the treating physician. J Pediatr Surg. 2009;44(10):2004-11.
32. Gürkan U, Aydemir B, Aksoy S, Akgöz H, Tosu AR1, Öz D, et al. Echocardiographic assessment of right ventricular function before and after surgery in patients with pectus excavatum and right ventricular compression. ThoracCardiovasc Surg. 2014;62(3):231-5.
33. Malek MH, Fonkalsrud EW, Cooper CB. Ventilatory and cardiovascular responses to exercise in patients with pectus excavatum. Chest. 2003;124(3):870-82.
34. Mocchegiani R, Badano L, Lestuzzi C, Nicolosi GL, Zanuttini D. Relation of right ventricular morphology and function in pectus excavatum to the severity of the chest wall deformity. Am J Cardiol. 1995;76(12):941-6.
35. Albouaini K, Egred M, Alahmar A, Wright DJ. Cardiopulmonary exercise testing and its application. Heart. 2007;93(10):1285-92.

36. Malek MH, Coburn JW. Strategies for cardiopulmonary exercise testing of pectus excavatum patients. Clinics (Sao Paulo). 2008;63(2):245-54.

37. Perhonen MA, Franco F, Lane LD, Buckey JC, Blomqvist CG, Zerwekh JE, et al. Cardiac atrophy after bed rest and spaceflight. J ApplPhysiol (1985). 2001;91(2):645-53.

38. Udholm S, Maagaard M, Pilegaard H, Hjortdal V. Cardiac function in adults following minimally invasive repair of pectus excavatum. Interact CardiovascThorac Surg. 2016;22(5):525-9.

39. Malek MH, Berger DE, Housh TJ, Marelich WD, Coburn JW, Beck TW. Cardiovascular function following surgical repair of pectus excavatum: a metaanalysis. Chest. 2006;130(2):506-16.

40. Maagaard M, Heiberg J. Improved cardiac function and exercise capacity following correction of pectus excavatum: a review of current literature. Ann Cardiothorac Surg. 2016;5(5):485-92.

41. Kelly RE Jr, Cash TF, Shamberger RC, Mitchell KK, Mellins RB, Lawson ML, et al. Surgical repair of pectus excavatum markedly improves body image and perceived ability for physical activity: multicenter study. Pediatrics. 2008 Dec;122(6):1218-22.

42. Kelly RE Jr. Pectus excavatum: historical background, clinical picture, preoperative evaluation and criteria for operation. SeminPediatr Surg. 2008 Aug;17(3):181-93.

43. Haller JA Jr, Kramer SS, Lietman SA. Use of CT scans in selection of patients for pectus excavatum surgery: a preliminary report. J Pediatr Surg. 1987;22(10):904-6.

44. Raichura N, Entwisle J, Leverment J, Beardsmore CS. Breath-hold MRI in evaluating patients with pectus excavatum. Br J Radiol. 2001;74(884):701-8.

45. Sarwar ZU, DeFlorio R, O'Connor SC. Pectus excavatum: current imaging techniques and opportunities for dose reduction. Semin Ultrasound CT MR. 2014;35(4):374-81.

46. Poston PM, Patel SS, Rajput M, Rossi NO, Ghanamah MS, Davis JE, et al. The correction index: setting the standard for recommending operative repair of pectus excavatum. Ann Thorac Surg. 2014;97(4):1176-79.

47. Daunt SW, Cohen JH, Miller SF. Age-related normal ranges for the Haller index in children. Pediatr Radiol. 2004;34(4):326-30.

48. Ravitch MM. The Operative Treatment of Pectus Excavatum. Ann Surg. 1949;129(4):429-44.

49. Hamaji M, Hiraoka K, Jaroszewski DE, Deschamps C. Modified Robicsek procedure for pectus excavatum in adult patients. Interact CardiovascThorac Surg. 2014;18(5):611-4.

50. Nuss D, Kelly RE Jr, Croitoru DP, Katz ME. A 10-year review of a minimally invasive technique for the correction of pectus excavatum. J Pediatr Surg. 1998;33(4):545-52.

51. Molik KA, Engum SA, Rescorla FJ, West KW, Scherer LR, Grosfeld JL. Pectus excavatum repair: experience with standard and minimal invasive techniques. J Pediatr Surg. 2001;36(2):324-8.

52. Park HJ, Lee SY, Lee CS, Youm W, Lee KR. The Nuss procedure for pectus excavatum: evolution of techniques and early results on 322 patients. Ann Thorac Surg. 2004;77(1):289-95.

53. Jaroszewski DE, Johnson K, McMahon L, Notrica D. Sternal elevation before passing bars: a technique for improving visualization and facilitating minimally invasive pectus excavatum repair in adult patients. J Thorac Cardiovasc Surg. 2014;147(3):1093-5.

54. McMahon LE, Johnson KN, Jaroszewski DE, Acosta JM, Egan JC, Bae J, et al. Experience with Fiber Wire for pectus bar attachment. J Pediatr Surg. 2014;49(8):1259-63.

55. Pilegaard HK. Nuss technique in pectus excavatum: a mono-institutional experience. J Thorac Dis. 2015;7(Suppl 2):S172-6.

56. Pilegaard HK, Licht PB. Routine use of minimally invasive surgery for pectus excavatum in adults. Ann Thorac Surg. 2008;86(3):952-6.

57. Stanfill AB, DiSomma N, Henriques SM, Wallace LJ, Vegunta RK, Pearl RH. Nuss procedure: decrease in bar movement requiring reoperation with primary placement of two bars. J Laparoendosc Adv Surg Tech A. 2012;22(4):412-5.

58. Jaroszewski DE, Temkit M, Ewais MM, Luckritz TC, Stearns JD, Craner RC, et al. Randomized trial of epidural vs. subcutaneous catheters for managing pain after modified Nuss in adults. J Thorac Dis. 2016;8(8):2102-10.

59. Gebhardt R, Mehran RJ, Soliz J, Cata JP, Smallwood AK, Feeley TW. Epidural versus ON-Q local anesthetic-infiltrating catheter for post-thoracotomy pain control. J Cardiothorac Vasc Anesth. 2013;27(3):423-6.

60. Ried M, Schilling C, Potzger T, Ittner KP, Rupp A, Szoke T, et al. Prospective, comparative study of the On-Q(R) PainBuster(R) postoperative pain relief system and thoracic epidural analgesia after thoracic surgery. J CardiothoracVascAnesth. 2014;28(4):985-90.

61. Weber T, Mätzl J, Rokitansky A, Klimscha W, Neumann K, Deusch E; Medical Research Society. Superior postoperative pain relief with thoracic epidural analgesia versus intravenous patient-controlled analgesia after minimally invasive pectus excavatum repair. J ThoracCardiovasc Surg. 2007;134(4):865-70.

62. Futagawa K, Suwa I, Okuda T, Kamamoto H, Sugiura J, Kajikawa R, et al. Anesthetic management for the minimally invasive Nuss procedure in 21 patients with pectus excavatum. J Anesth. 2006;20(1):48-50.

63. Fonkalsrud EW, Reemtsen B. Force required to elevate the sternum of pectus excavatum patients. J Am Coll Surg. 2002;195(4):575-7.

64. Fonkalsrud EW. 912 open pectus excavatum repairs: changing trends, lessons learned: one surgeon's experience. World J Surg. 2009;33(2):180-90.

65. Johnson KN, Jaroszewski DE, Ewais M, Lackey JJ, McMahon L, Notrica DM. Hybrid Technique for Repair of Recurrent Pectus Excavatum After Failed Open Repair. Ann Thorac Surg. 2015;99(6):1936-43.

66. Jaroszewski DE, Notrica DM, McMahon LE, Hakim FA, Lackey JJ, Gruden JF, et al. Operative management of acquired thoracic dystrophy in adults after open pectus excavatum repair. Ann Thorac Surg. 2014;97(5):1764-70.

67. Kanagaratnam A, Phan S, Tchantchaleishvili V, Phan K. Ravitch versus Nuss procedure for pectus excavatum: systematic review and meta-analysis. Ann Cardiothorac Surg. 2016;5(5):409-21.

68. Kim DH, Hwang JJ, Lee MK, Lee DY, Paik HC. Analysis of the Nuss procedure for pectus excavatum in different age groups. Ann Thorac Surg. 2005;80(3):1073-7.

69. Papic JC, Finnell SM, Howenstein AM, Breckler F, Leys CM. Postoperative opioid analgesic use after Nuss versus Ravitch pectus excavatum repair. J Pediatr Surg. 2014;49(6):919-23.

70. Antonoff MB, Erickson AE, Hess DJ, Acton RD, Saltzman DA. When patients choose: comparison of Nuss, Ravitch, and Leonard procedures for primary repair of pectus excavatum. J Pediatr Surg. 2009;44(6):1113-8;discussion 118-9.

71. Shamberger RC. Congenital chest wall deformities. CurrProbl Surg. 1996;33(6):469-542.

72. Ma IT, Rebecca AM, Notrica DM, McMahon LE, Jaroszewski DE. Pectus excavatum in adult women: repair and the impact of prior or concurrent breast augmentation. PlastReconstr Surg. 2015;135(2):303e-12e.

73. Fonkalsrud EW. Management of pectus chest deformities in female patients. Am J Surg. 2004;187(2):192-7.

74. Fang FC, Cheng YL, Lee SC, Chen JC, Hsu HH, Tzao C. Clinical experience of Nuss procedure for pectus excavatum in adult female patients. ThoracCardiovasc Surg. 2008;56(5):283-6.

75. Park HJ, Gu JH, Jang JC, Dhong ES, Yoon ES. Correction of pectus excavatum with breast hypoplasia using simultaneous pectus bar procedure and augmentation mammoplasty. Ann Plast Surg. 2014;73(2):190-5.