Clinics in Surgery

Research Article
Published: 16 Jul, 2021

# Etio-Histomorphogenesis of Styloid enlargement - A Novel & Extensive Light Microscopic Analysis of Ten cases of Eagle's Syndrome

*Colonel Priya Jeyaraj**

*Department of Oral & Maxillofacial Surgery, Commanding Officer 33 Corps Dental Unit and Corps Dental Adviser 33 Corps, Indian Army, India*

## Abstract

**Aim & Objectives:** To carry out detailed light microscopic analysis of excised specimen of Elongated Styloid Processes (ESPs) from patients suffering from Eagle's Syndrome (ES). To thus gain a clear and precise insight into the etiology, origin, development and progression of styloid enlargement, and to accurately hypothesize the underlying histopathological mechanisms bringing about their thickening and elongation.

**Study Design & Setting:** This three-year study was conducted in ten patients of ES, who were treated by transoral styloidectomy. The excised ESPs were subjected to a systematic and comprehensive histological analysis of sections from their base, mid and apical thirds.

**Material & Methods:** Imaging and diagnostic workup, operative procedure, post-surgical protocols & regimen, tissue processing & analysis of excised specimen were the same in all patients.

**Results:** Immature woven bone trabecula and dystrophic calcifications were found within fibro-collagenous mesenchymal condensations of the Stylohyoid Ligament (SL) at the apical region of the ESPs, and in the tendinous insertions of the styloid group of muscles into the ESPs, indicative of their osseous metaplasia as a form of reactive response.

**Conclusion:** Repetitive stress, traction or traumatic stimuli brought to bear upon the apices and lateral surfaces of styloid processes via tendinous insertions of the SL and styloid group of muscles, as a result of neck and hyoid movements, are likely to serve as triggering factors, stimulating an osseous metaplasia of connective cells within these mesenchymal structures as well as in the periosteal fibrous tissue, into osteoblasts and osteocytes. This reactive response is followed by osteogenesis and laying down of woven bone at these sites, resulting in increase in length and circumference of the SPs and their attendant, associated clinical sequela.

**Keywords: Eagle's Syndrome (ES); Styloid Ligament (SL); Osseous metaplasia; Styloid enlargement; Elongated Styloid Process (ESP)**

**OPEN ACCESS**

***Correspondence:**
*Colonel Priya Jeyaraj, Department of Oral & Maxillofacial Surgery, Commanding Officer 33 Corps Dental Unit and Corps Dental Adviser 33 Corps, Indian Army, India, Tel: (91)9596840303;*
*E-mail: jeyarajpriya@yahoo.com*

**Received Date**: *24 Jun 2021*
**Accepted Date***: 13 Jul 2021*
**Published Date***: 16 Jul 2021*

***Citation:***
*Jeyaraj CP. Etio-Histomorphogenesis of Styloid enlargement - A Novel & Extensive Light Microscopic Analysis of Ten cases of Eagle's Syndrome. Clin Surg. 2021; 6: 3254.*



## Introduction

Uni- or Bilaterally Elongated Styloid Processes (ESPs) are known to cause impingement of neurovascular structures in their immediate vicinity, leading to a clinico-pathological condition commonly referred to as the Eagle's Syndrome. The condition comprises of a symptom complex of vague myofascial, oropharyngeal, craniofacial or cervical pain, TMJ disorders, tinnitus, hyper salivation, foreign body sensation in the throat, dysphagia, change in voice, recurrent syncope and so on [1,2].

Literature is replete with descriptive reports on the clinical presentations and manifestations of Eagle's syndrome, radiographic characteristics of the Elongated Styloid Processes (ESPs) [3], as well as the different extraoral and transoral surgical approaches and techniques of performing Styloidectomy [4-6]. However, there is practically nil documentation on the etiomorphogenesis of this condition and a stark lacuna on the histopathological analysis of excised ESPs. There exists a pronounced lack of understanding and explanation as to the precise underlying cause, predisposing or triggering factors, origin and development/progress of the abnormal elongation, thickening, ossification and deformity of the styloid apparatus/stylohyoid complex.

There is felt a need to examine in detail the light microscopic features of ESPs from various

different patients suffering from Eagle's syndrome, to gain a better understanding and a deeper and clearer insight as to the probable triggering and predisposing factors leading to mineralization/ ossification of the stylohyoid apparatus bringing about abnormal styloid enlargement in these cases, and to thus accurately hypothesize the etio-histomorphogenesis of this ambiguous condition.

This painstaking, thorough and comprehensive clinical and histopathological study was carried out over a period of three years to examine and analyze in detail, the histological features of different parts of excised ESPs from ten different patients diagnosed with ES, with the aim to gain a better understanding and more accurate insight into their development and etiopathogenesis. Sections from the basal, mid and apical thirds of the surgically excised ESPs along with portions of their overlying periosteal fibrous tissue membrane were subjected to a meticulous and detailed light microscopic examination. The histopathological findings were analyzed and comprehensively interpreted to arrive at the most precise hypothesis explaining the etio-histomorphogenesis of ESPs, which hitherto has remained obscure and ambiguous.

## Aim

To determine the etiopathogenesis and histomorphogenesis of styloid process enlargement in patients diagnosed with ES and to examine probable triggering and predisposing factors bringing about this morphological anomaly, with its attendant clinical sequela.

## Objectives

(i) To carry out a detailed light microscopic study and analysis of the osseous, cartilaginous, periosteal, and fibrous connective tissue components found in the different levels and portions of excised ESPs (basal, mid and apical thirds), from ten different patients suffering from Eagle's syndrome.

(ii) To analyze the histopathological data and information so obtained, to hypothesize probable mechanisms of development and progression of styloid enlargement, and to gain information on their origin and likely etiopathogenesis.

(iii) To examine and explore the role of possible triggering factors and predisposing conditions which can lead to hyperplasia or osseous metaplasia of the periosteal fibrous tissue membrane overlying the SPs, the mesenchyme of the stylohyoid ligament and tendinous insertions of the styloid group of muscles into the SPs, thereby bringing about styloid elongation and thickening.

## Study Design and Setting

In this study which was carried out over a period of three years, ten patients (seven Males and three Females), were diagnosed with and treated for Eagle's Syndrome. Six of these patients exhibited bilateral elongation, while four had unilateral elongation of the styloid processes. The lengths of the ESPs ranged from 43 mm to 74 mm. All the cases were managed by Intraoral Styloidectomy (bilateral/ unilateral as the case dictated), carried out by a single operator. Follow up ranged from ten to twenty-nine months.

Imaging and diagnostic work up, operative procedure, post-surgical regimen and protocols, tissue processing & histopathological analysis of the excised specimen of ESPs carried out in all the ten cases, were the same. All the 16 excised ESPs were subjected to a detailed light microscopic analysis. Histopathological presentation of sections from different levels (apical, mid and basal thirds) of the excised ESPs from six patients, have been illustrated and elaborated in detail (Figures 2-7). An in depth, systematic analysis and comprehensive interpretation of the light microscopic findings was carried out in all the ten cases.

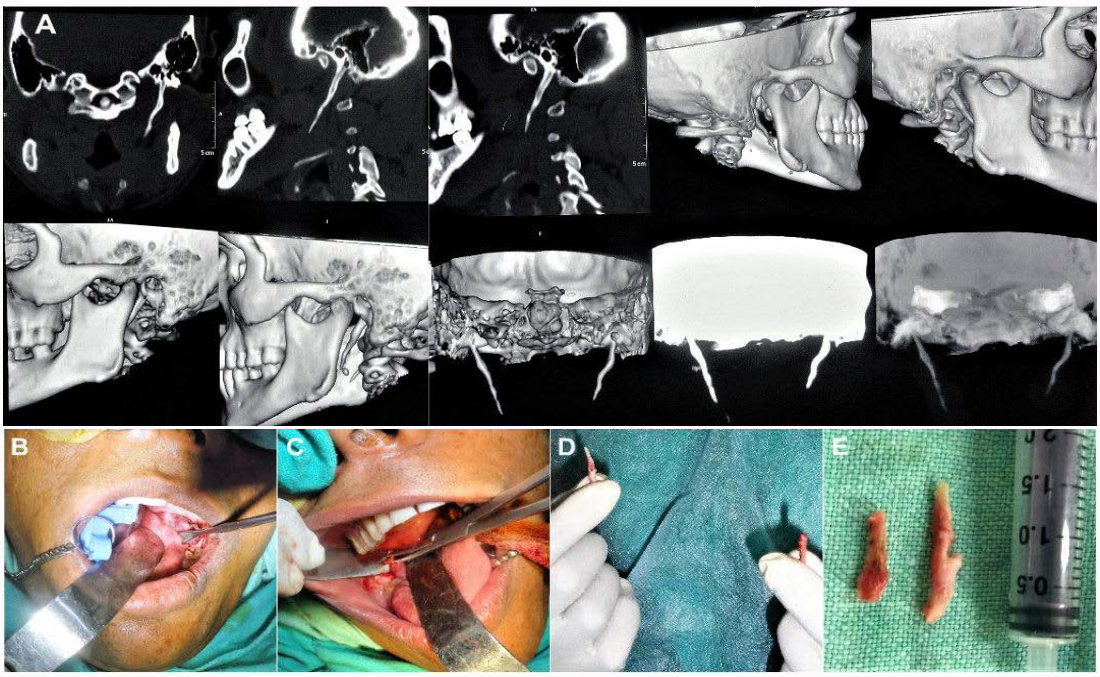


**Figure 1:** (A) Contrast Enhanced Computed Tomography (CECT) scans of the Craniomaxillofacial region in a 45-year-old male with Eagle's Syndrome - Coronal and Sagittal sections and 3D-reformatted images, showed bilaterally elongated styloid processes. The Right ESP was longer and was relatively straight, while the Left ESP was comparatively wavy and tortuous. Both ESPs were directed caudally & anteriorly, and were medially inclined. (B-E) Bilateral styloidectomy performed via a transoral approach. (B) Dissection of the tonsillar bed exposing the ESP. (C) Degloving of the ESP, which was then dissected free of its muscle, ligamentous & tendinous insertions, followed by transection at its base. (D, E) Excised ESPs. The Right ESP measured 63 mm, while the Left ESP measured 45mm.

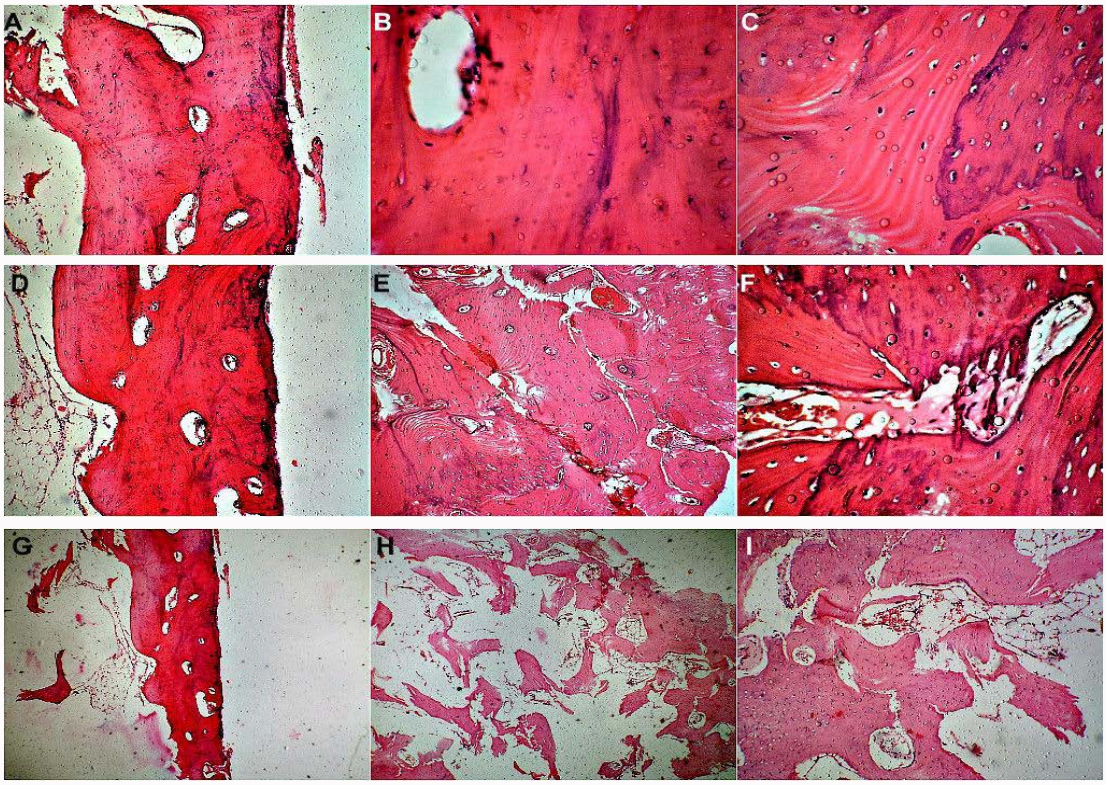


**Figure 2:** (Case 1) (A-C) Haematoxylin and eosin-stained sections at x50 and x150 magnifications of Basal third of the Excised ESP (B) H&E x150. Basal third was composed of compact bone with sparse marrow spaces. There was seen well calcified and mature trabecular bone, with a well-defined lamellar structure. Osteocytes appeared as elongated, elliptical-shaped cells, having long axes that were parallel to the lamellae within which they lay. (C) H&E x150. In the lower region, as the junction with the mid-third of the ESP was approached, the trabecular arrangement showed a distinct change, appearing wavier and more fibrous, resembling woven bone. The bone appeared to be composed of composites of woven and lamellar bone (fibro-lamellar). Numerous plump osteoblasts were seen within the trabecula. Wavy, deeply basophilic reversal lines could be seen, indicating recurrent periods of osteogenic activity alternating with periods of quiescence. (D-F) Hematoxylin and eosin-stained sections at x50 and x150 magnifications of mid third of the Excised ESPs. (E) H&E x150. Surface of the excised ESP was covered by a scanty fibrous layer of periosteum membrane. Deeper layers of the bony process were composed of mature lamellar bone, while the outer layers were composed of irregular, broad, undulating trabecula of immature woven bone. (F) H&E x150. Medial aspect of the mid third section of the styloid processes, showed angulated insertions of tendon fibres, of the stylohyoid and stylopharyngeus muscles. The tendon fibres of the muscles entered the fibrous bone here, and crossed the irregular calcification zones in a slanted direction. (G-I) Haematoxylin and eosin-stained sections at x50, x100 and x150 of Apical third of the Excised ESP. (H) H&E x100. Tissue specimen of the tip of the apex of the ESPs showed numerous disjointed islets and irregular flecks of woven bone interspersed with fibrovascular and richly collagenous connective tissue stroma. The osteophytic bone deposition in the apical ends of the styloid processes was irregular and dystrophic in its calcification. Many of the haphazardly scattered trabecula seemed to traverse and emerge from the surrounding fibrous background, suggesting a 'metaplastic' process. (I) H&E x150. Immature woven bone with a few vascular spaces, and an overlying fibro-collagenous connective tissue containing a moderate number of fusiform, spindle-shaped fibroblasts and scattered hemosiderin deposits. Evidence of osseous metaplasia taking place within the fibro-collagenous connective tissue, with numerous plumps, spindle-shaped osteoblasts observed within the developing trabecula of woven bone. There was no evidence of a cartilaginous cap at the apex.

## Material and Methods

**Clearance from the Institutional Ethical committee** (MDC (GL), Secunderabad, IA EC No. 53341/OS/13, dt 15 Jan 2018) was obtained prior to commencing this study.

### Clinical presentation

Ages of the ten patients who reported for treatment, ranged from 41 to 55 years. They presented with complaints of longstanding, chronic, vague pain in the posterior pharyngeal and/or submandibular regions, with exacerbation of the pain upon speaking, chewing, swallowing, yawning and on turning the head from side to side. The pain was bilateral in six patients and unilateral in the remaining four. The pain often radiated to the ears, temporomandibular joints and sides of the forehead. The duration of the symptoms experienced by the patients ranged from twelve months to twenty months, with an average of sixteen months. Many of them often experienced a foreign body sensation in the throat, accompanied by occasional difficulty in swallowing. None of the ten patients gave a previous history of tonsillectomy or trauma to the head and neck region.

Upon extraoral examination, all the ten patients exhibited varying degrees of tenderness on palpation of the submandibular region's uni- or bilaterally. None of these patients presented with any evidence of dental, periapical or periodontal pathology. Upon transoral oropharyngeal palpation of the tonsillar fossa regions, the tips of the styloid processes were palpable, and there was an immediate exacerbation of pain elicited in the region, which helped in reaching a conclusive clinical diagnosis of ESPs and Eagle's syndrome in these cases.

### Imaging & diagnostic workup

Radiographic evaluation with the aid of Orthopantomogram (OPG) and Contrast Enhanced Computed Tomographic scans (CECT) of the craniomaxillofacial region corroborated the clinical findings of bilateral (in six patients) (Figure 1A). And unilateral (in

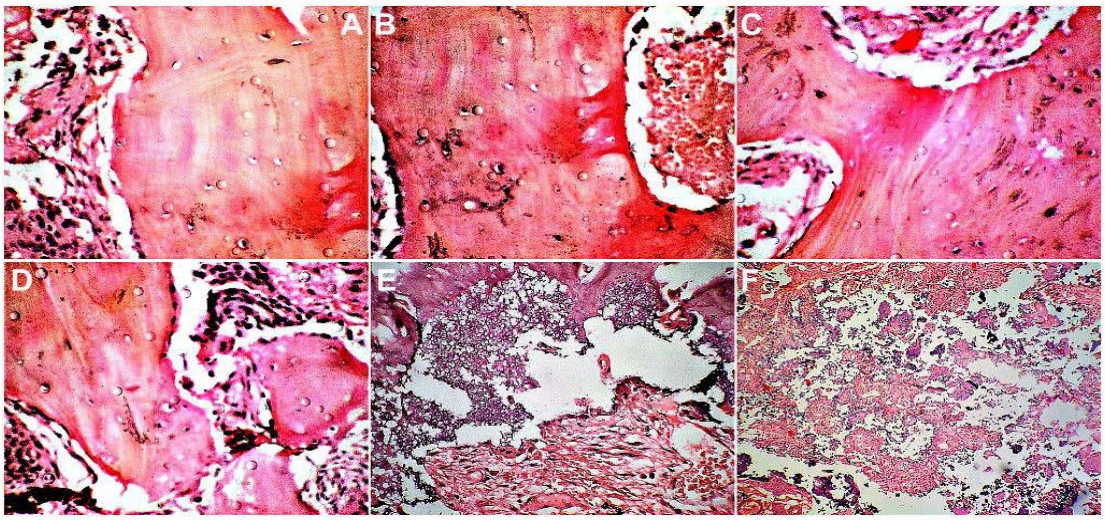


**Figure 3:** (Case 2) (A, B) H&E X 150. Basal third of the ESP, seen to be composed of well calcified and mature trabecular bone having a well-defined lamellar structure, covered by an overlying fibrous layer of periosteal membrane. (C, D) H&E x150. Bony trabecula at the mid-third of the styloid process appeared wavier and more fibrous, giving a fibro-lamellar appearance. Numerous plump osteoblasts are visible within the trabeculae. Also seen are the dense fibro-collagenous insertions of tendon fibres of the stylohyoid and stylopharyngeus muscles, crossing the partially remodeled immature woven bone. (E, F) H&E x50. Tissue specimen from the apex of the elongated styloid process showed numerous disjointed islets of woven bone interspersed with fibrovascular and richly collagenous connective tissue stroma. Haphazardly scattered trabeculae traversing and emerging/emanating from the surrounding fibrous background containing pluripotent cells are indicative of a 'metaplastic' process, inducing their osteoblastic transformation thus contributing to styloid elongation.

four patients) Elongated Styloid Processes (ESPs). The length of the ESPs ranged from 43 mm to 74 mm. All of the caudally growing processes demonstrated a medial and anterior inclination.

A diagnostic test for definitive confirmation of Eagle's syndrome (ES) was carried out by instilling 1 ml of 2% lignocaine into the anterior faucial pillar and the tonsillar fossa, one side at a time, for each patient. This resulted in an almost instantaneous relief from all the symptoms of ES, in particular, the local tenderness and pain.

Correlating history, clinical and radiographic features with the corroboratory diagnostic test, enabled establishing a definitive diagnosis of Eagle's syndrome associated with either unilateral or bilateral ESPs in all ten patients. The patients were then planned for uni/bilateral transoral styloidectomy.

## Operative procedure

All the patients were operated under General Anesthesia. Transoral approach was employed to expose and excise the elongated styloid processes (Figures 1B-1E). The incision placed in the tonsillar fossa, followed by dissection carried through the medial pterygoid and superior constrictor muscles (Figure 1B). The tonsillar bed was palpated for the bony protrusion of the tip of the styloid process and in those cases where the styloid process was deep set, tonsillectomy was carried out for better access and visibility. Of the ten patients treated, a tonsil sparing approach was employed in six cases, while in the remaining four; the tonsils were removed prior to sectioning the ESPs. In these four cases, the styloid processes were found to be more deep set and less easily accessible at the time of surgery. Removal of the tonsils aided in an easier dissection therein and a clearer visual field and access to more easily identify, strip and section the styloid processes.

Once the tip of the styloid process was identified, a Bard-Parker blade No. 11 was used to make a sharp incision through its overlying fascia and muscle attachments, facilitating their reflection from the ESP. The full length of the bony styloid process was exposed as proximally as possible, followed by its transection at its base (Figure 1C), taking care all along not to inadvertently fracture it. The procedure was completed on both sides in the cases of bilateral ESPs. The excised specimens (Figure 1D, 1E) were carefully placed in a container containing formalin and sent for histopathological examination. After ensuring adequate hemostasis, the tonsillar bed was sutured using Vicryl 3-0 sutures.

## Postoperative regimen & protocol

Postoperative recovery was smooth and uneventful in all the ten patients. A strict aseptic surgical technique, careful dissection and meticulous identification and cauterization of blood vessels in the surgical field during the operative procedure, ensured nil postoperative infection, and minimal postoperative edema and trismus.

Eight patients experienced an immediate and complete resolution of all symptoms following their awakening in the recovery unit, while the remaining two had relief from their symptoms within the first 3 days following surgery.

The patients were placed on a soft and cold diet for the first 24 h, and were administered Inj Omnatax 1 gm IV 8 hourly, Inj Flagyl 500 mg IV 8 hourly, Inj Wymesone 8 mg IV 12 hourly, Inj Voveran 50 mg IM 12 hourly, Tab Chymoral forte three times a day, and Multivitamin capsule once a day for three days. Thereafter, Intravenous (IV) medications were stopped and oral analgesics were advised for two days. The patients were encouraged to carry out warm saline rinses and gargling four times a day for a fortnight, which had a soothing fomentation effect on the throat, and also encouraged healing of the operated site. Physiotherapy in the form of active mouth opening exercises helped in preventing trismus from setting in. The patients were regularly followed up for ten to nineteen months thereafter, with no recurrence either clinically or radiographically of any of the features of ES.

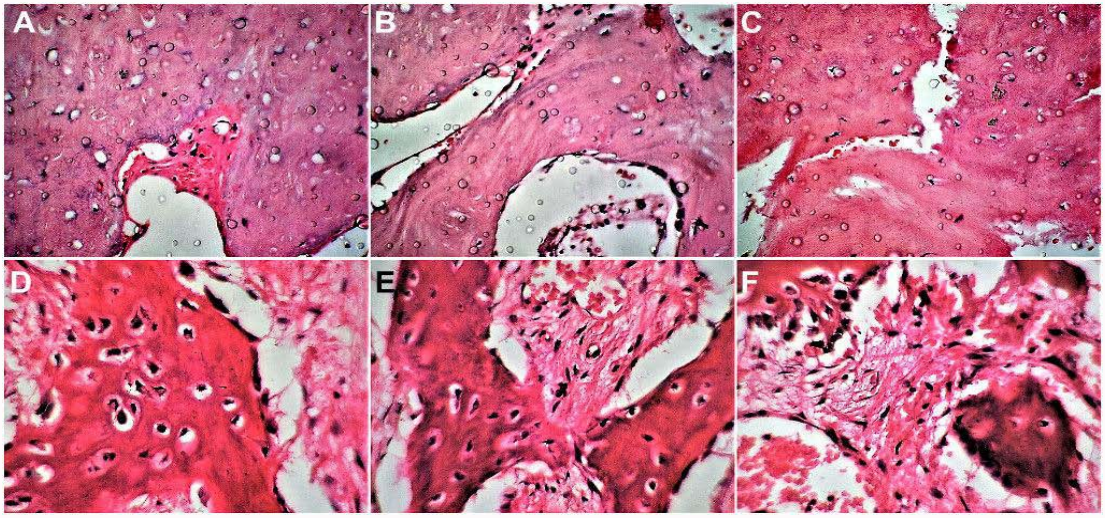


**Figure 4:** (Case 3) (A-C) H&E x150. Basal and mid-third of the ESP, showing developing trabeculae of fibro-lamellar bone with numerous osteoblasts and osteoblasts. A few fibro-collagenous insertions of styloid group of muscle are visible. (D-F) H&E x150. Abundant immature woven bone was seen at the mid and apical thirds of the SP, with numerous osteoblasts and osteocytes within, indicative of new, active bone formation. Woven bone trabeculae were also found emanating from the tendinous insertions of the stylopharyngeus and stylohyoid muscles at the medial regions of mid third of the ESPs indicative of a possible causative role of tensile stresses exerted at these muscle insertions in bringing about new bone formation. The most apical region showed fibro-collagenous mesenchymal tissue with developing trabecula of immature, woven bone which was indicative of osseous metaplasia of mesenchymal condensations of the Stylohyoid Ligament (SL) into osseous tissue.

### Processing & histopathological analysis of the excised specimen

All excised specimens of the ESPs were fixed in 10% neutral formalin, decalcified with 0.5 M EDTA solution (pH 8.0), and embedded in paraffin for further processing. Uniform sections of 15 µm thickness, were cut from the apical, mid and basal thirds of the styloid processes, and were stained with Hematoxylin and Eosin. Light microscopic study was carried out using a Nikon Eclipse E400 microscope and a Nikon DXM 1200 digital camera.

## Results

Histopathological examination and study of sections of the Basal, Mid and Apical thirds of the excised ESPs from the ten patients, revealed the following details:

### Basal third of the excised ESPs

This region was found to be composed of compact bone with sparse marrow spaces (Figures 2A-2C, 3A, 3B, 4A, 4B, 5A, 5D). A thin fibro-collagenous layer of periosteal membrane covered mature, well calcified trabecular bone showing a distinct ad well-defined lamellar structure, with a regular, parallel alignment of sheets of collagen (Figures 2A-2C, 3A, 3B). A few elongated, elliptical osteocytes were seen, having their long axes parallel to the lamellae within which they lay embedded in a mineralized matrix. In the lower regions of the basal third of the ESPs, as the junction with the mid-third was approached, the trabecular arrangement appeared wavier, resembling woven bone (Figures 2C, 5A, 5B). Composites of woven and lamellar bone gave a fibro-lamellar appearance in this region. Wavy, strongly basophilic reversal lines were seen, which were representative of recurrent periods of osteogenic activity alternating with periods of quiescence (Figure 2C).

### Mid third of the excised ESPs

A thin layer of periosteum covered the surface of the mid third of the ESPs (Figures 2D-2F, 3C, 3D, 4C, 4D, 5E-5H). Just beneath the periosteal layer, the bone was composed of broad irregular trabecula of immature woven bone with numerous large osteoblasts, osteocytes and haphazardly arranged collagen fibres. This was indicative of new active osteophytic bone deposition along the lateral surfaces of the ESPs. Deeper layers were composed of mature lamellar bone (Figures 2E, 2F, 4C, 5E-5H). The medial aspect of the mid third section of the styloid processes, showed angulated insertions of tendon fibres, of the stylohyoid and stylopharyngeus muscles (Figures 2F, 3C, 3D, 4D, 5G, 5H). These tendon fibres entered the fibrous bone here, and crossed the irregular calcification zones in a slanted direction. Numerous wavy, strongly basophilic reversal lines were seen, which were representative of recurrent periods of osteogenic activity alternating with periods of quiescence (Figures 5E-5H). This was indicative of interrupted attempts at bone repair and abnormal remodeling.

### Apical third of the excised ESPs

Tissue specimen from the apices of the excised ESPs (Figures 2G-2I, 3E, 3F, 4E, 4F, 5I-5L and 6, 7) showed richly collagenous fibrovascular connective tissue stroma containing numerous partially calcified osseous islets of immature woven bone. An abundance of plump osteoblasts and osteocytes were indicative of active osteophytic bone deposition at the apical ends of the ESPs. Numerous flecks of woven bone trabecula were also observed within the tendinous fibres of the stylohyoid ligament inserting at the tips of the styloid processes (Figures 2H, 2I, 3E, 3F, 4E, 4F, 5I-5L and 6, 7), which was indicative of osseous metaplasia of this connective tissue mesenchyme, resulting most likely from the repetitive stimulus of tensile forces exerted on the apices by movements of the hyoid bone, transmitted *via* the SL. A number of basophilic reversal lines were seen within the bone, indicative of alternating periods of quiescence and active bone formation at the in this region (Figures 5I-5L).

Postoperatively, following transoral styloidectomy in all patients, there was observed a complete and permanent remission and resolution of all the objective and subjective symptoms of the condition. The patients were followed up for ten to nineteen months,

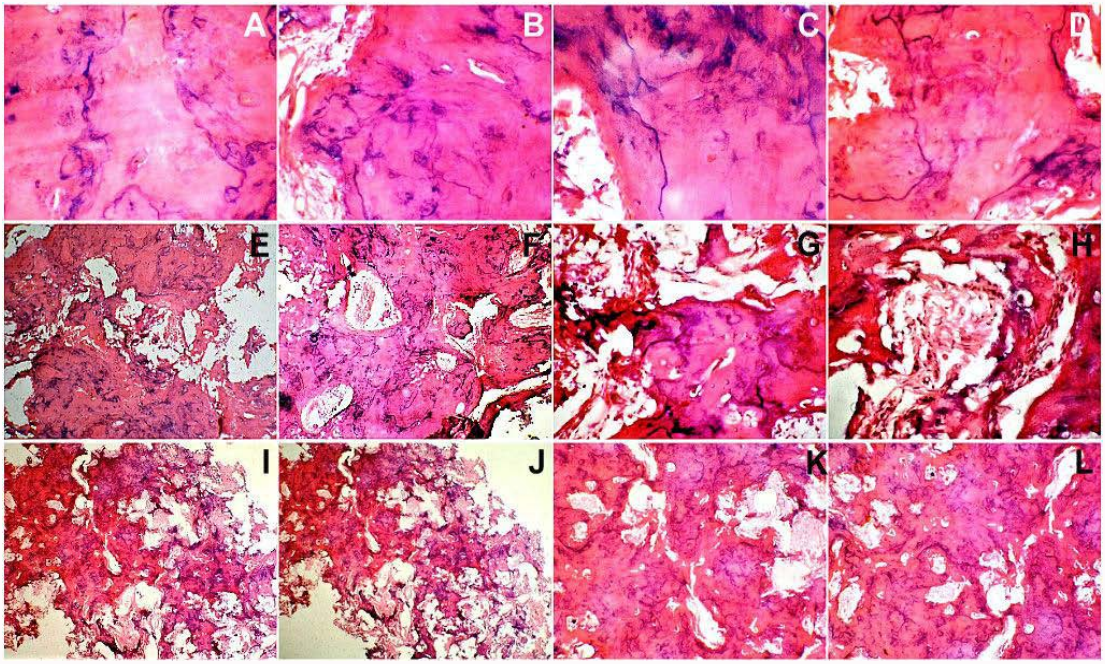


**Figure 5:** (Case 4) Basal, Mid- and Apical thirds of the Excised ESPs. (A-D) (Hematoxylin and Eosin-stained sections at x150 magnification) Basal third of the ESPs in this case, were composed of dense, compact bone with sparse marrow spaces and deeply staining reversal lines indicative of alternating periods of quiescence and active bone deposition. There was observed limited lamellar arrangement of the trabeculae, which instead, appeared more like irregular woven bone. (E-H) Hematoxylin & Eosin x150. Mid-third of the ESP was composed of haphazardly arranged, immature woven bone trabeculae, interspersed with inferiorly inclined fibro-collagenous insertions of tendons of the styloid group of muscles. (I-L) Haematoxylin & Eosin x50, x150. Apical third of the ESP showed a profusion of immature woven bone trabeculae with tendinous fibres of the stylohyoid ligament entering its tip. Emergence of developing bony trabeculae from the adjacent fibrous connective tissue was indicative of osseous metaplasia of pluripotent cells, induced by the tensile stresses generated at the insertion of the stylohyoid ligament.

and there was neither recurrence of any of the clinical features of ES, nor any radiological evidence of lengthening noted in the styloid stumps in any of the patients.

## Discussion

The normal length of the styloid process ranges from 1.52 cm to 4.77 cm [6] with most of them being shorter than 3 cm [7]. In our Study of ten patients diagnosed with Eagle's syndrome, the lengths of the SPs ranged from 4.3 cm to 7.4 cm. Four patients in this series exhibited unilateral objective and subjective symptoms of the syndrome complex, accompanied by unilateral elongation of the SP.

Studies and reports in the past have unsuccessfully attempted to explain the pathogenesis of elongation of Styloid processes [8,9]. However, none of these theories have been backed by adequate and valid substantiating or supporting evidence.

Among the various documented explanations for styloid enlargement, some have attributed a traumatic event occurring in the pharyngeal region, such as tonsillectomy [8], which could stimulate postsurgical fibrous granulation tissue formation, which in turn stimulates overgrowth of the styloid process. Others have focused on changes due to aging [9], endocrine disorders, local chronic irritations or inflammation which could result in ossified hyperplasia of the SPs. According to another theory, ESPs may primarily have a congenital origin. Mechanical stresses stretching the second branchial arch during fetal development might possibly induce a variable stimulation of different parts of the Reichert's cartilage during morphogenesis of the styloid process, resulting in its lengthening.

Systemic factors related to abnormal serum calcium and phosphorus levels, leading to heterotopic calcification in non-osseous soft tissues, have been proposed to be associated with Eagle's syndrome [10]. According to this theory, extra skeletal (ectopic) calcification (deposition calcium phosphate crystals) or ossification (true bone formation) due to high serum calcium levels, may contribute towards elongation of SPs. Abnormal Calcium (Ca), Phosphorus (P) and vitamin D metabolism is very common in patients with chronic renal failure and End-Stage Renal Disease (ESRD), particularly in the geriatric population. Secondary hyperparathyroidism causing metastatic calcification has also been proposed to have a possible role to play in some cases of styloid elongation [9].

Some studies have explored the presence of cartilaginous islets at the apex of the SP and have attributed continued growth of the styloid as being made possible through continued activity of this cartilaginous cap at the tip.

The present report is probably the only one of its kind recorded in literature so far, that provides a detailed and comprehensive histopathological analysis of different parts of the excised specimen of ESPs from ten different patients diagnosed with ES. This study has provided valuable information on the etiomorphogenesis of this condition, and significant insights into the probable stimuli or triggering factors leading to its development.

The detailed and systematic histopathological analysis of sections from different levels (apical, mid- and basal thirds) of the excised ESPs carried out in this study revealed valuable and important facts. A multitude of newly developing woven bone trabecula were seen emanating from two main regions, the mesenchyme of the tendons of the styloid group of muscles inserting at the basal and mid thirds

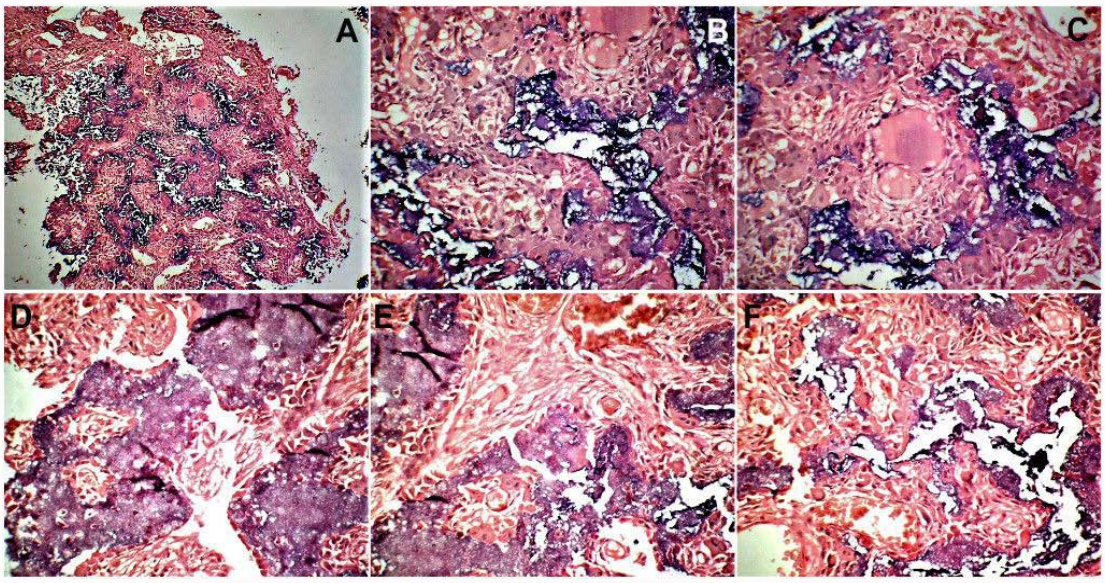


**Figure 6:** (Case 5) Apical third of the Excised ESP. (A-C) Haematoxylin and eosin-stained sections at x40 and x150 magnifications, showed irregular osteophytic bone deposition and dystrophic calcification at the tip of the elongated styloid process. Deeply staining irregular flecks and larger spherules of woven bone were seen interspersed within fibrovascular and dense collagenous connective tissue stroma. (D-F) Hematoxylin & Eosin x100. Immature woven bone with a few vascular spaces and plump osteoblasts, surrounded by fibro-collagenous connective tissue was distinctly indicative of osseous metaplasia taking place within the connective tissue. There was no evidence of a cartilaginous cap at the apex. A number of deeply basophilic reversal lines were also seen within the immature woven bone. Numerous thick tendinous fibres of the stylohyoid ligament were found entering and inserting into the tip of the styloid process, as well as engulfing the developing and differentiating osteoid tissue at the apical region of the ESP.

of the ESPs, and from the mesenchymal tissue insertions of the stylohyoid ligament fibres at the styloid process apex. This histologic picture was indicative of the fact that the secondary bone growth responsible for enlargement (widening as well as elongation) of the SPs, was attributable to bone formation at these tendon and ligament attachments, and was likely to have been stimulated/triggered by their repetitive pull and traction forces resulting from the respective muscle and ligament contractions. The vesicular connective tissue cells within the tendinous tissue inserting into the SPs, are stimulated to undergo metaplastic transformation into osteoblasts/osteocytes, leading thereon to laying down of fibrous bone in the region. We propose a reactive response to triggers or stimuli, such as repetitive tensile and traction forces exerted as a result of muscle contractions, to be responsible for this osseous metaplasia, i.e., to a direct change of the tendinous tissue into bone.

Further, in our light microscopic analysis of the ESPs, marked osteophytic bone deposition and dystrophic calcification was observed at the tips and lateral surfaces of their apical thirds. The mesenchymal insertions of the stylohyoid ligament and the periosteal fibrous connective tissue covering the apices of the styloid processes were found to be traversed by a profusion of developing islets of immature woven bone. This was indicative of metaplasia of the mesenchymal elements of the stylohyoid ligament inserting at the apex, as well as of the pluripotent cells of the periosteum, into osseous tissue. This metaplasia was most likely to have been triggered by a constant or intermittent local irritation, resulting from repeated hyoid movements, transmitted as traction forces or tensile stresses, *via* the SL to the SP.

Numerous histologic sections from the entire length of the ESPs demonstrated the presence of basophilic reversal lines, which was suggestive of possible micro-fractures of these delicate stalactite structures, resulting from recurrent traumatic, muscular traction forces, followed by repeated attempts at repair and ossification.

We propose that mechanical stresses generated at the tips of the styloid processes, caused by tensile stresses transmitted through repeated stretching of the styloid ligament fibres inserting there, could stimulate new, active bone deposition as a reactive/protective response in the periosteal connective tissue, thereby leading to lengthening of the SPs. The factors stimulating this osseous metaplasia and subsequent calcification of the SP, are most likely to be recurrent or chronic tensile forces generated by the pharyngeal, tongue and neck (hyoid) movements and transmitted *via* the stylopharyngeus, styloglossus and stylohyoid muscles, and stylohyoid ligament insertions respectively, to the bony styloid. Metaplasia of pluripotent cells within the tendinous muscle insertions as well as within the periosteal membrane overlying the SPs, may be followed by their transformation into osseous structure by mineralization and ossification followed by the subsequent elongation and thickening of the SPs.

Studies in the past have claimed that the developmental origin of the ESP is the cartilaginous tissue remnant within it and the cartilage cap at its apex, and that axial and apical elongation of the SP result from callus-induced endochondral ossification, rather than intramembranous bone ossification, after an osteogenetic signal such as a tensile stress on the SP [11,12]. However, in our histopathological analysis of the sixteen excised ESPs, we found no cartilaginous cap at their tips and no evidence of endochondral ossification anywhere along their entire length.

Moreover, our study demonstrated osteophytic bone deposition at the apices, as well as lateral & medial surfaces of the ESPs, with no evidence to support an axial elongation attributable to endochondral ossification of intramedullary growth plate calluses.

Additional studies augmented by Immunohistochemical analysis

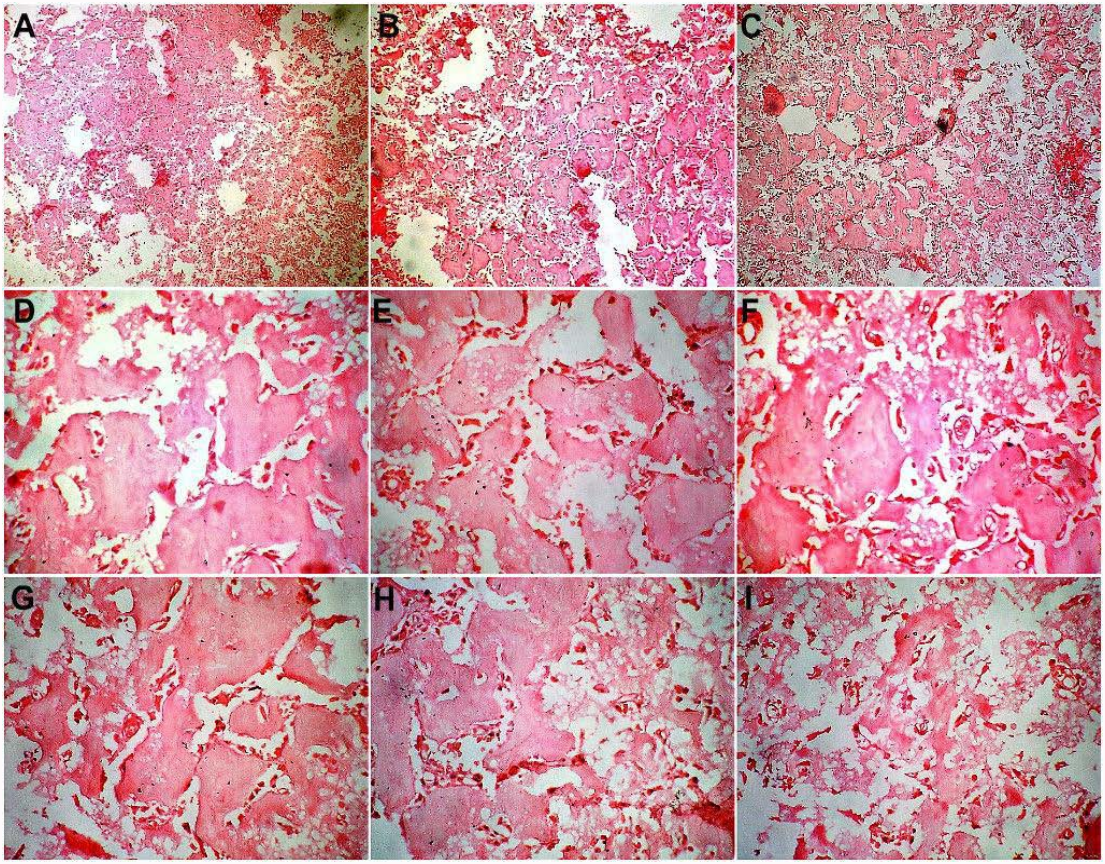


**Figure 7:** (Case 6) Hematoxylin and Eosin-stained sections at x50, x150 magnifications of the Apical third of the Excised ESP. (A-F) Irregular osteoid formation and osteophytic bone deposition was found at the apical region of the ESP, at the site of inserting fibres of the stylohyoid ligament. This was demonstrative of stress induced osseous metaplasia of the connective tissue component adjacent to the tip of the styloid apex. (G-I) The relative proportion of fibro-collagenous connective tissue component in this case, was found to be less, with scanty collagen observed at the most terminal portion of the bony apex, continuing inferiorly as the stylohyoid ligament insertion.

of excised styloid processes from Eagle's syndrome patients, may contribute towards elucidating the precise molecular and biochemical mechanisms of styloid process elongation.

## Conclusion

This report is probably the only one of its kind, recorded as yet in literature, which provides an in-depth histopathological analysis of the different parts of excised specimen of ESPs from ten patients with ES. The data obtained has significantly contributed towards understanding the etiomorphogenesis of ESPs and has also served to elucidate the stimuli and triggering factors leading to their development and progression.

The increased tensile stresses in the Stylohyoid ligament attached to the styloid process at its apex, and in the tendinous insertions of the Stylopharyngeus and Styloglossus muscles at its base and mid thirds, may well play the role of triggering factors, stimulating osseous metaplasia of pluripotent cells and consequent osteogenesis at these locations as a reactive response, leading to increase in length as well as circumference of the SPs with their attendant, associated clinical sequela.

## Compliance with Ethical Standards

### Research involving human participants and/or animals

All procedures performed on the patients (human participants) involved were in accordance with the ethical standards of the institution and/or national research committee, as well as with the 1964 Helsinki declaration and its later amendments and comparable ethical standards.

## References

1. Prasad KC, Kamath MP, Reddy KJ, Raju K, Agarwal S. Elongated styloid process (Eagle's syndrome): A clinical study. J Oral Maxillofac Surg. 2002;60(2):171-5.
2. Badheya A, Jategaonkara A, Kovacsb AJA, Kadakiaa S, De Deync PP, Ducicd Y, et al. Eagle syndrome: A comprehensive review. Clin Neurol Neurosurg. 2017;159:34-8.
3. Kursoglu P, Unalan F, Erdem T. Radiological evaluation of the styloid process in young adults resident in Turkey's Yeditepe University Faculty of Dentistry. Oral Surg Oral Med Oral Pathol Oral Radiol Endod. 2005;100(4):491-4.
4. Yavuz H, Caylakli F, Erkan AN, Ozluoglu LN. Modified intraoral approach for removal of an elongated styloid process. J Otolaryngol Head Neck Surg. 2011;40(1):86-90.
5. Chrcanovic BR, Neto Custódio AL, Felix de Oliveira DR. An intraoral surgical approach to the styloid process in Eagle's syndrome. Oral Maxillofac Surg. 2009;13(3):145-51.
6. Saccomanno S, Greco F, De Corso E, Lucidi D, Deli R, D'addona A, et al. Eagle's Syndrome, from clinical presentation to diagnosis and surgical treatment: A case report. Acta Otorhinolaryngol Ital. 2018;38(2):166-9.
7. Kaufman SM, Elzay RP, Irish EF. Styloid process variation: radiologic and

clinical study. Arch Otolaryngol. 1970;91(5):460-3.

8. Fini G, Gasparini G, Filippini F, Becelli R, Marcotullio D. The long styloid process syndrome or Eagle's syndrome. J Craniomaxillofac Surg. 2000;28(2):123-7.

9. Camarda AJ, Deschamps C, Forest DI. Stylohyoid chain ossification: A discussion of etiology. Oral Surg. Oral Med Oral Pathol. 1989;67(5):508-14.

10. Gokce C, Sisman Y, Sipahioglu M. Styloid process elongation or Eagle syndrome: Is there any role for ectopic calcification? Eur J Dent. 2008;2:224-8.

11. Maki D, Okami K, Ebisumoto K, Sakai A. Chronological progression of an enlarged styloid process: A case report of eagle syndrome. Case Rep Otolaryngol. 2018;1-4.

12. Ilguy M, Ilguy D, Guler N. Incidence of the type and calcification patterns in patients with elongated styloid process. J Int Med Res. 2005;33(1):96-102.